

A Case of Olfactory Neuroblastoma Developing Bilateral Retropharyngeal Lymph Node Metastasis 14-years After Skull Base Surgery

MARIE MIZUMOTO¹, TATSUYA FURUKAWA^{1,*}, MITSUKO YUI¹,
KEISUKE IRITANI¹, SHUN TATEHARA¹, GO INOKUCHI¹,
MASANORI TESHIMA¹, HIROTAKA SHINOMIYA¹, HIDEHITO KIMURA²,
NAOMI KIYOTA³, RYOHEI SASAKI⁴, and KEN-ICHI NIBU¹

¹*Department of Otolaryngology-Head and Neck Surgery, Kobe University Hospital, Kobe, Japan;*

²*Department of Neurosurgery, Kobe University Hospital, Kobe, Japan;*

³*Cancer Center, Kobe University Hospital, Kobe, Japan;*

⁴*Division of Radiation Oncology, Kobe University Hospital, Kobe, Japan*

**Corresponding author*

Received January 23, 2024/Accepted March 13, 2024

Keywords: Olfactory neuroblastoma, Otitis media with effusion, Retropharyngeal lymph node, Hyams grade, Postoperative radiotherapy

Olfactory neuroblastoma (ONB) is an uncommon malignant tumor and is usually treated by a multidisciplinary approach includes surgery, radiotherapy, and chemotherapy. A 62 years-old male had a tumor in the nasal cavity and diagnosed as ONB with Kadish A stage. Anterior skull base surgery was performed as radical treatment. Since the surgical margin was negative, no postoperative radiotherapy was administered. 14 years after the surgery, bilateral otitis media with effusion (OME) was occurred, we found the recurrence tumor at bilateral retropharyngeal lymph node (RPLN) which surrounded the internal carotid arteries. Since these were unresectable, we planned chemoradiotherapy which was 70Gy of intensity modulated radiotherapy combined with two courses of carboplatin and etoposide. The tumor volume was reduced and bilateral OME were improved. He has been alive for 3 years after salvage treatment. Although ONB has a relatively good prognosis, it is known to often cause cervical lymph node metastasis. Grades III and IV of Hyams classification are considered high risk. This case, initial tumor was limited in the nasal cavity and its clinical classification was early stage, but Hyams classification was grade III. In reference to this case, considering that RPLN metastasis are difficult to radically resect at the salvage surgery, including this area in postoperative radiotherapy was considered an option.

INTRODUCTION

Olfactory neuroblastoma (ONB) is a rare malignant neoplasm accounting for 3% of sinonasal malignant tumors (1) and is thought to be derived from the olfactory neuroepithelium (2). Since the initial symptoms are non-specific nasal complications, such as nasal congestion and epistaxis, ONB is often diagnosed at advanced stages and easily invades adjacent structures, such as anterior cranial base at the time of initial diagnosis (3). Thus, open and/or endoscopic craniofacial resection followed by postoperative radiotherapy with or without systemic chemotherapy is the current standard of care (4–7) and leads to favorable oncological and functional outcomes in the short term. However, locoregional and/or distant recurrences occasionally occur long after the initial treatment (8–11) and long-term follow-up is recommended for the patients with ONB. In this article, we report a case of ONB developing bilateral retropharyngeal lymph nodes (RPLN) associated with refractory otitis media with effusion (OME) 14 years after skull base surgery without postoperative radiotherapy.

CLINICAL CASE

A 62 years-old male visited our affiliated hospital with a complaint of right nasal obstruction. Endoscopic examination revealed an easily bleeding reddish mass in the right olfactory fissure. The biopsy specimen from this lesion was diagnosed as olfactory neuroblastoma. The patient was referred to our department for further investigation and treatment. Enhanced computed tomography (CT) showed a lesion with contrast effect in the right olfactory fissure. Bone of the anterior skull base above this lesion was thinning, but the continuity of the

Phone: +81-78-382-6024 Fax: +81-78-382-6039 E-mail: ftatsuya@med.kobe-u.ac.jp

Any user may reuse and redistribute the article without requesting permission from the copyright holder only for non-commercial purposes, as long as the original source is properly credited.

A CASE OF ONB WITH RPLN METASTASIS AFTER 14 YEARS

bone cortex was maintained (Fig. 1). Thus, we considered this tumor was confined in the nasal cavity. From these results, clinical stage was diagnosed as modified Kadish A (12) and T1N0 according to Dulguerov classification (13, 14). However, pathological diagnosis was grade III according to Hyams histological grading system (14) (Fig. 2).

The patient underwent radical resection of the tumor by anterior skull base surgery using bilateral frontal craniotomy (Fig. 3). Skull base was reconstructed pericranial flap. Since surgical margins were pathologically negative, postoperative radiotherapy was not employed. The patient had been followed up without recurrence for 6 years. After that, he stopped visiting the hospital on his own accord.

At the age of 76-years old, he underwent MRI to investigate prolonged OME at another hospital. Then, he was referred to our hospital for further examination of the abnormal findings in MRI. On MRI, large space occupying lesions were observed in bilateral retropharyngeal area and both lesions surrounded the entire circumference of the internal carotid arteries (Fig. 4a). Biopsy was performed via transoral approach and these lesions were diagnosed as lymph node metastasis of ONB. On FDG-positron emission tomography (FDG-PET), marked accumulations of FDG were observed in these lesions (Fig. 4b), but no accumulation was observed in the primary site or other areas.

Since the lesions were unresectable, concomitant chemoradiation therapy was applied. Intensity modulated radiation therapy (IMRT) of 69.96Gy/33Fr was administered to these recurrent lymph nodes, mainly to the bilateral RPLN (Fig. 5). For chemotherapy, two courses of carboplatin (5 AUC) and 80 mg/m² of etoposide were administered. The tumor volumes were dramatically reduced and OME gradually improved. He has been alive with reduced bilateral RPLN metastasis for 3 years after concomitant CRT. No evidence of recurrence was observed in primary site or other areas (Fig. 6).

Written Informed consent was obtained from the patient and this study was approved by the Ethical Committee of Kobe University Hospital (No. B200029).

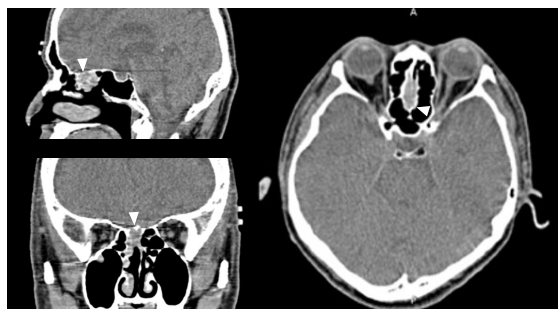


Fig. 1.

Preoperative computed tomography at the initial treatment (arrowheads indicate tumor)

Lesion was confined to the nasal cavity. Bone of the anterior skull base above this lesion was thinning, but the continuity of the bone cortex was maintained.

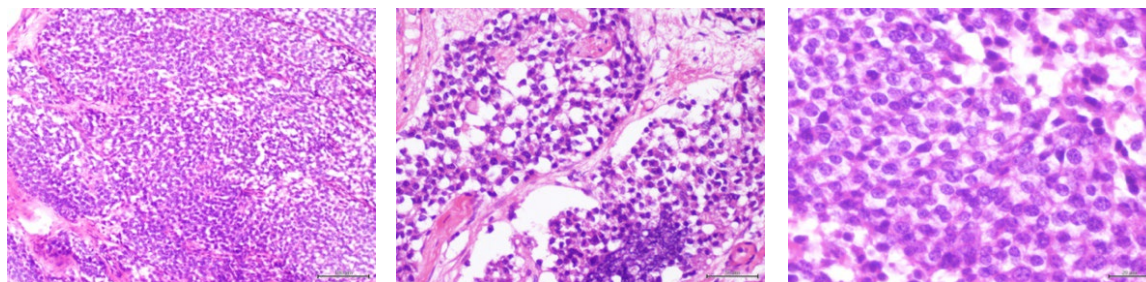


Fig. 2. Pathological images (Hematoxylin Eosin staining)

Homogeneous cells with pale sporangia and similarly round nuclei. Nuclear/cytoplasm ratio is high. Scattered rosette-like structures.

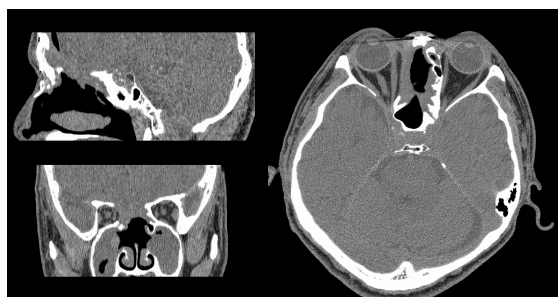

Fig. 3.

Postoperative computed tomography

The tumor was removed along with part of the skull base. Fluid accumulation was observed as a secondary change in the extraction site and bilateral maxillary sinuses.

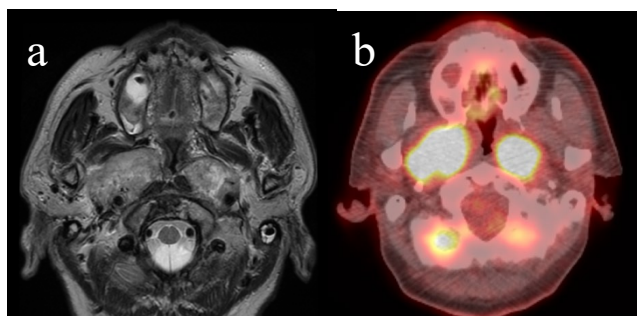


Fig. 4.
T2 weighted MRI (a) and FDG-PET/CT (b) at the diagnosis of regional recurrence
Bilateral internal carotid arteries were encased by RPLN metastasis.

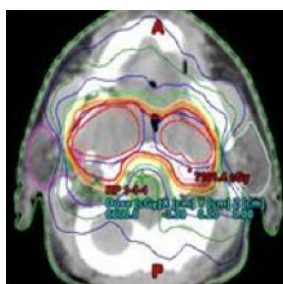


Fig. 5.
Imaging of IMRT planning

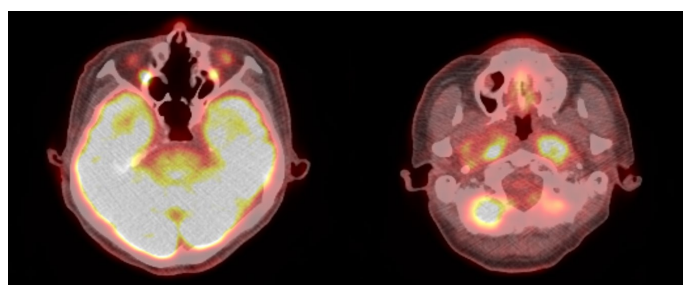


Fig. 6.
Follow-Up FDG-PET/CT 3 years after CRT
No evidence of recurrence was observed in primary site or other areas.

DISCUSSION

ONB is relatively slow growing and its oncological outcome is favorable in the short term. However, locoregional and/or distant recurrences occasionally occur long after the initial treatment (8–11). Recurrence in the regional lymph node has been reported to occur in about 20% of ONB. Level II, III, and RPLN as shown in the present case are common sites for regional metastasis (11, 15–19). According to the Hyams grading system, patients with grades III and IV are considered at high risk of distant and regional metastasis after initial treatment (20). Thus, several studies recommend that not only the primary site but also regional lymph nodes should be included in the irradiation field of postoperative radiotherapy (11, 21, 22). Jiang et al. reported the recurrence rate of cervical lymph nodes was dramatically reduced by including the neck in the irradiation field of postoperative radiotherapy, even in the patients without lymph node metastasis at the time of initial treatment (11).

Recurrence at cervical lymph nodes, such as Level I–V can be surgically treated if detected early. However, metastasis to RPLN is difficult to surgically treat due to its location and proximity to internal carotid artery and lower cranial nerves. In addition, surgical resection of RPLN is often associated with significant postoperative complications, such as aspiration and dysphagia (23).

Additionally, when combined with chemotherapy for ONB, regimens are based on platinum agents and are commonly used in combination with etoposide (24, 25).

As mentioned above, depending on the degree of malignancy of ONB, it is necessary to consider multidisciplinary treatment including surgery. There are some reports of recurrence more than 5 years after treatment, and long-term follow-up for 10 years or more is required (26, 27).

CONCLUSION

Patients with high histological grade ONB are at high risk of regional recurrence including RPLN. Recurrence at RPLN should be considered as a differential diagnosis if the patients with ONB suffer from OME

even years after initial treatment. As mentioned above, surgery is difficult when metastasis are present in the RPLN. If there are similar cases in the future, it is worth considering the use of postoperative radiotherapy and the inclusion of RPLN in the irradiation range for the early-stage cancer with the high histological grade.

REFERENCES

1. Bell D, Hanna EY, Weber RS, D Bell D, Hanna EY, Weber RS, et al. Neuroendocrine neoplasms of the sinonasal region. *Head Neck*. 2016;38 Suppl 1:E2259–2266.
2. Saade RE, Hanna EY, Bell D. Prognosis and biology in esthesioneuroblastoma: the emerging role of Hyams grading system. *Curr Oncol Rep*. 2015;17(1):423.
3. Dulguerov P, Allal AS, Calcaterra TC. Esthesioneuroblastoma: a meta-analysis and review. *Lancet Oncol*. 2001;2(11):683–690.
4. Bachar G, Goldstein DP, Shah M, Tandon A, Ringash J, Pond G, et al. Esthesioneuroblastoma: The Princess Margaret Hospital experience. *Head Neck*. 2008;30(12):1607–1614.
5. Mays AC, Bell D, Ferrarotto R, Phan J, Roberts D, Fuller CD, et al. Early Stage olfactory neuroblastoma and the impact of resecting dura and olfactory bulb. *Laryngoscope*. 2018;128(6):1274–1280.
6. Mehta GU, Hanna EY, DeMonte F, Raza SM. Endoscopic endonasal resection of sinonasal/anterior skull base malignancy (Kadish C esthesioneuroblastoma). *Acta Neurochir (Wien)*. 2018;160(2):361–366.
7. Teshima M, Shinomiya H, Otsuki N, Kimura H, Taniguchi M, Hashikawa K, et al. Complications in Salvage Surgery for Nasal and Paranasal Malignant Tumors Involving the Skull Base. *J Neurol Surg B Skull Base*. 2018;79(3):224–228.
8. Tyler MA, Mohamed ASR, Smith JB, Aymard JM, Fuller CD, Phan J, et al. Long-term quality of life after definitive treatment of sinonasal and nasopharyngeal malignancies. *Laryngoscope*. 2020;130(1):86–93.
9. Bell D, Saade R, Roberts D, Ow TJ, Kupferman M, DeMonte F, et al. Prognostic utility of Hyams histological grading and Kadish-Morita staging systems for esthesioneuroblastoma outcomes. *Head Neck Pathol*. 2015;9(1):51–59.
10. Su SY, Bell D, Ferrarotto R, Phan J, Roberts D, Kupferman ME, et al. Outcomes for olfactory neuroblastoma treated with induction chemotherapy. *Head Neck*. 2017;39(8):1671–1679.
11. Jiang W, Mohamed ASR, Fuller CD, Kim BYS, Tang C, Gunn GB, et al. The role of elective nodal irradiation for esthesioneuroblastoma patients with clinically negative neck. *Pract Radiat Oncol*. 2016;6(4):241–247.
12. Morita A, Ebersold MJ, Olsen KD, Foote RL, Lewis JE, Quast LM. Esthesioneuroblastoma: prognosis and management. *Neurosurgery*. 1993;32(5):706–714; discussion 714–705.
13. Dulguerov P, Calcaterra T. Esthesioneuroblastoma: the UCLA experience 1970-1990. *Laryngoscope*. 1992;102(8):843–849.
14. Hyams V, Batsakis J, Michaels L. Tumors of the Upper Respiratory Tract and Ear. In: *Atlas of Tumor Pathology*. Washington D.C: Armed Forces Institute of Pathology; 1988. p. 240–248.
15. Howell MC, Branstetter BF 4th, Snyderman CH. Patterns of regional spread for esthesioneuroblastoma. *AJNR Am J Neuroradiol*. 2011;32(5):929–933.
16. Kim HJ, Kim J, Yoon JH. Retropharyngeal lymph node metastasis from olfactory neuroblastoma: A report of two cases. *Eur Arch Otorhinolaryngol*. 2006;263(8):778–782.
17. Zollinger LV, Wiggins RH 3rd, Cornelius RS, Phillips CD. Retropharyngeal lymph node metastasis from esthesioneuroblastoma: a review of the therapeutic and prognostic implications. *AJNR Am J Neuroradiol*. 2008;29(8):1561–1563.
18. Sai A, Shimono T, Yamamoto A, Takeshita T, Ohsawa M, Wakasa K, et al. Incidence of abnormal retropharyngeal lymph nodes in sinonasal malignancies among adults. *Neuroradiology*. 2014;56(12):1097–1102.
19. Banuchi VE, Dooley L, Lee NY, Pfister DG, McBride S, Riaz N, et al. Patterns of regional and distant metastasis in esthesioneuroblastoma. *Laryngoscope*. 2016;126(7):1556–1561.
20. Goshtasbi K, Abiri A, Abouzari M, Sahyouni R, Wang BY, Tajudeen BA, et al. Hyams grading as a predictor of metastasis and overall survival in esthesioneuroblastoma: a meta-analysis. *Int Forum Allergy Rhinol*. 2019;9(9):1054–1062.
21. Hollen TR, Morris CG, Kirwan JM, Amdur RJ, Werning JW, Vaysberg M, et al. Esthesioneuroblastoma of the nasal cavity. *Am J Clin Oncol*. 2015;38(3):311–314.
22. Ow TJ, Hanna EY, Roberts DB, Levine NB, El-Naggar AK, Rosenthal DI, et al. Optimization of long-term outcomes for patients with esthesioneuroblastoma. *Head Neck*. 2014;36(4):524–530.
23. Otsuki N, Morita N, Furukawa T, Teshima M, Shinomiya H, Nibu KI. Functional and oncological outcomes after retropharyngeal node dissection for papillary thyroid carcinoma. *Eur Arch Otorhinolaryngol*.

- 2019;276(6):1809–1814.
24. Porter AB, Bernold DM, Giannini C, Foote RL, Link MJ, Olsen KD, et al. Retrospective review of adjuvant chemotherapy for esthesioneuroblastoma. *J Neurooncol.* 2008;90(2):201–204.
 25. Fitzek MM, Thornton AF, Varvares J, Ancukiewicz M, Mcintyre J, Adams J, et al. Neuroendocrine tumors of the sinonasal tract. Results of a prospective study incorporating chemotherapy, surgery, and combined proton-photon radiotherapy. *Cancer.* 2002;94:2623–34
 26. Devaiah AK, Andreoli MT. Treatment of esthesioneuroblastoma: a 16-year meta-analysis of 361 patients. *Laryngoscope.* 2009;119(7):1412–16.
 27. Zhang L, Niu K, Zhu K, Yan J, Zhao W, Wei J, et al. Long-Term Prognostic Analysis after Endoscopic Endonasal Surgery for Olfactory Neuroblastoma: A Retrospective Study of 13 Cases. *PLoS One.* 2016;11(11):e0166046.