

A Case of Uterine Leiomyosarcoma with Long-Term Disease Control by Pazopanib

SATOSHI NAGAMATA^{1,*}, YASUHIKO EBINA¹, YUMIKA YAMANO¹,
TAKEO MIYAMOTO², MITSUHIRO NISHIJIMA², and HIDETO YAMADA¹

¹Department of Obstetrics and Gynecology, Kobe University Graduate School of Medicine, 7-5-1 Kusunoki-cho, Chuo-ku, Kobe, Hyogo 650-0017, Japan

²Department of Obstetrics and Gynecology, Hyogo Prefectural Awaji Medical Center, 1-1-137 Shioya, Sumoto, Hyogo 656-0021, Japan

Received 5 January 2016/ Accepted 18 March 2016

Key words: Uterine leiomyosarcoma, Soft tissue sarcoma, Lung metastases, Pazopanib, Multityrosine kinase inhibitor

Uterine leiomyosarcoma (ULMS) is an aggressive tumor associated with high rates of progression, recurrence, and mortality. Pazopanib is the only approved molecular targeted drug for advanced soft tissue sarcoma, and it has been proven to prolong progression-free survival relative to placebo. We herein report a case of ULMS with multiple lung metastases treated with pazopanib, which led to sustained disease control for 44 weeks. A 53-year-old woman was referred to our hospital due to massive uterine bleeding from a uterine corpus tumor mass. Total abdominal hysterectomy with bilateral salpingo-oophorectomy was performed as emergency surgery. The final histopathological diagnosis was uterine leiomyosarcoma, and computed tomography revealed multiple lung metastases. After chemotherapy with 17 cycles of gemcitabine and docetaxel and two cycles of doxorubicin, the lung metastases had increased in size and new lesions had appeared. Pazopanib administration at 800 mg/day was started as third-line therapy. Ten weeks later, the dose of pazopanib was reduced to 600 mg/day because of hepatic impairment and hypertension. However, lung metastases of ULMS were stabilized by pazopanib administration for about 44 weeks without a decline in the patient's quality of life. After 44 weeks of therapy, pazopanib administration was discontinued because of progressive disease and worsening of the patient's respiratory status. Pazopanib is an oral multityrosine kinase inhibitor of vascular endothelial growth factor receptor-1, -2, and -3; platelet-derived growth factor- α and - β ; and c-Kit receptor. The role of pazopanib may be clinically significant in the treatment of advanced ULMS.

INTRODUCTION

Uterine leiomyosarcoma (ULMS) is a rare tumor that accounts for only 1% to 2% of uterine malignancies². Compared with other types of uterine cancers, ULMS is an aggressive tumor associated with high rates of progression, recurrence, and mortality. The peak age at onset of ULMS is approximately 50 years, and the median survival time is 31 months in Japan³. There are limited treatment options in patients with metastasis.

Pazopanib is an oral multityrosine kinase inhibitor of vascular endothelial growth factor receptor (VEGFR)-1, -2, and -3; platelet-derived growth factor (PDGFR)- α and - β ; and c-Kit receptor^{4,9}. The drug has been approved for the treatment of advanced soft tissue sarcomas in Japan since 2012.

We herein report a case of ULMS with multiple lung metastases treated with pazopanib, which led to sustained long-term disease control. Written informed consent was obtained from the patient for publication of this case report and accompanying images.

CLINICAL CASE

A 53-year-old, gravida 2, para 2 presented with massive vaginal bleeding from a uterine corpus tumor. She had a history of a uterine tumor and bronchial asthma. Total abdominal hysterectomy with bilateral salpingo-oophorectomy was performed as emergency surgery. Examination of the pelvic cavity revealed a 12cm uterine mass with some myomas. Surface of the uterus was smooth and visible invasions of uterine serosa or adnexa were not observed. However, uterine corpus tumor contained extensive necrotic tissue and the final histopathological diagnosis was ULMS. Computed tomography (CT) revealed multiple lung metastases after surgery, and the tumor was staged and graded as T1b Nx M1, Stage IVB (International Federation of Gynecologists and Obstetricians; FIGO2008).

Gemcitabine–docetaxel chemotherapy (hospital’s original fixed dose rate to avoid severe myelosuppression: gemcitabine at 650 mg/m² on days 1 and 8, docetaxel at 55 mg/m² on day 8) was initiated. CT revealed a partial response according to the Response Evaluation Criteria in Solid Tumors (RECIST). However, after 17 cycles of first-line chemotherapy with gemcitabine–docetaxel, the lung metastases had increased in size and a new lesion had appeared in the lung. Second-line treatment with doxorubicin (60 mg/m²) was discontinued after two cycles because progression of the lung metastases was detected. Pazopanib was administered as third-line therapy.

After 8 weeks of pazopanib at 800 mg/day, CT revealed necrotic change in some of the metastatic tumors and an increase in the size of the other tumors (Figure 1a, b). The response evaluation revealed stable disease according to the RECIST criteria. However, blood tests showed a gradual increase in the concentrations of liver enzymes (the alanine transaminase and aspartate transaminase) on liver function tests. Furthermore, the blood pressure showed a tendency to rise. After 10 weeks of this treatment, the liver enzyme concentrations and blood pressure significantly increased (grade 3 toxicity: adverse events were graded according to Common Terminology Criteria for Adverse Events (CTCAE) version 4.0), and we reduced the dose of pazopanib to 600 mg/day. After this dose reduction, both of these adverse effects returned to a normal level without any medication.

The treatment was well tolerated by the patient, and no other significant adverse effects occurred. Grade 2 diarrhea and grade 1 fatigue developed, but the diarrhea improved by probiotics. The patient was able to continue treatment without a decline in quality of life (QOL), and periodic CT scans revealed further necrotic change in the largest metastasis in the left lung (Figure 1c). However, some of the lung metastases were gradually increasing in size, and the overall evaluation was stable disease according to the RECIST criteria.

After 44 weeks of this therapy, CT scan demonstrated progressive lung metastases and an increase in size of solid component in the maximum lesion of lung metastases in the left lung (Figure 1d). Furthermore, the patient’s bronchial asthma and cough had worsened. Pazopanib administration was discontinued, and the patient entered a palliative care unit. Three weeks later, the patient died of respiratory failure.

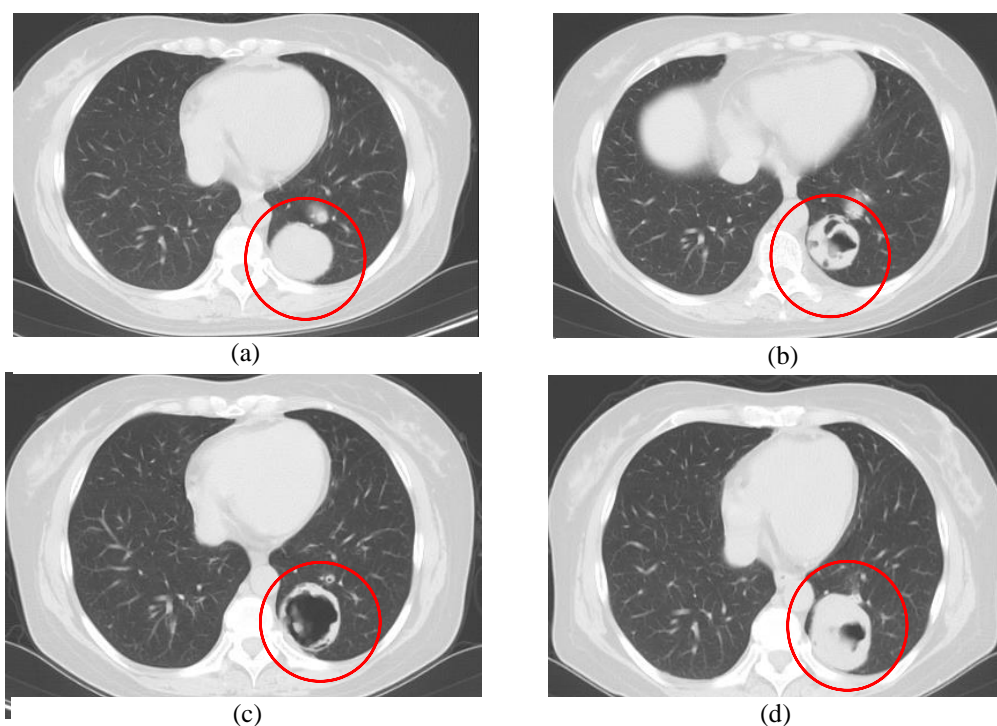


Figure 1.

(a) CT scan at start of pazopanib showing maximum lesion of multiple lung metastases in the left lung (circle). (b) (c) CT scans after 8 weeks and 26 weeks of pazopanib treatment showing gradually increase in size of necrotic component in the maximum lesion (circle). (d) CT scan after 44 weeks of pazopanib treatment showing an increase in size of solid component in the maximum lesion (circle).

DISCUSSION

ULMS is a rare and extremely aggressive disease. The diagnosis is often proven by histopathology after surgery, because accurate preoperative diagnosis of ULMS is difficult⁸. Total abdominal hysterectomy is recommended as the initial treatment; removal of the ovaries and lymph node dissection remain controversial². Chemotherapy should be considered in patients with advanced or unresectable ULMS. Gemcitabine–docetaxel chemotherapy is the most common treatment method for ULMS with response rates ranging from 27% to 36%^{5,6}, and doxorubicin-based therapy is also a mainstay of chemotherapy for unresectable metastatic ULMS. In addition to those, pazopanib, a multityrosine kinase inhibitor, has been approved as a new treatment option in patients with ULMS since 2012 in Japan.

Pazopanib was tested in patients with metastatic non-adipocytic soft tissue sarcoma after failure of standard chemotherapy (phase III PALETTE study) and was shown to prolong median progression-free survival by 3 months relative to placebo (4.6 vs. 1.6 months, respectively)¹⁰. However, no statistically significant difference in median overall survival was observed (12.5 vs. 10.7 months, respectively). A partial response was observed in 6% of patients on pazopanib vs. 0% on placebo, and stable disease occurred in 67% on pazopanib vs. 38% on placebo. In this study, 43% of patients had leiomyosarcoma.

In the present case, lung metastases of ULMS were stabilized by pazopanib for about 44 weeks. Comparison between this case and the PALETTE study cannot be easily made, but overall survival was nearly equal between the two. According to a report of long-term responders and survivors who were treated with pazopanib for advanced soft tissue sarcomas, good performance status, low or intermediate grade of primary tumor and normal hemoglobin level at baseline were advantageous for long-term outcome⁷. In this case, in spite of pretreatment with frequent chemotherapy, the patient had kept good performance status and normal hemoglobin level. Although hepatic impairment and hypertension were observed, dose reduction alone improved these adverse events and patient could continue treatment without a decline in QOL.

In addition to hepatic impairment and hypertension, cardiac disorders, hypothyroidism, bleeding, and pneumothorax have been reported as other important adverse events associated with pazopanib. Special attention should be paid to cardiac adverse events because of anthracycline pretreatment¹⁰. In patients with lung metastases, as in the present case, the risk of pneumothorax should be discussed before initiation of pazopanib because it is very difficult to treat¹¹.

The reported grade 3 toxicities in the pazopanib arm of the PALETTE study were fatigue (13%), hypertension (7%), anorexia (6%), diarrhea (5%), nausea (3%), vomiting (3%), mucositis (1%), and rash or desquamation (<1%)¹⁰. Grade 4 toxicity was only fatigue (<1%) in the pazopanib arm. Although diarrhea, appetite loss, nausea/vomiting, and fatigue were significantly worse in the pazopanib arm, there were no statistically significant differences in health-related QOL between the pazopanib arm and placebo arm as assessed by European Organization for the Research and Treatment of Cancer Quality-of-Life Questionnaire (EORTC QLQ-C30)¹.

There are few reports of ULMS treated with pazopanib. In the report of long-term responders to pazopanib, no conclusive statements could be drawn because of the diversity of the histologic types⁷. In the present case, pazopanib offered long-term disease control and high QOL in a patient with advanced ULMS. The role of pazopanib will be more clinically significant in the treatment of advanced leiomyosarcoma if the associated toxicities are acceptable to the patient.

ACKNOWLEDGEMENTS

This work was supported in part by a Grant-in-Aid from the Japan Society for the Promotion of Science (Grant No. 25462593).

REFERENCES

1. **Coens, C., van der Graaf, W.T., Blay, J.Y., Chawla, S.P., Judson, I., Sanfilippo, R., Manson, S.C., Hodge, R.A., Marreud, S., Prins, J.B., Lugowska, I., Litière, S., and Bottomley, A.** 2015. Health-related quality-of-life result from PALETTE: a randomized, double-blind, phase 3 trial of pazopanib versus placebo in patients with soft tissue sarcoma whose disease has progressed during or after prior chemotherapy—a European Organization for research and treatment of cancer soft tissue and bone sarcoma group global network study (EORTC 62072). *Cancer* **121**:2933-2941.
2. **D'Angelo, E. and Prat, J.** 2010. Uterine sarcomas: a review. *Gynecol Oncol* **116**:131-139.
3. **Fujita, H., Adachi, S., Kigawa, J., Sugiyama, T., and Takeuchi, S.** 2004. A clinicopathological study of uterine sarcoma in last decade – a retrospective study of KCOG/USSG inter group study. *Adv Obstet Gynecol* **56**:463-465.
4. GlaxoSmithKline Votrient Prescribing Information. https://www.accessdata.fda.gov/drugsatfda_docs/label/2009/022465lbl.pdf.2009

5. **Hensley, M.L., Blessing, J.A., DeGeest, K., Abulafia, O., Rose, P.G., and Homesley, H.D.** 2008. Fixed-dose rate gemcitabine plus docetaxel as second-line therapy for metastatic uterine leiomyosarcoma: a Gynecologic Oncology Group phase II study. *Gynecol Oncol* **109**:323-328.
6. **Hensley, M.L., Blessing, J.A., Mannel, R., and Rose, P.G.** 2008. Fixed-dose rate gemcitabine plus docetaxel as first-line therapy for metastatic uterine leiomyosarcoma: a Gynecologic Oncology Group phase II trial. *Gynecol Oncol* **109**:329-334.
7. **Kasper, B., Sleijfer, S., Litiere, S., Marreaud, S., Verweij, J., Hodge, R.A., Bauer, S., Kerst, J.M., and van der Graaf, W.T.** 2014. Long-term responders and survivors on pazopanib for advanced soft tissue sarcomas: subanalysis of two European Organization for Research and treatment of Cancer (EORTC) clinical trials 62043 and 62072. *Ann Oncol* **25**:719-724.
8. **Sagae, S., Yamashita, K., Ishioka, S., Nishioka, Y., Terasawa, K., Mori, M., Yamashiro, K., Kanemoto, T., and Kudo, R.** 2004. Preoperative diagnosis and treatment results in 106 patients with uterine sarcoma in Hokkaido, Japan. *Oncology* **67**:33-39.
9. **Schutz, F.A., Choueiri, T.K., and Sternberg, C.N.** 2011. Pazopanib: clinical development of a potent anti-angiogenic drug. *Crit Rev Oncol Hematol* **77**:163-171.
10. **van der Graaf, W.T., Blay, J.Y., Chawla, S.P., Kim, D.W., Bui-Nguyen, B., Casali, P.G., Schöffski, P., Aglietta, M., Staddon, A.P., Beppu, Y., Le Cesne, A., Gelderblom, H., Judson, I.R., Araki, N., Ouali, M., Marreaud, S., Hodge, R., Dewji, M.R., Coens, C., Demetri, G.D., Fletcher, C.D., Dei Tos, A.P., and Hohenberger, P.; EORTC Soft Tissue and Bone Sarcoma Group; PALETTE study group.** 2012. Pazopanib for metastatic soft-tissue sarcoma (PALETTE): a randomized, double-blind, placebo-controlled phase 3 trial. *Lancet* **379**:1879-1886.
11. **Verschoor, A.J. and Gelderblom, H.** 2014. Pneumothorax as adverse event in patients with lung metastases of soft tissue sarcoma treated with pazopanib: a single reference centre case series. *Clin Sarcoma Res* **4**:14.