

## Coexistence of Endometrioid Adenocarcinoma in Atypical Polypoid Adenomyoma

AYAKO SONOYAMA<sup>1\*</sup>, MASATOSHI KANDA<sup>1</sup>, YOJIRO OJIMA<sup>1</sup>,  
TOMOHIKO KIZAKI<sup>2</sup> and NORIYUKI OHARA<sup>1</sup>.

<sup>1</sup>Department of Obstetrics and Gynecology, Sanda Municipal Hospital, Sanda, Japan;

<sup>2</sup>Department of Pathology, Sanda Municipal Hospital, Sanda, Japan

Received 20 June 2014/ Accepted 17 September 2014

**Key words:** atypical polypoid adenomyoma; endometrial adenocarcinoma

**Atypical polypoid adenomyoma (APA) is a rare polypoid tumor of the uterus composed of atypical endometrial glands and smooth muscle cells. Concomitant development of endometrial adenocarcinoma in APA remains infrequent. We report a case of the coexistence of endometrioid adenocarcinoma in APA. A 41-year-old patient presented with abnormal genital bleeding. A polypoid mass was extruded from the external cervical os. She underwent transcervical resection of the polypoid mass arising from the lower uterine segment. Pathological examination revealed APA with the foci of well-differentiated endometrioid adenocarcinoma. Subsequently, she underwent total hysterectomy and bilateral salpingo-oophorectomy. No residual malignant lesions were found. Awareness of the close association of APA with the development of endometrial cancer is warranted. A meticulous pathological evaluation of specimen of APA is necessary for the detection of the coexistence of endometrial cancer.**

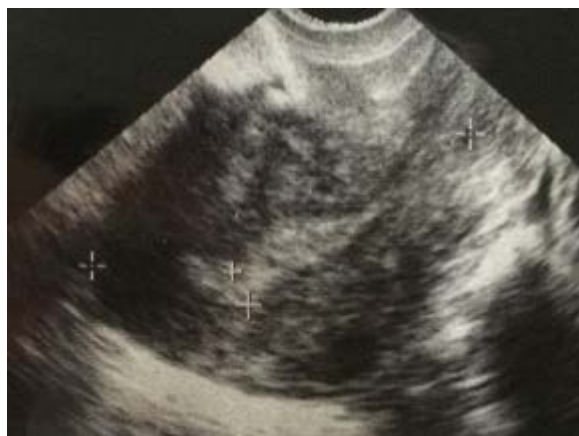### INTRODUCTION

Atypical polypoid adenomyoma (APA) was first designated by Mazur as an uncommon polypoid lesion of the uterus, which was characterized by the proliferation of irregular atypical endometrial glands with squamous metaplasia embedded with a cellular, smooth muscle mesenchyme (6). Although APA is classified as a benign lesion, APA has been reported to undergo progression to endometrial endometrioid adenocarcinoma (2,11) and to coexist with endometrioid adenocarcinoma (1,7,9).

We report a case of the coexistence of endometrioid adenocarcinoma in APA.

### CLINICAL CASE

A 41 year-old mentally-retarded, nulliparous woman presented with abnormal vaginal bleeding. Pelvic examination showed a 2x2 cm-sized polypoid mass protruding from the external cervical os. The surface of the mass was smooth with no findings of necrosis or hemorrhage, and the mass was relatively hard. The presumptive diagnosis was a pedunculated leiomyoma and a different diagnosis was an endocervical polyp. Transvaginal ultrasonography showed an irregularly-shaped uterine cavity with no apparent mass lesions. The thickness of endometrium was 4mm (Figure 1).

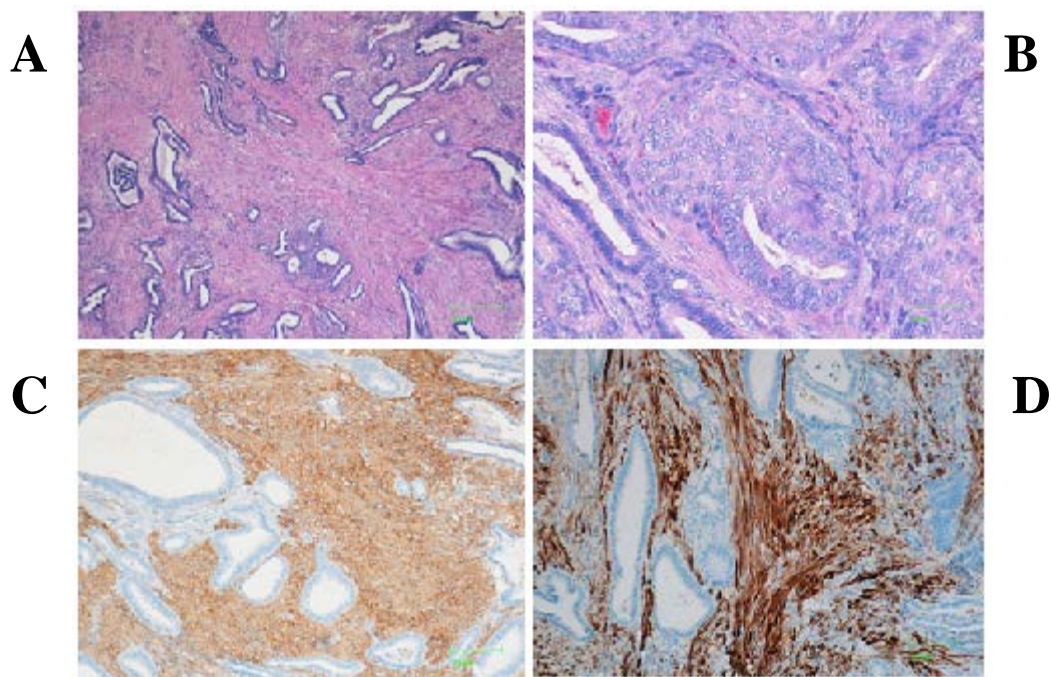


**Figure 1.** Transvaginal ultrasonography, showed the irregularity of uterine cavity with the thickness of endometrium being 4mm.

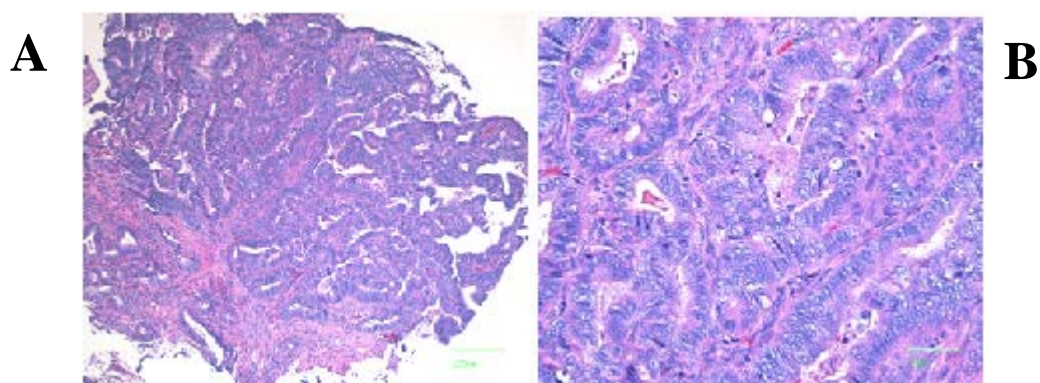
## ENDOMETRIOID ADENOCARCINOMA ARISING FROM APA

She underwent transcervical resection of the polypoid mass with hysteroscopy. The tumor arose from the lower uterine segment.

Pathological examination revealed atypical polypoid adenomyoma (APA) admixed with the foci of well-differentiated endometrioid adenocarcinoma. An adenomyomatous polyp was composed of proliferated endometrial glands with cellular atypia and interlacing bundles of spindle cells in the stroma (Figure 2A). Squamous morules were frequently noted within the hyperplastic glands (Figure 2B). Immunohistochemically, spindle cells were positive for  $\alpha$ -smooth muscle actin ( $\alpha$ -SMA) (Figure 2C) and h-Caldesmon, a marker of mature smooth muscles (Figure 2D). A focus of well-differentiated endometrioid adenocarcinoma shows a papillary or glandular growth-pattern and back-to-back arrangement. Tumor cells are somewhat large in size and the nuclei were relatively large and uniform. The prominent nucleoli were observed in some nuclei. Mitotic activity is poor (Figure 3A, 3B). She was diagnosed as having endometrioid adenocarcinoma arising in APA.



**Figure 2.** Microscopic findings of atypical polypoid adenomyoma. Proliferation of atypical or irregular glands in myomatous stroma, HE stain (A), Squamous moles in the glands lined by an atypical epithelium with nuclear atypia, HE stain (B), stromal cells being diffusely highlighted with  $\alpha$ -smooth muscle actin (C), and h-Caldesmon (D), original magnification x5 (A), x20 (B), x10 (C), and x10 (D)



**Figure 3.** A focal well-differentiated endometrioid adenocarcinoma. The tumor cells show a papillary or glandular growth-pattern, HE stain (A). Higher magnification shows confluent glands lined by slightly stratified cells and papillary infoldings in large glands, HE stain (B), original magnification x5 (A) and x20 (B)

We explained to her family that pathological examination diagnosed a concomitant existence of endometrioid adenocarcinoma in APA and that treatment of TCR alone without performing a hysterectomy may lead to the local recurrence. By obtaining the consent from the family, we determined to perform a hysterectomy. Subsequently, she underwent a total hysterectomy and bilateral salpingo-oophorectomy. Pathology showed no residual malignancy in the endometrium. The patient was diagnosed with clinical stage IA endometrial carcinoma according to the International Federation of Gynecology and Obstetrics (FIGO) system.

## DISCUSSION

We reported a rare case of coexistence of endometrioid adenocarcinoma in APA.

APA generally occurs in women of reproductive ages (mean age; 38 years), and the majority of patients are nulligravida (75.9%) and nullipara (86.2%) (5). The mean tumor diameter is 2.3 cm, and 58.6% of the tumor is pedunculated (5). Treatment consists of dilatation and curettage, vaginal resection, hysteroscopic transcervical resection (TCR), and hysterectomy.

Although APA is classified as a benign lesion, it has been reported to recur at a rate of 10% in patients treated with TCR and at a rate of 36.4% in those treated with other treatment options (5). Furthermore, APA is known to undergo progression to endometrial endometrioid adenocarcinoma (2,11) and to coexist with endometrioid adenocarcinoma (1,7,9). In our case, the foci of well-differentiated endometrioid adenocarcinoma were found within APA. The frequency of coexistence of adenocarcinoma in APA was reported to be 8.8% (3) and 17.2% (5).

APA is thought to be an indicator or precursor lesion for endometrial endometrioid adenocarcinoma (2,9,11). Our case also suggests that APA has a propensity for the development of adenocarcinoma. Nonetheless, the precise mechanism underlying the development of adenocarcinoma in APA remains poorly understood.

The mainstay for the treatment of coexistent endometrioid adenocarcinoma arising in APA appears to be a hysterectomy and bilateral salpingo-oophorectomy (1,9,11). Zhang and Chen (11) reported a case with persistent endometrial cancer after treatment of hysteroscopy alone and subsequent high dose progestin therapy. This patient was diagnosed as having APA with carcinoma after TCR. The hysterectomy was recommended, but she refused to do that due to a desire to preserve the fertility. Some areas of cancer remained despite three months' administration of high dose progestin, and underwent a hysterectomy and bilateral salpingo-oophorectomy. In our patient, we could not exclude the possibility of local recurrence when her uterus was retained after a simple excision of APA alone. We determined to perform a hysterectomy and bilateral salpingo-oophorectomy with obtaining the consent from her family.

Immunohistochemical examination revealed that stromal cells were diffusely positive for  $\alpha$ -SMA and h-Caldesmon. Our data of  $\alpha$ -SMA immunoreactivity were in agreement with the results of some authors showing that stromal component of APA were strongly positive for  $\alpha$ -SMA (2,8,10). Horita *et al.* (4) reported that the site of muscular invasion of endometrioid carcinoma showed a diffuse positive pattern in h-Caldesmon, whereas h-Caldesmon was immunonegative in APA. The reason for this discrepancy was undetermined. Further study is needed to clarify the difference in the staining pattern of h-Caldesmon.

In conclusion, awareness of a close association of APA with the occurrence of endometrial cancer is warranted. A meticulous pathological evaluation of specimen of APA is necessary for the detection of coexistence of endometrial cancer.

## REFERENCES

1. **Bakalianou, K., Salakos, N., Iavazzo, C., Paltoqlou, G., Papadias, K., and Kondi-Pafiti, A.** 2008. A case of endometrial carcinoma arising in a 36-year-old woman with uterine atypical polypoid adenomyoma (APA). *Eur J Gynaecol Oncol* **29**: 298-299.
2. **Fukuda, M., Sakurai, N., Yamamoto, Y., Taoka, H., Asakawa, Y., Kurasaki, A., Oharaseki, T., Takahashi, K., and Kubushiro, K.** 2011. Case of atypical polypoid adenomyoma that possibly underwent a serial progression from endometrial hyperplasia to carcinoma. *J Obstet Gynaecol Res* **37**: 468-471.
3. **Heatley, M.K.** 2006. Atypical polypoid adenomyoma: a systematic review of the English literature. *Histopathology* **48**: 609-610.
4. **Horita, A., Kurata, A., Maeda, D., Fukayama, M., Sakamoto, A.** 2011. Immunohistochemical characteristics of atypical polypoid adenomyoma with special reference to h-caldesmon. *Int J Gynecol Pathol* **30**: 64-70.
5. **Matsumoto, T., Hiura, M., Baba, T., Ishiko, O., Shiozawa, T., Yaegashi, N., Kobayashi, H., Yoshikawa, H., Kawamura, N., and Kaku, T.** 2013. Clinical management of atypical polypoid adenomyoma of the uterus. a clinicopathological review of 29 cases. *Gynecol Oncol* **129**: 54-57.
6. **Mazur, M.T.** 1981. Atypical polypoid adenomyomas of the endometrium. *Am J Surg Pathol* **5**: 473-482.

## ENDOMETRIOID ADENOCARCINOMA ARISING FROM APA

7. **Nejković, L., Pazin, V., and Filimonović, D.** 2013. Atypical polypoid adenomyoma mixed with endometrioid carcinoma: a case report. *Eur J Gynaecol Oncol* **34**: 101-103.
8. **Ohishi, Y., Kaku, T., Kobayashi, H., Aishima, S., Umekita, Y., Wake, N., Tsuneyoshi, M.** 2008. CD10 immunostaining distinguishes atypical polypoid adenomyofibroma (atypical polypoid adenomyoma) from endometrial carcinoma invading the myometrium. *Hum Pathol* **39**: 1446-1453.
9. **Sugiyama, T., Ohta, S., Nishida, T., Okura, N., Tanabe, K., and Yakushiji, M.** 1998. Two cases of endometrial adenocarcinoma arising from atypical polypoid adenomyoma. *Gynecol Oncol* **71**: 141-144.
10. **Terada, T.** 2011. Atypical polypoid adenomyoma of the uterus: an immunohistochemical study on 5 cases. *Ann Diagn Pathol* **15**: 338-341.
11. **Zhang, H.K., and Chen, W.D.** 2012. Atypical polypoid adenomyomas progressed to endometrial endometrioid adenocarcinomas. *Arch Gynecol Obstet* **286**: 707-710.