

## Molecular Analysis of *TSC2/PKD1* Contiguous Gene Deletion Syndrome

YOSHINOBU OYAZATO<sup>1\*</sup>, KAZUMOTO IJIMA<sup>1</sup>, MITSURU EMI<sup>2</sup>,  
TAKASHI SEKINE<sup>3</sup>, KOICHI KAMEI<sup>4</sup>, JUNICHI TAKANASHI<sup>5</sup>,  
HIDETO NAKAO<sup>6</sup>, YOSHIYUKI NAMAI<sup>7</sup>, KANDAI NOZU<sup>1</sup>,  
and MASAFUMI MATSUO<sup>1</sup>

<sup>1</sup>*Department of Pediatrics, Kobe University Graduate School of Medicine, Kobe, Japan.  
7-5-1, Chuo-ku, Kobe, Hyogo, Japan*

<sup>2</sup>*CNV laboratory, DNA Chip Research Institute, Yokohama, Japan.  
1-1-43, Suehiro-cho, Turumi-ku, Yokohama, Kanagawa, Japan*

<sup>3</sup>*Department of Pediatrics, Toho University Ohashi Medical Center, Tokyo  
2-17-6, Ohashi, Meguro-ku, Tokyo, Japan*

<sup>4</sup>*Department of Nephrology, National Center for Child Health and Development, Tokyo.  
2-10-1, Okura, Setagaya-ku, Tokyo, Japan*

<sup>5</sup>*Department of Pediatrics, Kameda Medical Center, Kamogawa  
929, Higashi-cho, Kamogawa, Chiba, Japan*

<sup>6</sup>*Department of Neonatology, Hyogo Prefectural Kobe Children's Hospital, Kobe  
1-1-1, Takakuradai, Suma-ku, Kobe, Hyogo, Japan*

<sup>7</sup>*Department of Pediatrics, Ohta Nishinouchi General Hospital, Koriyama  
2-5-20, Nishinouchi, Koriyama, Fukushima, Japan*

Received 11 January 2011/ Accepted 13 January 2011

**Key Words:** multiplex ligation-dependent probe amplification, array comparative genomic hybridization, tuberous sclerosis, autosomal dominant polycystic kidney disease, contiguous gene syndrome

**Background:** Tuberous sclerosis complex (TSC) is an autosomal dominant disorder caused by mutations in either of two genes, *TSC1* and *TSC2*. Autosomal dominant polycystic kidney disease (ADPKD) is caused by mutations in either *PKD1* or *PKD2*. *TSC2* lies immediately adjacent to *PKD1* and large heterozygous deletions can result in the *TSC2/PKD1* contiguous gene syndrome (PKDTS). PKDTS has been identified in patients with TSC and early-onset severe ADPKD. However, genetic diagnosis with conventional methods proved to be difficult because its genetic aberrations are large monoallelic mutations. **Methods:** In the study presented here, we used both multiplex ligation-dependent probe amplification (MLPA) and array comparative genomic hybridization (array-CGH) for four PKDTS patients. **Results:** We were able to detect large heterozygous deletions including *TSC2* and *PKD1* by both of MLPA and array-CGH in all four patients. And in two patients, array-CGH identified relatively large genomic aberrations (*RAB26*, *NTHL1*, etc.), that extended outside of *TSC2* or *PKD1*. **Conclusion:** The identical results obtained with these two completely different methods show that both constitute highly reliable strategies. Only a few studies have determined the breakpoints of large deletions in this disease and ours is the first to have

**identified the breakpoints by using array-CGH. We suggest that these methods are not only useful for the diagnosis of PKDTS but also for elucidation of its molecular mechanism.**

## INTRODUCTION

Tuberous sclerosis complex (TSC, MIM#191100) is an autosomal dominant neurocutaneous disorder characterized by hamartomatous growth abnormalities in multiple organ systems, including brain, skin, heart, lungs, and kidneys. Two genes, *TSC1* and *TSC2*, have been identified as responsible for TSC. It has been reported that the abnormality of *TSC2* occurs 4-5 times more often than that of *TSC1* in sporadic patients (8,15,23). Both *TSC1* and *TSC2* are tumor suppressor genes. Because heterozygous deletion has been identified in hamartoma-related lesions, it has been suggested that malignant transformation occurs as a result of the continued mutation of two hits occurring in both alleles (3,13,14). Kidney complications such as angiomyolipoma are found in 75-80% of TSC patients (11), and renal cysts (which are single in many patients) in one-third of these patients. The onset of renal cysts occurs in the second decade, which is later than for other TSC complications (19).

Autosomal dominant polycystic kidney (ADPKD, MIM#173900) is a disease characterized by progressive bilateral renal cysts and is sometimes complicated with liver cysts and intracranial aneurysms. The age at which clinical manifestations such as renal failure or hypertension occur varies. Renal function remains intact until the third or fourth decade of life of most patients, while the precise age for onset of renal cysts remains unknown. Early onset of symptoms is a risk factor for progressive renal disease, but children presenting with the disease in the first or second year of life usually do not progress rapidly to end-stage renal failure (12,26). ADPKD is genetically heterogeneous with two genes identified so far, *PKD1* and *PKD2*. The genetic aberration of *PKD1* gene has reportedly been found in 85% of patients (17,21), and 2-3% of *PKD1* mutations are large deletions that remove between one and several exons (2,14,29).

The *PKD1* gene is found 60bp downstream of *TSC2* in a tail-to-tail orientation. Large *PKD1* deletions that also disrupt the adjacent *TSC2* result in the *TSC2/PKD1* contiguous gene syndrome (PKDTS, MIM#600273). PKDTS, identified by Brook-Carter *et al.* in 1994 in TSC patients with severe infantile PKD, results in disruption of both the *TSC2* and *PKD1* genes (4). This finding made it clear that kidney symptoms are very severe in PKDTS and in some subsequent studies genetic diagnosis of PKDTS was performed by using the FISH method or quantitative real-time PCR (2,4,5,9,18,20).

Recently, multiplex ligation dependent probe assay (MLPA) and array comparative genomic hybridization (array-CGH) methods have been used to identify many aspects of widespread deletions/duplications known as copy number variations (CNVs) (16,24,25). In this report, we identified widespread heterozygous deletions including *TSC2* and *PKD1* by the MLPA and array-CGH in four PKDTS patients. Also, we examined the genotype-phenotype correlations in this disease including previously reported patients with clarified breakpoints of the large deletions.

## METHODS

### Patients Report

We studied four unrelated patients with tuberous sclerosis and multiple bilateral renal cysts (Table. I). All four patients fulfilled the definitive criteria for TSC in infancy, and at the

## MOLECULAR ANALYSIS OF *TSC2/PKD1* DELETION SYNDROME

same time had been diagnosed as PKD. All patients except patient 3 show intractable epilepsy and mental retardation. Patient 4 shows renal dysfunction (CKD stage 3). At present, the complications for ADPKD (liver cysts and intracranial aneurysm) have not been found in all patients.

This study was approved by the Institutional Review Board of Kobe University Graduate School of Medicine and consent for this study was obtained from the patients' parents.

### **Molecular analysis**

Genomic DNA was extracted and purified from peripheral leukocytes in whole-blood samples by means of a QIAamp DNA blood kit (QIAGEN, Tokyo, Japan). Probable identified deletions were confirmed with multiple ligation-dependent probe amplification (MLPA) assays using an MLPA kit (SALSA MLPA P046-B2 *TSC2*, Lot 0508; MCR-Holland, Amsterdam, The Netherlands) ([www.mlpa.com](http://www.mlpa.com)), which contains probes for 32 of the 41 exons of *TSC2*. In addition, the MLPA kit contains one probe for exon 46 of the *PKD1* gene next to *TSC2* and eight reference probes for sequences located on other chromosomes. With this kit, heterozygous deletions of probe recognition sequences should yield a 35-50% reduction in the relative peak area of the amplification product of that probe. MLPA was performed as per the general directions provided by MRC-Holland.

We subsequently performed array-CGH analysis to identify the boundaries of the deleted region involving *TSC2* and *PKD1*. For array-CGH, we used SurePrint G3 Human CNV Microarray Kit 2x400K (Agilent Technologies, Santa Clara, CA), consisting of 450,288 probes. Array-CGH experiments were performed according to the manufacturer's instructions. Only the range from 1.7Mb to 2.44Mb of chromosome 16p13.3 is shown, where *TSC2*, *PKD1*, and flanking genes are located.

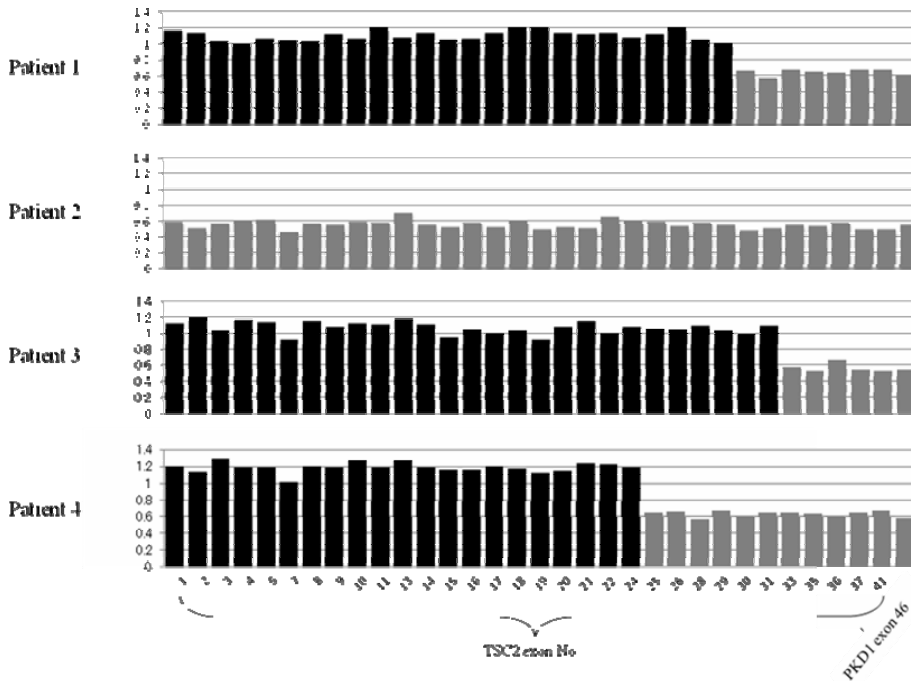
### **Clinical presentation of this disease**

To investigate genotype-phenotype correlations, we searched the entire previous literature for patients whose clinical manifestations and genomic deletion ranges were described in detail. We found only 11 patients (in six reports (2,9,118,20,15,28)) whose findings, including deletion breakpoints and precise clinical features, were described in sufficient detail. We then added data for these 11 patients to those for our four patients and listed them in Table 2. Although the genomic analytical methods used for these previous studies varied, the deletion ranges were identified, do that we could compare these reported genomic aberrations with the clinical features.

## **RESULTS**

### **MLPA analysis**

The results of the *TSC2* analysis by MLPA are shown in Figure 1. When the ratio drops from 0.5 to 0.65, it means that the genomic copy number is reduced by half, thus indicating heterozygous deletions. MLPA showed large heterozygous deletions of the *TSC2* gene in all patients: exons 30-41 in patient 1, all *TSC2* exons in patient 2, exons 33-41 in patient 3, and exons 25-41 in patient 4 (Fig. 1). All patients showed heterozygous deletions of *PKD1* exon 46 downstream of *TSC2*. These findings led to a diagnosis of PKDTS for all four patients.



**Figure 1.** MLPA analysis MLPA data for TSC2 and PKD1 is indicated, with details of specific probes. Gray bars show reductions by half of genomic quantity, it means heterozygous deletions.

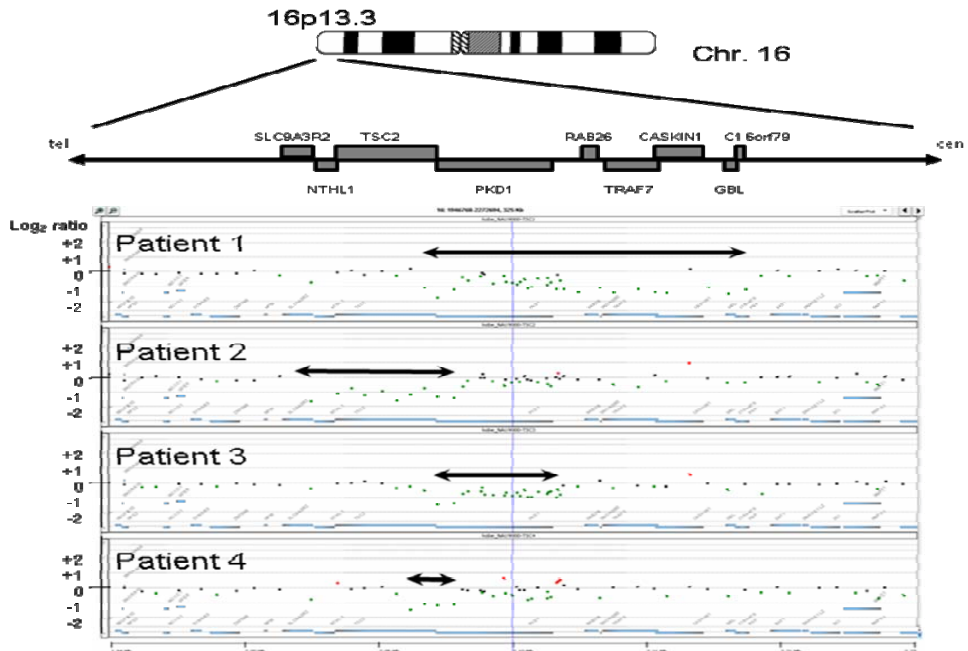
### Array-CGH analysis

Array-CGH for the 16p13.3 locus (Fig. 2) detected reduction by half of the genomic copy number of *TSC2* and *PKD1* and large heterozygous deletions in all patients. The heterozygous deletion ranges for *TSC2* agree with the results obtained with MLPA. In patient 2, not only were large heterozygous deletions of *TSC2* detected but also reduction in the genome copy number of *NTHL1* and *SLC9A3R2* which are upstream and adjacent genes. As for PKD, heterozygous deletions of *PKD1* were also identified in all patients. Patients 1 and 3 showed complete *PKD1* gene deletions, and patients 2 and 4 partial heterozygous deletions of *PKD1*. Furthermore, in patient 1 we detected a reduction in the genomic copy number of the gene region (*RAB26*, *TRAF7*, *CASKINI*) which is downstream from *PKD1*.

### Clinical presentation

Clinical features and genomic aberrations are summarized in Table 1. We also examined the potential associations between various aspects of clinical phenotype and extent of deletion in *TSC2*, *PKD1*, and other genomic regions, including those of the 11 patients found in the previous literature (Table 2), whose genomic aberrations were identified by various methods (Southern blot, FISH, quantitative PCR, and MLPA (2,9,118,20,15,28)). Our investigation found few patients showing liver cysts or intracranial aneurysms. However, there were no genotype-phenotype correlations for this disease as were previously reported for neurological and renal symptoms.

## MOLECULAR ANALYSIS OF *TSC2*/*PKD1* DELETION SYNDROME



**Figure 2.** Array comparative genomic hybridization (array-CGH) analysis  
 Array-CGH data for 16p13.3 is indicated. Gray bars show the range of heterozygous deletions. Upper map shows the positions of *TSC2*, *PKD1*, and flanking genes in 16p13.3.

**Table.I** Comparison between clinical feature and genetic aberration in our four patients

| Patient No                                      | 1           | 2           | 3          | 4           |
|---|-------------|-------------|------------|-------------|
| Current age (years)                             | 7           | 4           | 3          | 17          |
| Diagnosis age of TSC<br>(months)                | 24          | 2           | 0          | 2           |
| Epilepsy control                                | intractable | intractable | good       | intractable |
| Mental retardation                              | moderate    | severe      | borderline | severe      |
| Diagnosis age of PKD<br>(months)                | 24          | 3           | 8          | 2           |
| Estimated GFR<br>(ml/min/1.73.2m <sup>2</sup> ) | 113.9       | 95.3        | 85.9       | 33.3        |
| Stage of chronic renal<br>disease               | 1           | 1           | 2          | 3           |
| Liver cysts                                     | -           | -           | -          | -           |
| Intracranial aneurysms                          | -           | -           | -          | -           |
| <i>TSC2</i> deletions<br>(exon No)              | 30-41       | all         | 33-41      | 25-41       |
| <i>PKD1</i> deletions                           | all         | partial     | all        | partial     |

TSC=tuberous sclerosis

PKD=polycystic kidney disease

GFR= glomerular filtration rate

**Table 2. Presentation of patients with PKDTS**

| Age at reported | TSC              |          |                    |                    |                            |                  | PKD                  |             |                        |           | genomic aberration |                     |  |                 | references |
|-----------------|------------------|----------|--------------------|--------------------|----------------------------|------------------|----------------------|-------------|------------------------|-----------|--------------------|---------------------|--|-----------------|------------|
|                 | Age of diagnosis | Epilepsy | Mental retardation | Endocranial lesion | Renal angiomatoid polypoma | Age of diagnosis | Prognosis            | Liver cysts | Intracranial aneurysms | size      | TSC2               | PKD1                | LOH of other genes   | Methods         |            |
| 30yr            | 12yr             | +        | moderate           | +                  | NR                         | 12yr             | renal failure (28yr) | +           | +                      | 175kb     | all                | partial             | NTHL1, SLC9A3R2, NPW                                       | Southern blot   | [20]       |
| death (47yr)    | NR               | NR       | NR                 | NR                 | +                          | 34yr             | renal failure (42yr) | NR          | NR                     | 175kb     | all                | partial             | NTHL1, SLC9A3R2, NPW                                       | Southern blot   | [20]       |
| 34yr            | 4yr              | +        | +                  | +                  | +                          | 19yr             | renal failure (19yr) | NR          | NR                     | 260kb     | all                | all                 | unknown *  | Southern blot   | [20]       |
| death (46yr)    | NR               | -        | moderate           | NR                 | NR                         | 44yr             | renal failure (46yr) | 44yr        | NR                     | 280kb     | all                | all                 | NTHL1, RAB26, SNORD60, TRAF7, CASKIN1, AF7, CASKIN1, RNPS1 | FISH            | [9]        |
| 26yr            | 13yr             | +        | -                  | +                  | +                          | -                | NR                   | +           | -                      |           | all                | partial             | NTHL1, SLC9A3R2  | FISH            | [28]       |
| 3yr             | 3mo              | +        | NR                 | +                  | NR                         | 3m               | normal               | -           | -                      |           | all                | all                 | unknown *  | FISH            | [18]       |
| death (42yr)    | 20yr             | -        | -                  | +                  | +                          | 20yr             | nephrectomy (35yr)   | +           | -                      | 141kb     | all                | all                 | RAB26, TRAF7, CASKIN1                                      | qPCR            | [2]        |
| NR              | NR               | +        | mild               | NR                 | NR                         | 31yr             | nephrectomy (33yr)   | NR          | NR                     | >240kb    | all                | all                 | NTHL1, SLC9A3R2, ZNF598, TRAF7, BL3, RN151                 | MLPA            | [25]       |
| NR              | NR               | NR       | NR                 | NR                 | NR                         | 12yr             | nephrectomy (30yr)   | NR          | NR                     | 100-120kb | all                | partial             | NTHL1, SLC9A3R2, ZNF598                                    | MLPA            | [25]       |
| NR              | NR               | +        | +                  | NR                 | NR                         | 2yr              | hypertension         | NR          | NR                     |           | exon30-41          | partial (exon23-46) | -  | MLPA            | [25]       |
| NR              | NR               | NR       | NR                 | NR                 | NR                         | 5yr              | normal               | NR          | NR                     |           | exon41             | partial (exon34-46) | -  | MLPA            | [25]       |
| 7yr             | 2yr              | +        | borderline         | +                  | -                          | 2yr              | stage1 CRD           | -           | -                      | 129.8kb   | exon 30-41         | all                 | RAB26, TRAF7, CASKIN1, GB, LO1, 6orf79                     | MLPA, array-CGH | Patient 1  |
| 4yr             | 2mo              | +        | moderate           | +                  | -                          | 3mo              | stage1 CRD           | -           | -                      | 58.0kb    | all                | partial             | NTHL1, SLC9A3R2  | MLPA, array-CGH | Patient 2  |
| 3yr             | at birth         | +        | severe             | +                  | -                          | 8mo              | stage2 CRD           | -           | -                      | 54.9kb    | exon 33-41         | all                 | -  | MLPA, array-CGH | Patient 3  |
| 17yr            | 2mo              | +        | severe             | +                  | -                          | unknown          | stage3 CRD           | -           | -                      | 18.0kb    | exon 25-41         | partial             | -  | MLPA, array-CGH | Patient 4  |

\*: The exact deletion range is unknown, but the deletion is very extensive from upstream of TSC todownstream of PKD1

TSC: tuberous sclerosis

PKD: polycystic kidney disease

NR: not reported

FISH: fluorescence in situ hybridization

qPCR: quantitative real-time polymerase chain reaction

MLPA: multiplex ligation-dependent probe amplification

array-CGH: array comparative genomic hybridization

## MOLECULAR ANALYSIS OF *TSC2/PKDI* DELETION SYNDROME

In this study, we were able to diagnose PKDTS by means of MLPA and array-CGH in all four of our patients. MLPA was able to detect the genomic aberration of *TSC2* by exon unit. By using the same MLPA kit as employed in our study, Kozłowski et al. identified patients as PKDTS (7,16,17). Furthermore, Kozłowski et al. and Consugar et al. conducted analysis using custom made kits (7,17). They could successfully detect copy number losses in several patients with PKDTS. In their studies, they also identified other deletion genes by using their original probes, though this MLPA is able to examine only exon 46 as for *PKDI*. Therefore we conclude that this MLPA facilitates the diagnosis of PKDTS, but is not suitable for the identification of the deletion range.

We also performed array-CGH analysis in this study to detect deletional breakpoints and ours is the first report of the successful identification of the breakpoints using array-CGH for PKDTS. Array-CGH is able to identify the boundaries of the changes in genome copy numbers although MLPA analysis could detect relatively narrow area and usually miss the boundaries of the large rearrangement. Indeed, in two patients in our study, array-CGH identified relatively large genomic aberrations (*RAB26*, *NTHL1*, etc.), that extended outside of *TSC2* or *PKDI*.

We also examined genotype-phenotype correlations between the deletion range of *TSC2* and *PKDI* and their clinical severities for the 15 patients (Table 2) (2,9,118,20,15,28). However, neither TSC nor PKD showed any correlation between clinical features and clearly identified deletion range. PKDTS did not influence the severity of the symptoms of TSC except its renal complications, including those previously reported. Some authors previously reported the possibility that severity of epilepsy is associated with somatic mosaic deletions (7,16,22), and that patients with such deletions showed milder neurological phenotypes. By using the same MLPA kit as employed in our study, Kozłowski et al. and Consugar et al. identified patients with mosaic deletion (7,16), indicating that this MLPA kit is also sensitive enough for detection of mosaic deletion. Since there were no patients with somatic mosaic deletions in our study, we could not evaluate the correlation between mosaic deletions and clinical features. As for PKD, their onset tended to be at early age and their renal dysfunction more severe, although few patients had liver cysts or intracranial aneurysms from an early age. These findings demonstrate that PKDTS is associated exclusively with the severity of kidney symptoms, and not with the severity of TSC, liver cysts, and intracranial aneurysms. In the patients of PKDTS, only kidney findings can be enhanced by these digenic defects.

The mechanism for PKDTS is nearly unknown. As for TSC, it has been suggested that the hamartin(*TSC1*)-tuberin(*TSC2*) and mTOR pathway is important (3,13,27). However, because many other factors influence this pathway, the actual molecular mechanism of TSC remains unknown. As for ADPKD, some mechanisms involving polycystin-1 (PC1, product of *PKDI*) have been reported, although it is not known which of these proposed mechanisms are critical for renal cyst formation (10,17,21). There are also reports that PC1 acts have a direct or indirect effect on suppression of the mTOR activity (3). In a recent model mouse study, *TSC2* and *PKDI* were found to act on different points of the pathway (i.e., *TSC2* acts on ciliary formation and *PKDI* on sensing fluid flow), and co-activity of *TSC2* and *PKDI* is associated with aggravation of the clinical course (6,13). Because hamartin, tuberin and polycystin-1 become keys to the maintenance of cell polarity, their collapse results in enlargement of the cysts by cytotogenesis and mTOR activation (3). Although these studies have resulted in a partial assessment of the mechanism of severe renal phenotypes in PKDTS patient, it is still unknown why PKDTS causes aggravation only in kidney phenotypes, which suggests that there may be other factors which influence the severity of this disease. Further genetic and clinical studies are thus required to elucidate the mechanism of PKDTS.

## CONCLUSION

We used two new techniques, MLPA and array-CGH, for the diagnosis of PKDTS in four TSC patients who had contracted PKD in infancy. Both methods proved to be reliable and robust for the diagnosis of PKDTS. We also examined genotype-phenotype correlations in our as well as in previously reported patients, but we were not able to find any definite correlations. Other modifier genes or environmental factors may contribute to progression of PKDTS. We established that contiguous gene deletions appear to enhance only the kidney symptoms. The mechanism for PKD remains unclear at present. We conclude that MLPA and array-CGH methods are useful for further large-scale investigations of PKDTS.

## ACKNOWLEDGEMENT

We thank Ms. N. Ito and Dr H. Sato for their help with array-CGH analysis, Drs. Ken-ichi Matsubara, Takashi Igarashi and Shuichi Ito for their helpful advice, and Ms. Yoshimi Nozu for her help with the genetic analysis. This study was supported by a Grant in Aid for Scientific Research (B-20380240) (to K. I.) and a Grant-in-Aid for Young Scientists (B-19790720) (to K.N.) from the Japan Society for the Promotion of Science.

## FUNDING

This study was supported by a Grant-in-Aid for Scientific Research (B-20380240) (to K. I.) and a Grant-in-Aid for Young Scientists (B-19790720) (to K.N.) from the Japan Society for the Promotion of Science.

## REFERENCES

1. **Ariyurek, Y., Lantinga-van, Leeuwen, I., Spruit, L., Ravine, D., Breuning, M.H., Peters D.J.** 2004. Large deletions in the polycystic kidney disease 1 (PKD1) gene. *Hum. Mutat.* **23**: 99.
2. **Boehm, D., Bacher, J., Neumann, HP.** 2007. Gross genomic rearrangement involving the TSC2-PKD1 contiguous deletion syndrome: characterization of the deletion event by quantitative polymerase chain reaction deletion assay. *Am. J. Kidney Dis* **49**: e11-e21.
3. **Bonnet, C.S., Aldred, M., von Ruhland, C. Harris, R., Sandford, R., Cheadle, J.P.** 2009. Defects in cell polarity underlie TSC and ADPKD-associated cystogenesis. *Hum. Mol. Genet.* **18**: 2166-2176.
4. **Brook-Carter, P. T., Peral, B., Ward, C. J., Thompson, P., Hughes, J., Maheshwar, M.M., Nellist, M., Gamble, V., Harris, P. C., Sampson, J. R.** 1994. Deletion of the TSC2 and PKD1 genes associated with severe infantile polycystic kidney disease--a contiguous gene syndrome. *Nat. Genet.* **8**: 328-332.
5. **Brown, J., Horsley, S.W., Jung, C., Saracoglu, K., Janssen, B., Brough, M., Daschner, M., Beedgen, B., Kerkhoffs, G., Eils, R., Harris, P.C., Jauch, A., Kearney, L.** 2000 Identification of a subtle t(16;19)(p13.3;p13.3) in an infant with multiple congenital abnormalities using a 12-colour multiplex FISH telomere assay, M-TEL. *Eur.*



## MOLECULAR ANALYSIS OF *TSC2/PKD1* DELETION SYNDROME

- J. Hum. Genet. **8**: 903-910.
6. **Cai, S., Everitt, J.I., Kugo, H., Cook, J., Klymenova, E., Walker, C.L.** 2003. Polycystic kidney disease as a result of loss of the tuberous sclerosis 2 tumor suppressor gene during development. *Am. J. Pathol.* **162**: 457-468.
  7. **Consugar, M. B., Wong, W. C., Lundquist, P. A., Rossetti, S. Kubly, V. J., Walker D. L., Rangel L.J., Aspinwall, R., Niaudet, W. P., Ozen, S., David, A., Velinov, M., Bergstralh, E. J., Bae, K. T., Chapman, A. B., Guay-Woodford, L. M., Grantham, J. J., Torres, V. E., Sampson, J. R., Dawson, B. D., Harris, P. C.** 2008. Characterization of large rearrangements in autosomal dominant polycystic kidney disease and the PKD1/TSC2 contiguous gene syndrome. *Kidney Int.* **74**: 1468-1479.
  8. **Dabora, S.L., Jozwiak, S., Franz, D.N., Roberts, P.S., Nieto, A., Chung, J., Choy, Y.S., Reeve, M.P., Thiele, E., Egelhoff, J.C., Kasprzyk-Obara, J., Domanska-Pakiela, D., Kwiatkowski, D.J.** 2001. Mutational analysis in a cohort of 224 tuberous sclerosis patients indicates increased severity of TSC2, compared with TSC1, disease in multiple organs. *Am. J. Hum. Genet.* **68**: 64-80.
  9. **Dauwerse, J.G., Bouman, K., van Essen, A.J., van der Hout, A.H., Kolsters, G., Breuning, M.H., Peters, D.J.** 2002. Acrofacial dysostosis in a patient with the TSC2-PKD1 contiguous gene syndrome. *J. Med. Genet.* **39**: 136-141.
  10. **Distefano, G., Boca, M., Rowe, I. Wodarczyk, C., Ma, L., Piontek, K.B., Germino, G.G., Pandolfi, P.P., Boletta, A.** 2009. Polycystin-1 regulates extracellular signal-regulated kinase-dependent phosphorylation of tuberin to control cell size through mTOR and its downstream effectors S6K and 4EBP1. *Mol. Cell Biol.* **29**: 2359-2371.
  11. **Ewalt, D.H., Sheffield, E., Sparagana, S.P., Delgado, M.R., Roach, E.S.** 1998. Renal lesion growth in children with tuberous sclerosis complex. *J. Urol.* **160**: 141-145.
  12. **Fick, G.M., Johnson, A.M., Strain, J.D., Kimberling, W.J., Kumar, S., Manco-Johnson, M.L., Duley, I.T., Gabow, P.A.** 1993. Characteristics of very early onset autosomal dominant polycystic kidney disease. *J. Am. Soc. Nephrol.* **3**: 1863-1870.
  13. **Hartman, T.R., Liu, D., Zilfou, J.T., Robb, V., Morrison, T., Watnick, T., Henske, E.P.** 2009. The tuberous sclerosis proteins regulate formation of the primary cilium via a rapamycin-insensitive and polycystin 1-independent pathway. *Hum. Mol. Genet.* **18**: 151-163.
  14. **Henske, EP.** 2005. Tuberous sclerosis and the kidney: from mesenchyme to epithelium, and beyond. *Pediatr. Nephrol.* **20**: 854-857.
  15. **Jones, A.C., Shyamsundar, M.M., Thomas, M.W., Maynard, J., Idziaszczyk, S., Tomkins, S., Sampson, J.R., Cheadle, J.P.** 1999. Comprehensive mutation analysis of TSC1 and TSC2-and phenotypic correlations in 150 families with tuberous sclerosis. *Am. J. Hum. Genet.* **64**: 1305-1315.
  16. **Kozłowski, P., Roberts, P., Dabora, S. David, F., Johon B., Hope, N., Kit, S. A., Ross, L., Dorota, D., Katarzyna, K., Sergiusz, J., David, J. K.** 2007. Identification of 54 large deletions/duplications in TSC1 and TSC2 using MLPA, and genotype-phenotype correlations. *Hum. Genet.* **121**: 389-400.
  17. **Kozłowski, P., Bissler, J., Pei, Y., Davit, J. K.** 2008. Analysis of PKD1 for genomic deletion by multiplex ligation-dependent probe assay: absence of hot spots. *Genomics.* **91**: 203-208.
  18. **Laass, M.W., Spiegel, M., Jauch, A., Hahn, G., Rupperecht, E., Vogelberg, C., Bartsch, O., Huebner, A.** 2004. Tuberous sclerosis and polycystic kidney disease in a

- 3-month-old infant. *Pediatr. Nephrol.* **19**: 602-608.
19. **Leung, A.K., Robson, W.L.** 2007. Tuberous sclerosis complex: a review. *J. Pediatr. Health Care.* **21**: 108-114.
  20. **Longa, L., Scolari, F., Brusco, A. Carbonara, C., Polidoro, S., Valzorio, B., Riegler, P., Migone, N., Maiorca, R.** 1997. A large TSC2 and PKD1 gene deletion is associated with renal and extrarenal signs of autosomal dominant polycystic kidney disease. *Nephrol. Dial. Transplant.* **12**: 1900-7.
  21. **Rossetti, S., Harris, P.C.** 2007. Genotype-phenotype correlations in autosomal dominant and autosomal recessive polycystic kidney disease. *J. Am. Soc. Nephrol.* **18**: 1374-1380.
  22. **Sampson, J.R., Maheshwar, M.M., Aspinwall, R. Thompson, P., Cheadle, J.P., Ravine, D., Roy, S., Haan, E., Bernstein, J., Harris, P.C.** 1997. Renal cystic disease in tuberous sclerosis: role of the polycystic kidney disease 1 gene. *Am. J. Hum. Genet.* **61**: 843-851.
  23. **Sancak, O., Nellist, M., Goedbloed, M., Elfferich, P., Wouters, C., Maat-Kievit, A., Zonnenberg, B., Verhoef, S., Halley, D., van den Ouweland.** 2005. Mutational analysis of the TSC1 and TSC2 genes in a diagnostic setting: genotype--phenotype correlations and comparison of diagnostic DNA techniques in Tuberous Sclerosis Complex. *Eur. J. Hum. Genet.* **13**: 731-41.
  24. **Schouten, J.P., McElgunn, C.J., Waaijer, R., Zwijnenburg, D., Diepvens, F., Pals, G.** 2002. Relative quantification of 40 nucleic acid sequences by multiplex ligation-dependent probe amplification. *Nucleic. Acids. Res.* **30**: e57.
  25. **Sellner, L.N., Taylor, G.R.** 2004. MLPA and MAPH: new techniques for detection of gene deletions. *Hum. Mutat.* **23**: 413-419.
  26. **Shamshirsaz, A.A., Reza, Bekheirnia, M., Kamgar, M., Johnson, A.M., McFann, K., Cadnapaphornchai, M., Nobakthaghghi, N., Schrier, R.W.** 2005. Autosomal-dominant polycystic kidney disease in infancy and childhood: progression and outcome. *Kidney Int.* **68**: 2218-24.
  27. **Shillingford, J.M., Murcia, N.S., Larson, C.H., Low, S.H., Hedgepeth, Brown, N., Flask, C.A., Novick, A.C., Goldfarb, D.A., Kramer-Zucker, A., Walz, G., Piontek, K.B., Germino, G.G., Weimbs, T.** 2006. The mTOR pathway is regulated by polycystin-1, and its inhibition reverses renal cystogenesis in polycystic kidney disease. *Proc. Natl. Acad. Sci. U S A.* **103**: 5466-5471.
  28. **Smulders, Y.M., Eussen, B.H., Verhoef, S. Wouters, C.H.** 2003. Large deletion causing the TSC2-PKD1 contiguous gene syndrome without infantile polycystic disease. *J. Med. Genet.* **40**: E17.
  29. **The European Polycystic Kidney Disease Consortium.** 1994. The polycystic kidney disease 1 gene encodes a 14 kb transcript and lies within a duplicated region on chromosome 16. *Cell* **77**: 881-894.