

A Case of Malignant Melanoma of the Oral Cavity Alive with Liver Metastasis for a Long Period with Administration of a Biologic Response Modifier, OK432

MASAHIRO UMEDA*, MAHO MURATA, HIROAKI SUZUKI,
TADAHIKO YANAGIDA, YASUYUKI SHIBUYA,
and TAKAHIDE KOMORI

*Department of Oral and Maxillofacial Surgery, Kobe University Graduate School of
Medicine, 7-5-1Kusunoki-cho, Chuo-ku, Kobe, 650-0017, Japan.*

Received 17 September 2009/ Accepted 8 February 2010

Key Words: Malignant melanoma of the oral cavity, liver metastasis, biologic response modifier, OK432

A patient with malignant melanoma of the oral cavity who lived for a long period despite developing liver metastasis is presented. An 81-year-old female was referred to our hospital because of a pigmented tumor of the lower gingiva. Under the clinical diagnosis of malignant melanoma, she underwent bilateral functional neck dissection and marginal mandiblectomy. Histological diagnosis of the operation material was malignant melanoma with regional lymph node metastasis. In spite of loco-regional control, liver metastasis developed at 7 months after the surgery. She then underwent combination chemotherapies with dimethyl triazeno imidazole carboxamide (DTIC), nimustine hydrochloride (ACNU) and vincristin (DAV therapy), or cisplatin, DTIC, ACNU and tamoxifen (DAC-tam), but no marked response was obtained. Considering the advanced age of the patient, immunotherapy with a biological response modifier, OK432, alone was started. After administration of OK432, the metastatic tumor gradually decreased, and she is alive without any clinical symptoms of tumor at 46 months after the detection of liver metastasis, although it is still present on ultrasonic and CT examinations.

The frequency of malignant melanoma of the oral cavity among Japanese people is much higher than that among Caucasians. Nevertheless, the treatment method as well as the classification for oral melanoma remain controversial^{30,32)}. We previously reported that oral melanoma patients can obtain a good prognosis when an appropriate therapy is used without a preoperative surgical procedure such as incisional biopsy or tooth extraction³³⁾. However, the prognosis of patients with oral melanoma who developed distant metastases is extremely poor. We present here a new case of malignant melanoma occurring in the mandibular gingiva who has been alive for a long period despite liver metastasis with administration of a biological response modifier, OK432.

MALIGNANT MELANOMA OF THE ORAL CAVITY

CLINICAL CASES

An 81-year-old female visited a dental clinic with a chief complaint of a black tumorous lesion with pain in the anterior mandibular gingiva. Her dentist extracted the left side lateral incisor, but the symptoms did not improve, and she was referred to our hospital 2 weeks later. Clinical examinations revealed a black nodule in the anterior mandibular gingiva surrounded by a black plaque and macular lesions (Fig. 1). Panorama X-ray showed alveolar bone resorption in the region of $\overline{1+3}$ (Fig. 2). No enlarged cervical lymph nodes and no metastases to the lung or liver were found by CT examinations. Under the clinical diagnosis of malignant melanoma, she underwent surgery.

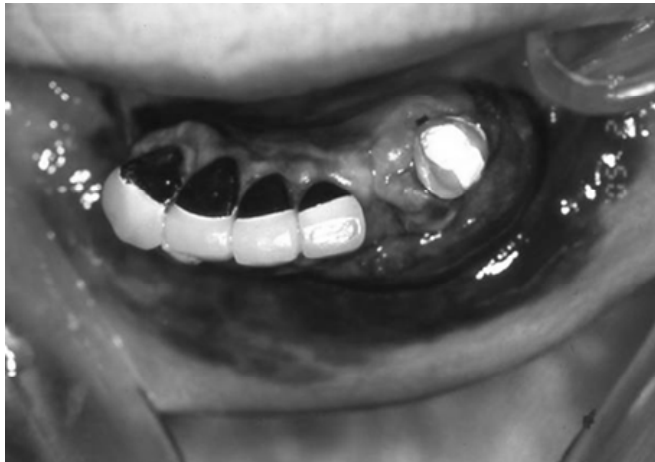

Figure1. Intraoral findings showing a black nodule surrounded by pigmented plaque and macular lesions in the mandibular gingiva.

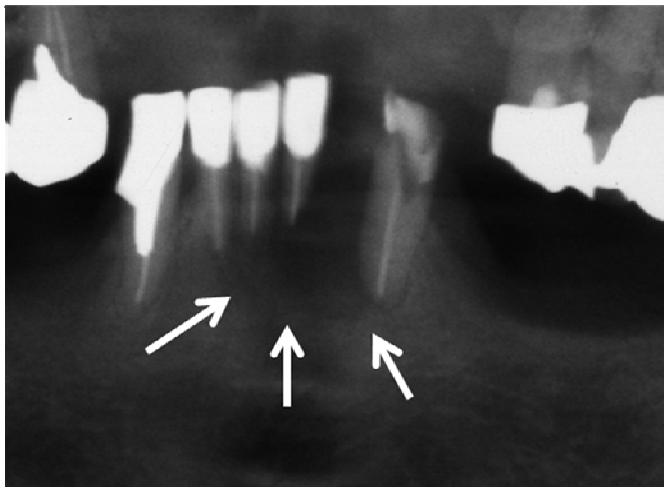


Figure2. Panoramic X-ray image shows diffuse bone resorption of the alveolar process of the mandible around the apical region of the left lateral incisor.

Since a black lymph node was observed in the right level IB neck during the operation, bilateral functional neck dissection and marginal mandibulectomy were performed. Resection was done at least 10 mm from the pigmented nodule and 5 mm from the macular lesion (Fig. 3). Histological examinations of the resected material showed malignant melanoma of the gingiva invading into the mandibular bone with a tumor thickness of 15 mm, and a single lymph node metastasis to the right level IB neck (Fig. 4).

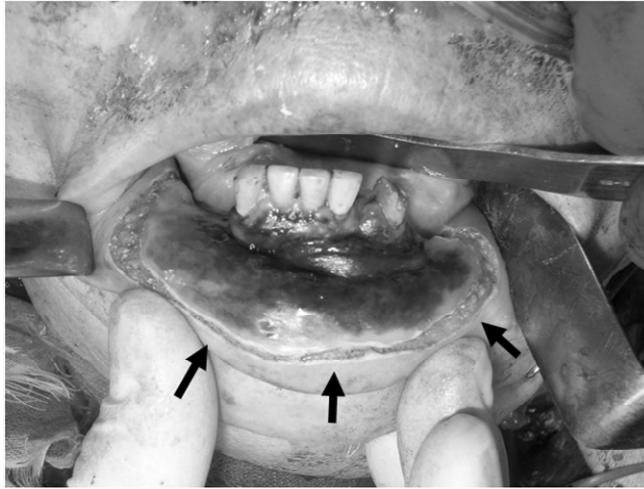


Figure3. Incision line of the intraoral tumor (arrows). Resection was done at least 5mm from the macular lesion. Bilateral functional neck dissection and marginal mandibulectomy were also performed.

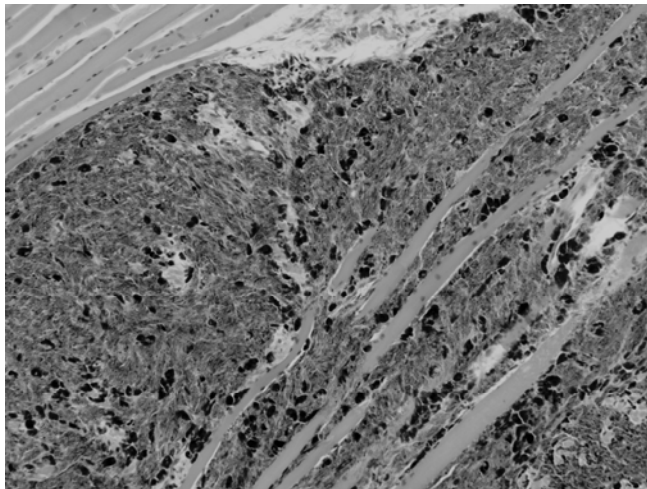


Figure4. Histological findings of the intraoral tumor (HE stain, original magnification X200).

She was free from loco-regional recurrence, but ultrasonic images showed liver metastasis at 7 months after surgery. One course of DAV therapy with dimethyl triazeno imidazole carboxamide (DTIC), nimustine hydrochloride (ACNU), and vincristine was

MALIGNANT MELANOMA OF THE ORAL CAVITY

performed. The following administration schedule was used: DTIC, 100 mg (day 1) and 200 mg (days 2-5); ACNU, 100 mg (day 1); vincristine, 1 mg (day 1). Further, another two courses of DAC-tam therapy with cisplatin (CDDP), DTIC, ACNU, and tamoxifen were added. The administration schedule was as follows: CDDP, 20 mg (days 1-3); DTIC, 200 mg (days 1-3); ACNU, 80 mg (day 1); tamoxifen, 20 mg (P.O. days 1-28).

The size of the metastatic liver tumor decreased after one course of DAV chemotherapy, but it soon grew larger despite an additional two courses of DAC-tam chemotherapy (Fig. 5). Considering the advanced age of the patient, aggressive chemotherapy was avoided and administration of OK432 was started. OK432 is a biologic response modifier consisting of a lyophilized powder made from cultures of penicillin-treated, low-Su-strain human *Streptococcus pyogenes* (Picibanil®, Chugai Pharmaceutical Co. Ltd., Shizuoka, Japan). Five Klinische Einheit (KE) (1 KE corresponding to 0.1mg of lyophilized bacilli) was injected subcutaneously every 2 weeks. After administration of OK432, the size of the metastatic tumor gradually decreased (Fig. 5). She is alive without any clinical symptoms of tumor at 46 months after the detection of liver metastasis, although the metastasis is still present on ultrasonic and CT examinations.

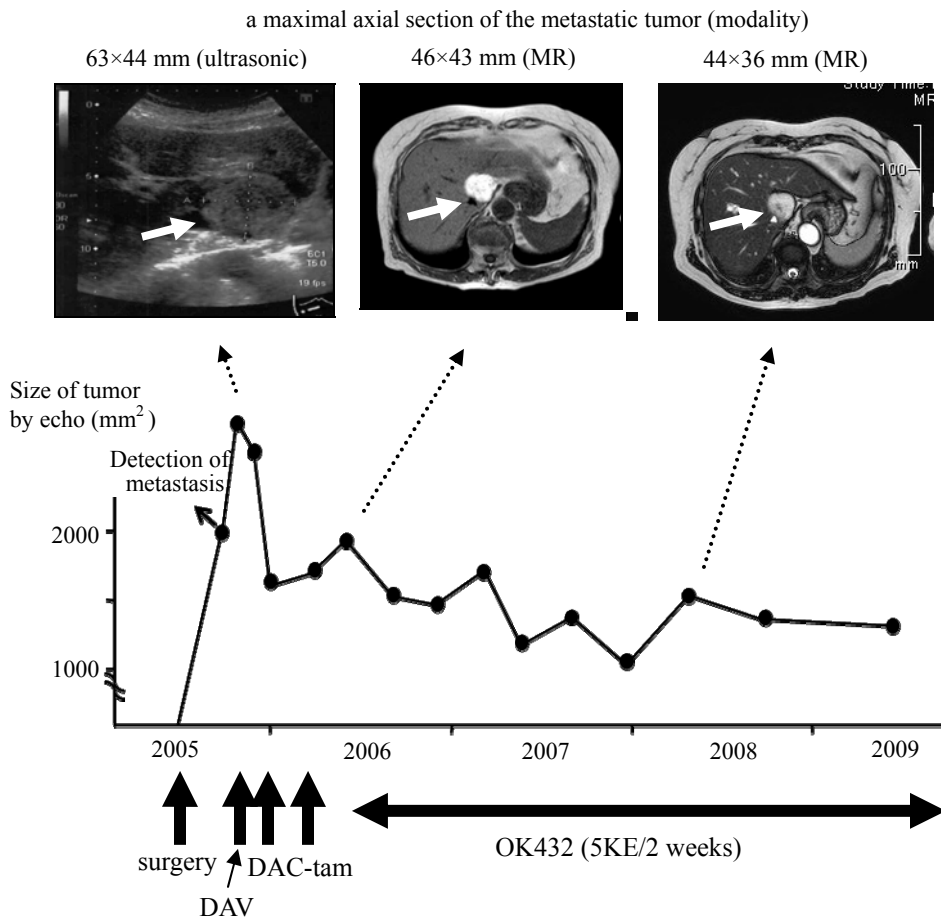


Figure 5. Changes in the size of the metastatic melanoma of the liver (arrows). The patient is still alive at 46 months after detection of the liver metastasis without tumor progression.

DISCUSSION

The prognosis of oral melanoma patients has been reported to be extremely poor. According to the recent literature, 5-year survival rate for oral melanoma patients was only 0%²⁸⁾, 6.6%²¹⁾, 13.5%²⁶⁾, 15%¹⁴⁾, 21.8%²⁹⁾, 25%⁸⁾, 30%¹¹⁾, 35%²⁷⁾, and 45%²³⁾. We have treated oral melanoma patients since 1980 with the following treatment protocols: (1) surgical resection of intraoral tumors; (2) neck dissection for clinically detected lymph node metastasis; (3) initiation of adjuvant immunochemotherapy with DTIC, ACNU, VCR, and OK432 on the day of surgery; and (4) no biopsy because it could promote metastasis³¹⁾. As a result, most patients treated with these methods obtained a good prognosis, while those who underwent preoperative surgical procedures such as incisional biopsy or tooth extraction frequently died of distant metastasis³³⁾.

Distant metastasis from cutaneous malignant melanoma occurs frequently. Various combination chemotherapies have been proposed for metastatic melanoma^{1.4.6.12.13)}. Regimens most widely used are; CDDP, DTIC, bischloroethylnitrosourea (BCNU), and tamoxifen (Dartmouth regimen)¹⁸⁾, or CDDP, vinblastine, and DTIC (CVD regimen)²⁰⁾, with- or without immunotherapy using interleukin-2 (IL-2) or interferon (IFN)^{2.3.19)}. However, none of them showed significant difference compared to single agent DTIC in overall survival in a phase III study^{1.7)}.

Atkins *et al.*³⁾ analyzed 270 patients with metastatic melanoma in eight clinical trials of immunotherapy using high dose IL-2. The overall objective response rate was 16%, with 17 complete responses (6%). They stated that response rate with high dose IL-2 immunotherapy was low, but responders showed longer progression-free duration than responders with chemotherapy, and that high dose IL-2 immunotherapy can achieved durable complete remissions in a small percentage of patients with metastatic melanoma. IL-2 therapy, however, causes various side effects which can be fatal, such as hypotension, oliguria, increasing serum creatinine, pulmonary vascular congestion, and generalized edema.

IFN has shown modest activity for metastatic melanoma as a single agent. In several trials the response rate ranged from 6% to 27% (average 10%-15%) with response durations from one to 60+ months¹⁾. IFN therapy also causes various side effects, such as bone marrow suppression, fever, chill, elevated alanine transaminase /aspartate aminotransferase (ALT/AST), depression, and suicidal ideation.

In Japan, the regimens of DAV (DTIC, ACNU, and vincristine) and DAC-tam (DTIC, ACNU, CDDP, and tamoxifen) or combination of these regimens plus IFN or OK432 are used generally as adjuvant therapy following surgery^{16.34)}. Although the patients presented here did not initially undergo adjuvant therapy after surgery because of advanced age, DAV and DAC-tam chemotherapies were given when liver metastasis occurred 7 months later. These chemotherapies showed only a minor response for a short duration, so OK432 was then administrated as a palliative therapy. However, the metastatic melanoma decreased unexpectedly and she remains progression-free at 46 months after the occurrence of liver metastasis.

Furudoi *et al.*¹⁰⁾ reported a case of oral melanoma who showed lung metastasis without loco-regional recurrence at 8 years after the initial therapy (surgery followed by 2 courses of DAV chemotherapy). The patient underwent administration of OK432 (5KE/2 weeks) for 6 years after the initial treatment. They stated that OK432 immunotherapy may suppress the growth of metastatic melanoma of the lung for 6 years postoperatively, but by stopping the use of OK432, metastatic tumor may appear clinically 2 years after that.

MALIGNANT MELANOMA OF THE ORAL CAVITY

A microbial immunostimulant OK432 has been studied intensively and used as an anticancer agent for various malignant tumors over the past 30 years in Japan. Kirkwood et al.¹⁷⁾ reported that patients with melanoma have as significant depression of various cytokine production such as interleukin-1 beta, interferon gamma, and tumor necrosis factor alpha at baseline, and that the depression of these cytokines associated with melanoma may be mitigated by treatment with OK432. Although no controlled study has been conducted as to the effect of OK432 for melanoma patients, this agent has been used for head and neck mucosal melanoma by many clinicians in Japan^{9,15,22,24,25)}. Considering the clinical course of the current case and the slight side effect of OK432, we believe that it is worth administering OK432 for patients with metastatic melanoma when there are no other promising therapies, but further trials are necessary to evaluate the effect of OK432 for this disease.

REFERENCES

1. **Atallah, E., and Flaherty, L.** 2005. Treatment of metastatic malignant melanoma. *Current Treatment Options in Oncology* **6**: 185-193.
2. **Atkins, M.B., Hsu, J., Lee, S., Cohen, G.I., Flaherty, L.E., Sosman, J.A., Sondak, V.K., and Kirkwood, J.M.** 2008. Phase III trial comparing concurrent biochemotherapy with cisplatin, vinblastine, dacarbazine, interleukin-2, and interferon alfa-2b with cisplatin, vinblastine, and dacarbazine alone in patients with metastatic malignant melanoma (E3695): a trial coordinated by the Eastern Cooperative Oncology Group. *J Clin Oncol* **26**: 5748-5754.
3. **Atkins, M.B., Lotze, M.T., Dutcher, J.P., Fisher, R.I., Weiss, G., Margolin, K., Abrams, J., Sznol, M., Parkinson, D., Hawkins, M., Paradise, C., Kunkel, L., and Rosenberg, S.A.** 1999. High-dose recombinant interleukin-2 therapy for patients with metastatic melanoma: analysis of 270 patients treated between 1985 and 1993. *J Clin Oncol* **17**: 2105-2116.
4. **Bajetta, E., Del Vecchio, M., Bernard-Marty, C., Vitali, M., Buzzoni, R., Rixe, O., Nova, P., Aglione, S., Taillibert, S., and Khayat, D.** 2002. Metastatic melanoma: chemotherapy. *Semin Oncol* **29**: 427-445.
5. **Barker, B.F., Carpenter, W.M., Daniels, T.E., Kahn, M.A., Leider, A.S., Lozada-Nur, F., Lynch, D.P., Melrose, R., Merrell, P., Morton, T., Peters, E., Regezi, J.A., Richards, S.D., Rick, G.M., Rohrer, M.D., Slater, L., Stewart, J.C., Tomich, C.E., Vicker, R.A., Wood, N.K., and Young, S.K.** 1997. Oral mucosal melanomas: the WESTOP Banff workshop proceedings. *Western Society of Teachers of Oral Pathology. Oral Surg Oral Med Oral Pathol Oral Radiol Endod* **83**: 672-679.
6. **Bleehen, N.M., Newlands, E.S., Lee, S.M., Thatcher, N., Selby, P., Calvert, A.H., Rustin, G.J., Brampton, M., and Stevens, M.F.** 1995. Cancer research campaign phase II trial of temozolomide in metastatic melanoma. *J Clin Oncol* **130**: 910-913.
7. **Chapman, P.B., Einhorn, L.H., Meyers, M.L., Saxman, S., Destro, A.N., Panageas, K.S., Begg, C.B., Agarwala, S.S., Schuchter, L.M., Ernstoff, M.S., Houghton, A.N., and Kirkwood, J.M.** 1999. Phase III multicenter randomized trial of the Dartmouth regimen versus dacarbazine in patients with metastatic melanoma. *J Clin Oncol* **17**: 2745-2751.
8. **Chiu, N.T., and Weinstock, M.A.** 1996. Melanoma of oronasal mucosa. Population-based analysis of occurrence and mortality. *Arch Otolaryngol Head Neck Surg* **122**: 985-988.
9. **Enomoto, T., Hamada, M., and Enomoto, T.** 1984. Cryosurgery and OK432 in the

- treatment of malignant melanoma. *Acta Otolaryngol* **110**: 127-129.
10. **Furudoi, S., Nakamura, E., Miyamura, A., Kinugasa, M., Umeda, M., and Komori, T.** 2005. A Case of malignant melanoma of upper jaw occurring lung metastasis after 9-year interval. *Jpn Diag/Oral Med* **18**: 303-308.
 11. **Garzino-Demo, P., Fasolis, M., Maggiore, G.M., Pagano, M., and Berrone, S.** 2004. Oral mucosal melanoma: a series of case reports. *J Craniomaxillofac Surg* **32**: 251-257.
 12. **Glover, D., Ibrahim, J., Kirkwood, J., Glick, J., Karp, D., Stewart, J., Ewell, M., and Borden, E.** 2003. Phase II randomized trial of cisplatin and WR-2721 versus cisplatin alone for metastatic melanoma: an Eastern Cooperative Oncology Group Study (E1686). *Melanoma Res* **13**: 619-626.
 13. **Gogas, H., Bafaloukos, D., and Bedikian, A.Y.** 2004. The role of taxanes in the treatment of metastatic melanoma. *Melanoma Res* **14**: 415-420.
 14. **Hicks, M.J., and Flaitz, C.M.** 2000. Oral mucosal melanoma: epidemiology and pathology. *Oral Oncol* **36**: 152-169.
 15. **Hiraishi, Y., Wada, T., Nakatani, K., Tajima, T., Iwagami, Y., and Fujita, S.** 2005. A case of malignant melanoma of the maxillary gingival in which the primary and metastatic lung tumors were controlled. *Jpn J Oral Maxillofac Surg* **51**: 196-199.
 16. **Ishihara, K., Hayasaka, K., and Yamazaki, N.** 1989. Current status of melanoma treatment with interferon, cytokines and other biologic response modifiers in Japan. *J Invest Dermatol* **92**: 326S-328S.
 17. **Kirkwood, J.M., Wilson, J., Whiteside, T.L., Donnelly, S., Herberman, R.B.** 1997. Phase IB trial of picibanil (OK-432) as an immunomodulator in patients with resected high-risk melanoma. *Cancer Immunol Immunother* **44**: 137-149.
 18. **Lattanzi, S.C., Tosteson, T., Chertoff, J., Maurer, L.H., O'Donnell, J., LeMarbre, P.J., Mott, L., DelPrete, S.A., Forcier, R.J., and Ernstoff, M.S.** 1995. Dacarbazine, cisplatin and carmustine, with or without tamoxifen, for metastatic melanoma: 5-year follow-up. *Melanoma Res* **5**:365-369.
 19. **Legha, S.S.** 1997. The role of IFN- α in the treatment of metastatic melanoma. *Semin Oncol* **24**: 24-31.
 20. **Legha, S.S., Ring, S., Papadopoulos, N., Plager, C., Chawla, S., and Benjamin, R.** 1989. A prospective evaluation of a triple-drug regimen containing cisplatin, vinblastine, and dacarbazine (CVD) for metastatic melanoma. *Cancer* **64**: 2024-2029.
 21. **Lopez-Graniel, C.M., Ochoa-Carrillo, F.J., and Meneses-Garcia, A.** 1999. Malignant melanoma of the oral cavity: diagnosis and treatment experience in a Mexican population. *Oral Oncol* **35**: 425-430.
 22. **Nagai, K., Matsumura, Y., Nomura, J., Inui, M., and Tagawa, T.** 2005. A case of double cancer involving oral malignant melanoma and gastrointestinal stromal tumor (GIST). *Int J Oral Maxillofac Surg* **34**: 328-330.
 23. **Nandapalan, V., Roland, N.J., Helliwell, T.R., Williams, E.M., Hamilton, J.W., and Jones, A.S.** 1998. Mucosal melanoma of the head and neck. *Clin Otolaryngol Allied Sci* **23**: 107-116.
 24. **Okita, R., Yamashita, M., Nakata, M., Teramoto, N., Bessho, A., and Mogami, H.** 2005. Multiple ground-glass opacity in metastasis of malignant melanoma diagnosed by lung biopsy. *Ann Thorac Surg* **79**: e1-2.
 25. **Okubo, T., Tanaka, T., Onoma, T., .** 1991. CDDP, DTIC, IFN- β , OK432 併用動注化学免疫療法が奏功した上顎悪性黒色腫の1例. *Biotherapy* **5**: 1495-1498.
 26. **Prasad, M.L., Patel, S., Hoshaw-Woodard, S., Escrig, M., Shah, J.P., Huvos, A.G., and Busam, K.J.** 2002. Prognostic factors for malignant melanoma of the squamous

MALIGNANT MELANOMA OF THE ORAL CAVITY

- mucosa of the head and neck. *Am J Surg Pathol* **26**: 883-892.
27. **Prasad, M.L., Busam, K.J., Patel, S.G., Hoshaw-Woodard, S., Shah, J.P., and Huvos, A.G.** 2003. Clinicopathologic differences in malignant melanoma arising in oral squamous and sinonasal respiratory mucosa of the upper aerodigestive tract. *Arch Pathol Lab Med* **127**: 997-1002.
 28. **Rapidis, A.D., Apostolidis, C., Vilos, G., and Valsamis, S.** 2003. Primary malignant melanoma of the oral mucosa. *J Oral Maxillofac Surg* **61**: 1132-1139.
 29. **Tanaka, N., Mimura, M., Ogi, K., and Amagasa, T.** 2004. Primary malignant melanoma of the oral cavity: assessment of outcome from the clinical records of 35 patients. *Int J Oral Maxillofac Surg* **33**: 761-765.
 30. **Umeda, M., Mishima, Y., Tranobu, O., Nakanishi, K., and Shimada, K.** 1988. Heterogeneity of primary malignant melanomas in oral mucosa: An analysis of 43 cases in Japan. *Pathology* **20**: 234-241.
 31. **Umeda, M., and Shimada, K.** 1994. Primary malignant melanoma of the oral cavity - its histological classification and treatment -. *Br J Oral Maxillofac Surg* **32**: 39-47.
 32. **Umeda, M., Komatsubara, H., Shibuya, Y., Yokoo, S., and Komori, T.** 2002. Premalignant melanocytic dysplasia and malignant melanoma of the oral mucosa. *Oral Oncol* **38**: 714-722.
 33. **Umeda, M., Komatsubara, H., Shigeta, T., Ojima, Y., Minamikawa, T., Shibuya, Y., Yokoo, S., and Komori, T.** 2008. Treatment and prognosis of malignant melanoma of the oral cavity: Preoperative surgical procedure increases risk of distant metastasis. *Oral Surg Oral Med Oral Pathol Oral Radiol Endod* **106**: 51-57.
 34. **Yamazaki, N., Yamamoto, A., Wada, T., Ishikawa, M.** 1999. Dacarbazine, nimustine hydrochloride, cisplatin and tamoxifen combination chemotherapy for advanced malignant melanoma. *J Dermatol* **26**: 489-93.