

Gingival Metastasis from Ovarian Mucinous Cystadenocarcinoma as An Initial Manifestation (A Rare Case Report)

HIROKO SASAKI^{1*}, NORIYUKI OHARA¹, TSUTOMU MINAMIKAWA²,
MASAHIRO UMEDA², TAKAHIDE KOMORI², NOBUE KOJIMA¹,
NAOYA TAKEMURA¹, HIROKI MORITA¹, RYO SUGIHARA³,
EISUKE ENOKI⁴, and TOMOO ITOH⁴

¹Department of Obstetrics and Gynecology, Kobe University Graduate School of Medicine, Kobe, Japan; ²Department of Oral and Maxillofacial Surgery, Kobe University Graduate School of Medicine, Kobe, Japan; ³Department of Radiology, Kobe University Graduate School of Medicine, Kobe, Japan; ⁴Department of Diagnostic Pathology, Kobe University Graduate School of Medicine, Kobe, Japan

Received 16 May 2008/ Accepted 25 June 2008

Key words: Gingival metastasis, Ovarian cancer, Positron emission tomography and computed tomography (PET/CT), magnetic resonance imaging

The metastasis of malignant tumors to the oral cavity remains a rare clinical entity. Most metastatic tumors have the propensity for involving the mandible rather than the oral soft tissues. Herein, we describe an unusual case of ovarian mucinous cystadenocarcinoma that metastasized to the mandibular gingiva as an initial manifestation. There is little information regarding metastatic ovarian cancer to the oral cavity. A patient was a 54-year-old woman who developed the paresthesia and swelling of the right mandible after tooth extraction. A pantomograph revealed an osteolytic lesion in the right mandible. A biopsy taken from the gingiva showed mucinous adenocarcinoma, indicating the gingival metastasis of undiscovered primary cancer. A positron emission tomography and computed tomography using 18F-fluorodeoxyglucose depicted an ovarian tumor with multiple pelvic and paraaortic lymph node swellings. A magnetic resonance imaging (MRI) clearly demonstrated the presence of an ovarian cancer. Based on the imaging studies, the diagnosis of the gingival metastasis of an ovarian cancer was suspected. Serum CEA levels were elevated at 125.6 ng/ml (normal range, 0 - 5 ng/ml). She underwent the right segmental mandiblectomy with functional neck dissection and left salpingo-oophorectomy. The histology of surgical specimen confirmed the gingival metastasis of ovarian mucinous adenocarcinoma. Neoplastic cells in the gingiva infiltrated to the mandibular bone. She has been treated with adjuvant chemotherapy consisting of paclitaxel and carboplatin. This case emphasizes that although rare, metastatic ovarian cancer to the gingiva should be included in the differential diagnosis of tumors in the oral cavity.

Metastatic tumors to the oral region are uncommon with an incidence of about 1% of all oral cancers. Metastatic tumors occur in the oral soft tissues or in the jawbones, particularly the mandible (14, 21), indicating the evidence of a widespread disease. Due to the rarity of this clinical entity, the correct diagnosis of metastatic tumors to the oral cavity remains a challenge (14). Although the primary tumor was already known in most patients before the

GINGIVAL METASTASIS OF OVARIAN CANCER

appearance of the oral metastasis, 24% to a third of oral metastases is the first indication of an undiscovered malignancy at a distal site (14, 21). Histological evaluation of the oral lesion and imaging studies of the whole body is warranted to detect a possible primary malignancy, whenever a metastatic tumor to the oral cavity is suspected. In women, the breast cancer is the most common primary tumor affecting the jawbones and oral soft tissues, followed by carcinomas of the adrenal and female genital organs (14). Several cases of the mandibular metastasis from gynecologic cancers have been reported, including endometrial cancer (8, 12) and cervical cancer (20). However, there is little information regarding the metastatic ovarian cancer to the oral cavity. Herein, we describe an unusual case of ovarian mucinous cystadenocarcinoma metastasizing to the gingiva at an initial clinical manifestation.

CLINICAL CASE

A patient was a 54-year-old woman, gravida 5, para 3, with no medical history of malignancy. She underwent tooth extraction of the right molar due to the pain in the right mandible at the general dentist. Later, she developed paresthesia in the region of the right lower lip and was diagnosed as having an osteomyelitis of the mandible. However, she did not respond to the treatment with antibiotics and subsequently developed the swelling of the right mandible. She was referred to our hospital for further examination. A pantomograph revealed a mass with an osteolytic lesion in the right mandible (Figure 1).

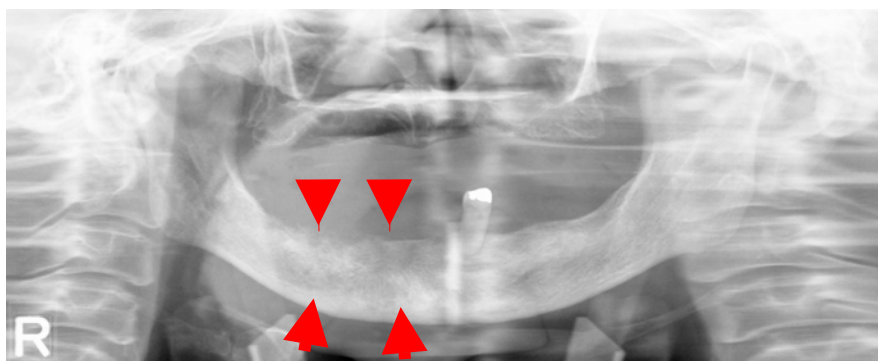


Figure 1. A pantomograph showing an osteolytic area in the right mandible (arrows).

A biopsy of the gingiva in the right mandible was taken, which showed the atypical glands with a cribriform pattern that resembled to an ovarian mucinous adenocarcinoma (Figure 2). The microscopic finding was suggestive of the metastatic ovarian cancer to the mandible, but it was uncertain about the origin of the primary malignancy.

In order to detect a possible primary malignancy, she underwent a positron emission tomography and computed tomography (PET/CT) using 18F-fluorodeoxyglucose (FDG). A PET/contrast-enhanced CT revealed strong FDG accumulation in the right mandible corresponding to the osteolytic area in the right mandible (Figure 3), a pelvic tumor (the maximum standard uptake value (max SUV) = 9.7) (Figure 3), and enlarged pelvic lymph nodes, including common iliac lymph nodes, left external iliac lymph nodes, and paraaortic lymph nodes (Figure 3). No evidence of bone metastasis was noted except the mandibular bone. The pelvic cystic tumor contained solid components at the anterior and caudal parts and mural nodule-like structures on the septa (Figure 4). Bilateral hydronephrosis and

hydroureter were noted. In view of the results of the PET/CT, a presumptive diagnosis of the gingival metastasis of ovarian cancer was made.

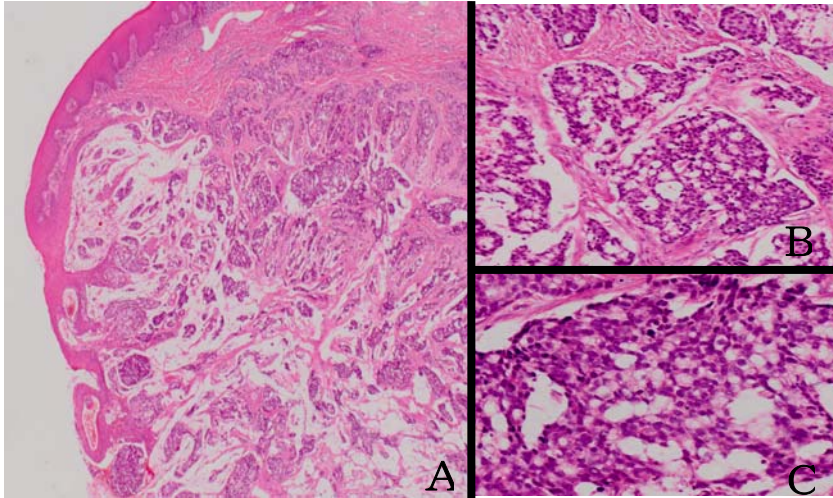


Figure 2. The pathological findings from the biopsy of the gingiva in the right mandible showing H-E stain, original magnification, $\times 10$ (A), $\times 20$ (B), $\times 100$ (C). Biopsied specimen of the mandibular tumor shows atypical glands with a cribriform pattern, which resembles to ovarian mucinous cystadenocarcinoma.

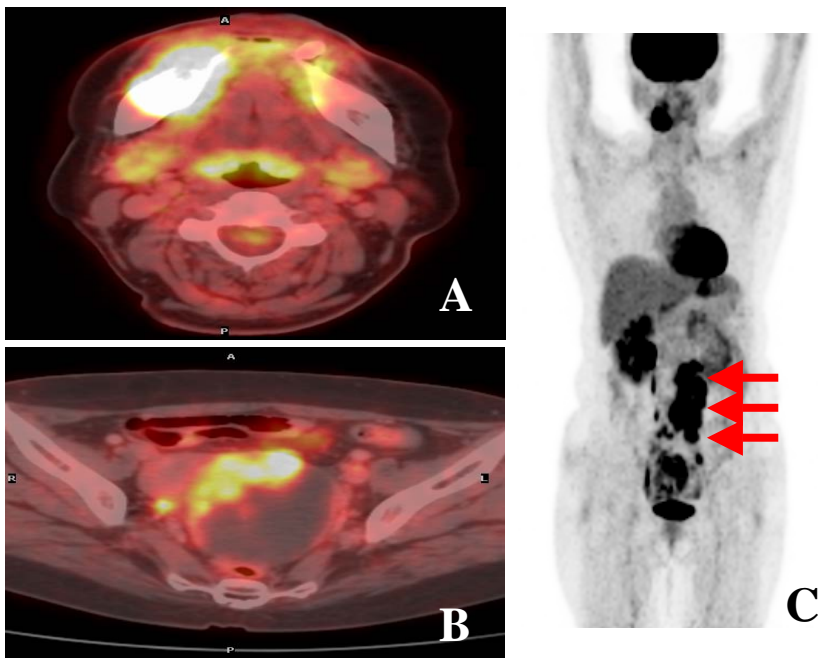


Figure 3. A PET/contrast-enhanced CT showing strong accumulation corresponding to the osteolytic area in the right mandible (A), a PET/contrast-enhanced CT showing strong accumulation (SUVmax = 9.7) corresponding to the enhanced part of the pelvic cystic tumor (B), and a PET image (maximum intensity projection image) showing strong accumulation corresponding to the right mandible, a pelvic tumor, and enlarged pelvic and paraaortic lymph nodes (arrows) (C). PET FDP uptake in tumor is colored in white and yellow.

GINGIVAL METASTASIS OF OVARIAN CANCER

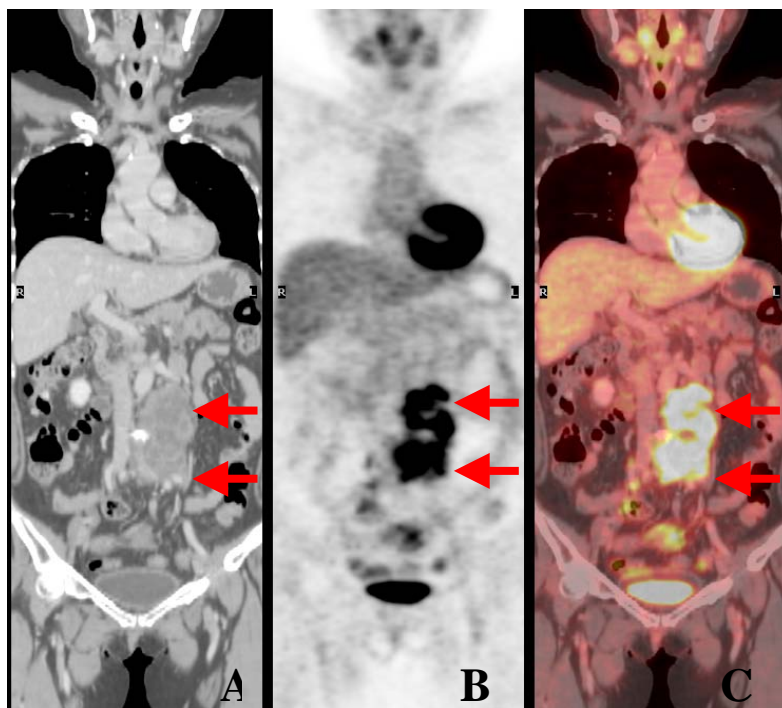


Figure 4. A PET image (reconstructed colonal image) showing strong accumulation corresponding to the enlarged pelvic and paraaortic lymph nodes (A, B, C). PET FDP uptake in tumor is colored in white and yellow.

An urgent referral to the gynecological unit was made for further examination of the pelvic mass. On the pelvic examination, a non-tender fist-sized mass was palpated to the left of the uterus. However, no symptoms referable to a pelvic mass were elicited in the patient. A pelvic ultrasound demonstrated a left solid and cystic adnexal mass measuring 96×65 mm. There was no ascites in the pelvic cavity. A magnetic resonance imaging (MRI) of the pelvis displayed a left ovarian tumor with irregular-shaped septa and hemorrhage on T1-weighted images, and the tumor content showed high to intermediate signal intensity on T2-weighted images (Figure 5A, 5B). The gadopentetate dimeglumine-enhanced T1-weighted images showed the enhancement of the intratumoral septa and solid components in the tumor and left internal and external iliac lymph nodes (Figure 5C).

Serum CEA levels were elevated at 125.6 ng/ml (normal range, 0 - 5 ng/ml), but serum CA125 and CA19-9 levels were normal. The cytology of the cervix and endometrium was normal. The CT of the abdomen and chest showed no remarkable findings. The upper gastrointestinal endoscopy and sigmoidoscopy were normal.

Based on these findings, a provisional diagnosis of stage IV ovarian cancer metastasizing to the gingiva and retroperitoneal lymph nodes was made. The various treatment options were discussed among periodontists and gynecologists, and it was decided not to proceed toward an extensive surgery because her prognosis was thought to be poor. She underwent

the right segmental mandibulectomy with functional neck dissection biopsy and a simultaneous left salpingo-oophorectomy.

Postoperative pathological examination of the mandible revealed that tumors invaded to the maxillary bone from surrounding gingiva and tumors exhibited atypical glands with a cribriform pattern similar to that of an ovarian mucinous adenocarcinoma (Figure 6). Histological section of ovarian tumor demonstrated the infiltrative growth of atypical glands with a cribriform pattern in the mucinous background and tumor cells had round to oval nuclei with mucinous cytoplasm (Figure 7). These findings indicated an ovarian mucinous cystadenocarcinoma of intestinal type. The neoplasm was negative for immunostaining of estrogen and progesterone receptors. The pathological findings confirmed that cancer cells in the gingiva had the similar morphology to that of an ovarian cancer, establishing the diagnosis of the gingival metastasis of ovarian cancer possibly with pelvic, paraaortic, and cervical lymph node metastasis.

Her postoperative course was uneventful. She has been treated with adjuvant chemotherapy consisting of paclitaxel (175 mg/m²) and carboplatin (AUC=3.0).

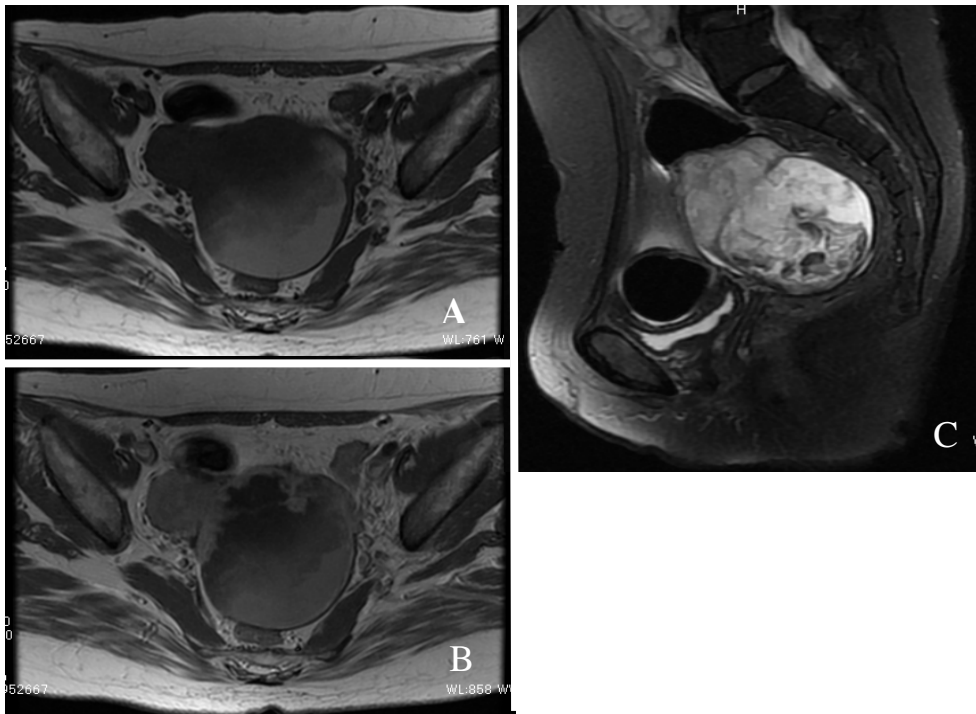


Figure 5. An axial MR image of the pelvis showing a left ovarian tumor in T1-weighted images (A) and in T2-weighted images (B), and the gadopentetate dimeglumine-enhanced T1-weighted images showing the enhancement of the intratumoral septa and solid components in ovarian tumor and pelvic lymph nodes (C).

GINGIVAL METASTASIS OF OVARIAN CANCER

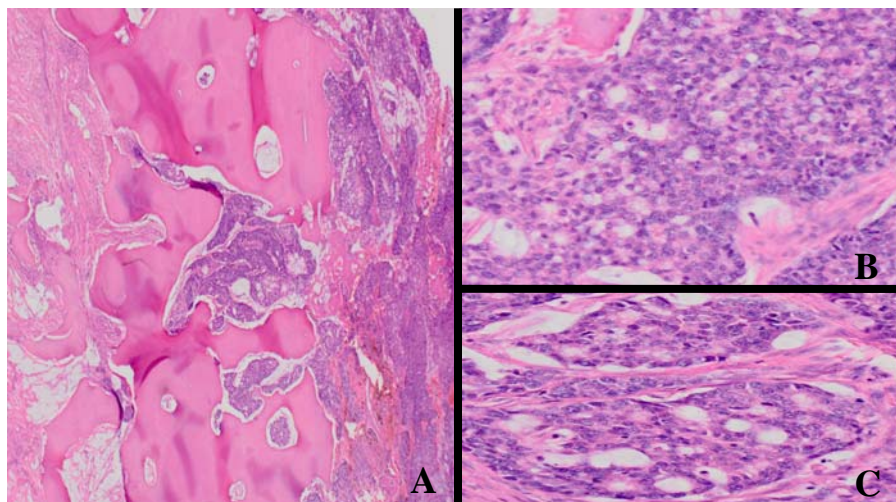


Figure 6. Histology of the mandible showing the infiltration of mucinous adenocarcinoma cells in the gingiva to the mandible, H-E stain, original magnification, $\times 10$ (A), $\times 200$ (B), $\times 200$ (C). Histological sections of the mandible exhibits that neoplastic cells invade to the mandibular bone from the surrounding gingiva. Tumors exhibit atypical glands with a cribriform pattern similar to that of ovarian mucinous cystadenocarcinoma.

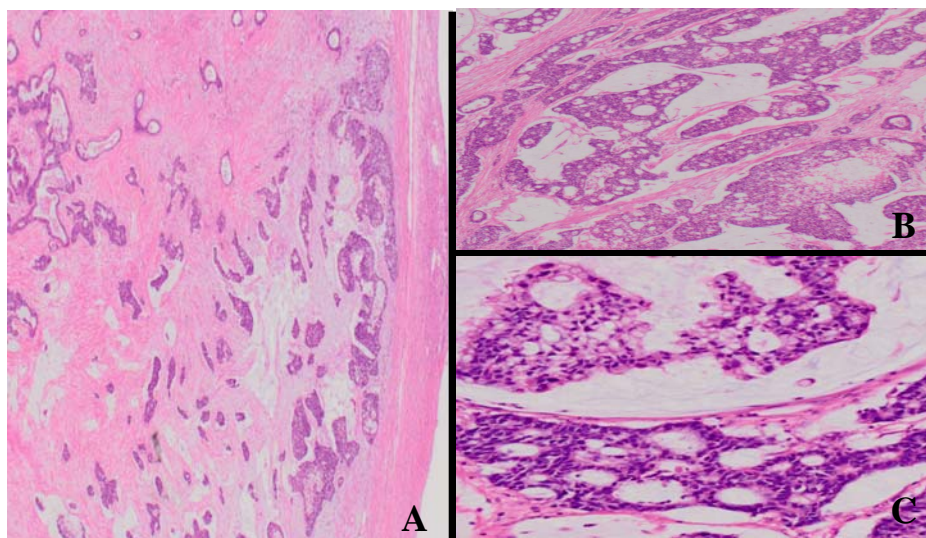


Figure 7. Histology of ovarian mucinous cystadenocarcinoma of intestinal type. H-E stain, original magnification, $\times 10$ (A), $\times 20$ (B), $\times 100$ (C). Histological section of ovarian tumor exhibits infiltrative growth of atypical glands with a cribriform pattern in the mucinous background. Tumor cells have round to oval nuclei with mucinous cytoplasm.

DISCUSSION

We presented an unusual case of ovarian cancer metastasizing to the gingiva as an initial manifestation. The metastatic tumors to the oral cavity remain to be uncommon (14, 21). The jawbones are more frequently affected than the oral soft tissues, and the mandible is the most common location with the molar area being the most frequently involved site (14). In the oral soft tissues, the gingiva is the most common affected site, followed by the tongue (13). The most common primary tumors metastasizing to the oral mucosa in females are breast, followed by female genital organs, kidney, bone, colo-rectum, and skin (14). To our best knowledge, our present case appears to be the first description of the metastatic ovarian cancer to the gingiva.

The clinical presentations of the metastatic lesions include the swelling, pain, ulcer, hemorrhage, trismus, paresthesia, and pathological fracture (14, 17). Paresthesia in the mandibular metastasis is reported to be located in the area innervated by the mandibular alveolar dental nerve (6). Gingival metastases are shown to be polypoid or exophytic, highly vascularized, and hemorrhagic (7). The differential diagnosis includes hemangioma, pyogenic granuloma, giant-cell granuloma, peripheral fibroma, adenoid squamous cell carcinoma, polymorphous low-grade adenocarcinoma that affects the minor salivary glands of the mouth (1, 11). In our case, the gingival lesion was first diagnosed as an inflammatory lesion and treated with tooth extraction and antibiotics, but the patient's symptoms were deteriorated despite the treatment. A subsequent biopsy of the gingiva showed malignant neoplasm. Thus, the diagnosis of the metastatic gingival tumor remains a difficult challenge, indicating that histological evaluation of the affected lesion is necessary for a definite diagnosis. Several authors also emphasize the importance of thorough evaluation of the gingival mass because of the close resemblance of the metastatic gingival tumor to an inflammatory lesion (2, 10, 16, 22).

Radiographic examination of the metastatic lesions often displays a radiolucent osteolytic lesion with ill-defined margin, while metastatic prostate carcinoma gives osteoblastic appearance, and metastatic breast or renal carcinoma may be osteolytic, osteoblastic, or mixed (9). In the present case, the osteolysis of the mandible was thought to be caused secondarily by the invasion of gingival metastatic lesion based on the postoperative histological findings.

Ovarian cancer still remains the leading cause of death in women worldwide. Because ovarian cancer tends to grow silently, this disorder is often diagnosed at an advanced stage. Indeed, in the case presented here, no symptoms associated with ovarian cancer developed. The gingival metastasis and subsequent infiltration to the mandibular bone was the initial clinical manifestation in this patient. However, a PET/CT was useful to detect the primary and metastatic lesions. A FDG-PET/CT was shown to increase the diagnostic accuracy of pre-treatment staging of ovarian cancer patients in comparison with contrast enhanced CT (4). Recent two articles have reported that the use of FDG PET and PET/CT helped to establish the diagnosis of mandibular metastasis from hepatocellular carcinoma (15, 18). Furthermore, an MRI could clearly demonstrate the presence of ovarian cancer and multiple lymph node metastases in our case.

In the present case, cancer cells were present both in the gingiva and mandibular bone. The meticulous pathological examination was done to clarify the route of the direct oral metastasis. From the pathological viewpoint, it was determined that ovarian cancer first metastasized to the gingiva, and then cancer cells invaded to the mandibular bone because neoplastic cells were found to surround the mandibular bone and infiltrated to it. This strongly indicates that ovarian cancer cells develop a direct gingival metastasis in the present

GINGIVAL METASTASIS OF OVARIAN CANCER

case with the subsequent metastasis to the mandible. In our case, it was noteworthy that no evidence of bone metastasis was detected with a PET/CT. In fact, bone metastasis from ovarian cancer has been reported to be rare (5, 19).

In most cases of the oral metastasis, the prognosis is shown to be grave with an average survival period of about seven months (14). The treatment regimen included local resection, palliative radiotherapy, chemotherapy, or supportive care only to improve the quality of life (3, 14). The prognosis of this case was also thought to be worse due to stage IV ovarian cancer with multiple metastases to the pelvic and paraaortic lymph nodes in addition to the oral cavity. Since curative treatment was difficult to perform due to her advanced stage of the disease, a segmental mandiblectomy with salpingo-oophorectomy was carried out as the reduction surgery. Ovarian mucinous cystadenocarcinoma is known to be relatively responsive to chemotherapy, and the patient has been receiving adjuvant chemotherapy consisting of paclitaxel and carboplatin with maintaining a relatively good performance status.

In this article, we presented an unusual presentation of an ovarian cancer that developed the gingival metastasis extending to the mandibular bone at an initial manifestation. This case emphasizes that although rare, metastatic ovarian cancer to the oral cavity should be included in the differential diagnosis of the metastatic tumors in the oral cavity.

REFERENCES

1. **Álvarez-Álvarez C, Iglesias-Rodríguez B, Pazo-Iraza S, and Delgado-Sánchez-Gracián C.** 2006. Colon adenocarcinoma with metastasis to the gingiva. *Oral Patol Oral Cir Bucal* **11**: E85-E87.
2. **Bernabé DG, Veronese LA, Miyahara GI, Conrado-Neto S, and Biasoli ER.** 2008. Gingival metastasis from salivary duct carcinoma of the parotid gland. *J Periodontol* **79**: 748-752.
3. **Bodner L, Sion-Vardy N, Geffen DB, and Nash M.** 2006. Metastatic tumors to the jaws: a report of eight new cases. *Med Oral Patol Oral Cir Bucal* **11**: E132-E135.
4. **Castellucci P, Perrone AM, Picchio M, Ghi T, Farsad M, Nanni C, Messa C, Meriggiola MC, Pelusi G, Al-Nahhas A, Rubello D, Fazio F, and Fanti S.** 2007. Diagnostic accuracy of ¹⁸F-FDG PET/CT in characterizing ovarian lesions and staging ovarian cancer: correlation with transvaginal ultrasonography, computed tomography, and histology. *Nucl Med Commun* **28**: 589-595.
5. **Chang KH, Lee JP, and Ryu HS.** 2006. Rare case of stage IA epithelial ovarian cancer with bone as the first site of recurrent metastasis. *Int J Gynecol Cancer* **16** (Suppl. 1): 322-326.
6. **Court DR, Encina S, and Levy I.** 2007. Prostatic adenocarcinoma with mandibular metastatic lesion: case report. *Med Oral Pathol Oral Cir Bucal* **12**: E424-E427.
7. **Curien R, Moizan H, and Gerard E.** 2007. Gingival metastasis of a bronchogenic adenocarcinoma: report of a case. *Oral Surg Oral Med Oral Pathol Oral Radiol Endod* **104**: e25-e28.
8. **Dosoretz DE, Orr Jr JW, Salenius SA, and Orr PF.** 1999. Mandibular metastasis in a patient with endometrial cancer. *Gynecol Oncol* **72**: 243-245.
9. **D'Silva NJ, Summerlin DJ, Cordell KG, Abdelsayed RA, Tomich CE, Hanks CT, Fear D, and Meyrowitz S.** 2006. Metastatic tumors in the jaws. a retrospective study of 114 cases. *JADA* **137**: 1667-1672.

10. **Elkhoury J, Cacchillo DA, Tatakis DN, Kalmar JR, Allen CM, and Sedghizadeh PP.** 2004. Undifferentiated malignant neoplasm involving the interdental gingiva: a case report. *J Periodontol* **75**: 1295-1299.
11. **Ellis GL, Jensen JL, Reingold IM, and Barr RJ.** 1977. Malignant neoplasms metastatic to gingivae. *Oral Surg Oral Med Oral Pathol* **44**: 238-245.
12. **Gallen DM.** 1998. Mandibular metastasis of endometrial carcinoma diagnosed via a dental radiograph. *JADA* **129**: 1595-1598.
13. **Hirshberg A, and Buchner A.** 1995. Metastatic tumours to the oral region. an overview. *Eur J Cancer B Oral Oncol* **31B**: 355-360.
14. **Hirshberg A, Shnaiderman-Shapiro A, Kaplan I, and Berger R.** 2008. Metastatic tumours to the oral cavity – pathogenesis and analysis of 673 cases. *Oral Oncol* **44**:743-752.
15. **Kamatani T, Tatemoto Y, Tateishi Y, and Yamamoto T.** Isolated metastasis from hepatocellular carcinoma to the mandibular condyle with no evidence of any other metastases: a case report. *Br J Oral Maxillofac Surg* in press.
16. **Pozzi EC, Altermatt HJ, Rees TD, and Bornstein MM.** 2008. Exophytic mass of the gingiva as the first manifestation of metastatic pulmonary adenocarcinoma. *J Periodontol* **79**: 187-191.
17. **Sánchez-Jiménez J, Acebal-Blanco F, Arévalo-Arévalo RE, and Molina-Martínez M.** 2005. Metastatic tumours in upper maxillary bone of esophageal adenocarcinoma. a case report. *Med Oral Patol Oral Cir Bucal* **10**: 252-257.
18. **Teshigawara K, Kakuzaki S, Sohara N, Hashida T, Tomizawa Y, Sato K, Takagi H, Mori M, Hoshino K, and Mogi K.** 2006. Solitary mandibular metastasis as an initial manifestation of hepatocellular carcinoma. *Acta Med Okayama* **60**: 243-247.
19. **Tiwari A, Kumar N, Bajpai R, and Lal P.** 2007. Bone metastasis from ovarian cancer. *J Cancer Res Ther* **3**: 34-36.
20. **Uhler IV, Fahs GR, and Dolan LA.** 1972. Metastasis of cervical carcinoma to the mandible: report of case. *J Am Dent Assoc* **85**: 363-364.
21. **van der Waal RIF, Buter J, and van der Waal I.** 2003. Oral metastases: report of 24 cases. *Br J Oral Maxillofac Surg* **41**: 3-6.
22. **Yoshii T, Muraoka S, Sano N, Furudoi S, and Komori T.** 2002. Large cell carcinoma of the lung metastatic to the mandibular gingiva. *J Periodontol* **73**: 571-574.