

## Two Cases of Masticator Space Abscess Initially Diagnosed as Temporomandibular Joint Disorder

TAKUMI HASEGAWA\*, YASUYUKI SHIBUYA,  
SHINSUKE KUROKI, JUNICHIRO TAKEUCHI, SATOSHI YOKOO,  
MASAHIRO UMEDA, and TAKAHIDE KOMORI

*Department of Oral and Maxillofacial Surgery,  
Kobe University Graduate School of Medicine*

Received 28 March 2008/ Accepted 15 May 2008

**Key words:** masticator space, abscess, temporomandibular joint

Diseases causing trismus or pain of the temporomandibular joint (TMJ) include temporomandibular joint disorders (TMJD), trauma, tumors and an inflammation. This report describes two cases of masticator space abscesses causing trismus and TMJ pain, which were initially diagnosed as TMJD. The first case was a 62-year-old female suffering from trismus and right-TMJ pain without swelling or redness, which was diagnosed as TMJD with MRI (TMJ region) findings of bilateral anterior disc displacement without reduction. However, five days later the right-TMJ pain became more severe and MRI (maxillofacial region) revealed a right masticator space abscess. She was treated with antibiotics and underwent an intraoral incision following hospitalization. She recovered well and was discharged from the hospital on the 15th day. The second case was a 68-year-old female having trismus and left-TMJ pain, which was diagnosed as TMJD at another hospital. She received instructions for jaw opening training, but visited our hospital because her symptoms were not improved. At the first visit, the mouth opening range was 18 mm and an anterior dislocation of the left condylar process was found by X-ray imaging. CT-scan revealed an abscess in the left masticator space. Therefore an intraoral incision was performed under general anesthesia and antibiotics were administered. She recovered well and was discharged from hospital on the 12th day.

When we treat TMJD, we must keep in mind the possibility of inapparent of the presence of some unseen inflammation, especially an abscess formation in the masticator space.

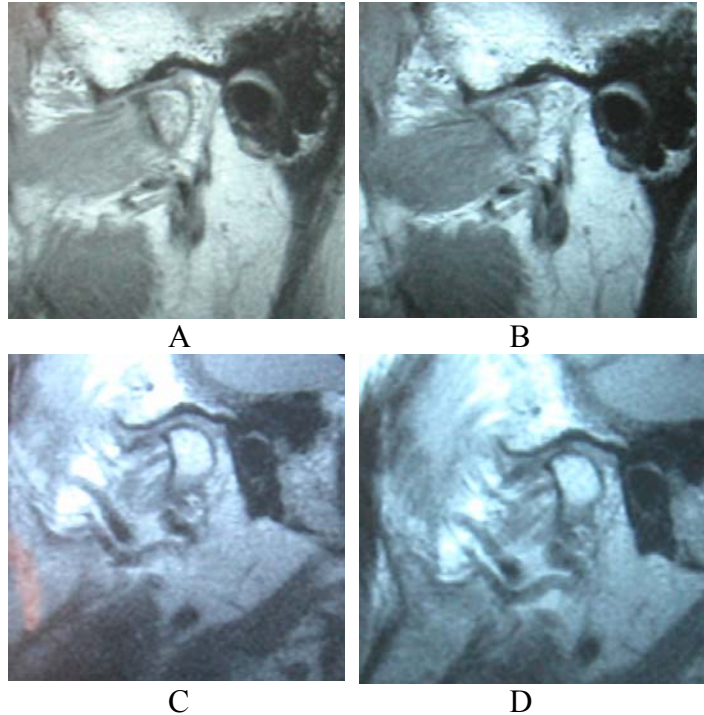
Pyogenic orofacial infections usually originate in an odontogenic location (3). The majority of these odontogenic infections are confined to local lesions, while in some cases they spread from the affected tooth along the anatomic spaces and occasionally advance to a site far from the initial infection. Significant morbidity or even death may occur in the cases that advance into the retropharyngeal, mediastinal, intracranial or intraorbital spaces (8). On the other hand, trismus or pain of the temporomandibular joint (TMJ) is typical symptom of a temporomandibular joint disorder (TMJD). However, in a few cases, a masticator space abscess resulting from an odontogenic infection also shows trismus or pain in the TMJ, which leads misdiagnosis as a TMJD. This paper reports two cases of masticator space abscess causing trismus and TMJ pain, which were initially diagnosed to be a TMJD.

## CLINICAL CASES

### CASE 1

The first case was a 62-year-old female. Her past medical history included coxarthrosis. She was treated with extraction of upper second molar because of severe periodontitis by another hospital, whereas she didn't recover well after a week and was referred to our hospital.

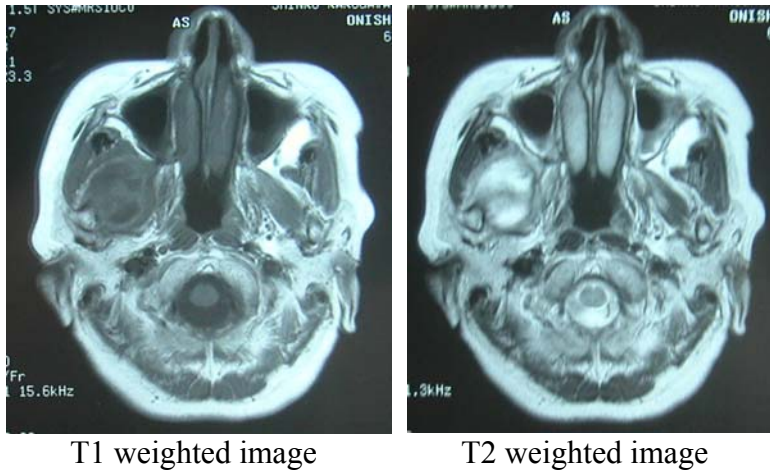
At the first visit, she was suffering from trismus and right-TMJ pain without swelling or redness in the buccal region. Her mouth-opening range between the upper and lower incisor was 24 mm. She was diagnosed as TMJD by MRI on TMJ slices which revealed bilateral anterior disc displacement without reduction (Fig.1). However, five days later the right-TMJ pain became more severe and she underwent a re-examination by MRI on maxillofacial slices. An axial T1 weighted spin echo image at the level of the mandible revealed a low signal mass including the right masticator space, and an axial T2 weighted spin echo image revealed a high signal mass (Fig.2). These findings indicated a right masticator space abscess. The patient was feverless but her white blood cell (WBC) count was 14.0/nl and her C reactive protein (CRP) was 7.9 mg/dl. She was treated with antibiotics (CPR 2g/day, CLDM 1200mg/day) and hospitalized. An intraoral incision was performed. At surgery a large amount of pus was drained, after which, her WBC count and CRP decreased. Administration of CLDM was completed on the 8th day and CPR on the 13th day. □-Streptococcus was detected by a bacteriological examination. She recovered well and was discharged from hospital on the 15th day. At 4 weeks after surgery, MRI revealed improvement of the right masticator space abscess (Fig.3), and another 4 weeks were required before her mouth-opening range reached 32mm without right-TMJ pain.



**Fig. 1.** MRI (TMJ slice of proton density-weighted image) in case 1  
MRI reveals bilateral anterior disc displacement without reduction.

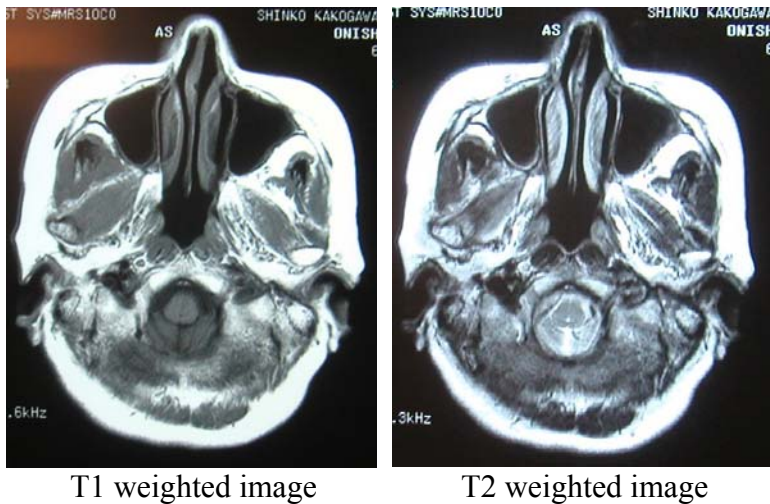
## TWO CASES OF A MASTICATOR SPACE ABSCESS

(A): right-TMJ (closed position), (B): right-TMJ (opened position),  
(C): left-TMJ (closed position), (D): left-TMJ (opened position)



**Fig. 2.** MRI (maxillofacial slice) in case 1

MRI reveals a right masticator space abscess. An axial T1 weighted spin echo image at the level of mandible reveals a low signal mass including the right masticator space. An axial T2 weighted spin echo image reveals a high signal mass.

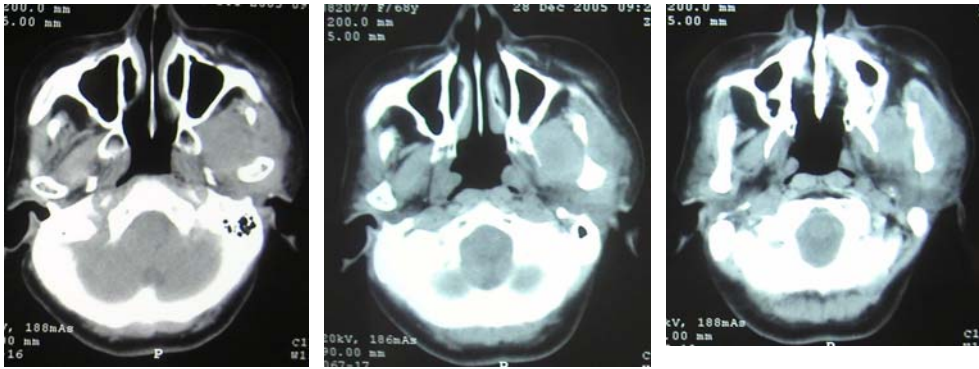


**Fig. 3.** MRI findings of postoperation in case 1

MRI reveals only change of postinflammation and no right masticator space abscess.

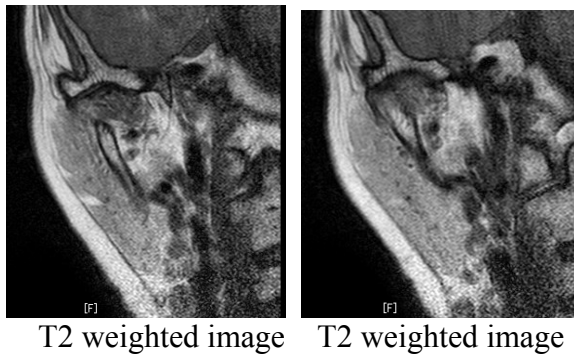
**CASE 2**

The second case was a 68-year-old woman with trismus and left-TMJ pain, which was diagnosed to be TMJD at another hospital. She received instructions in jaw opening training, but sought further treatment because her symptoms were not improved. Her past medical history included only hyperlipidemia. At the first visit, she had Class IV caries at lower left second premolar and pericoronitis at lower left wisdom tooth, with 18 mm of the mouth-opening range, while she was afebrile. X-ray photography revealed an anterior dislocation of the left condylar process and CT-scan demonstrated an abscess in the left masticator space (Fig. 4). Her WBC count was 10.9/nl and her CRP was 17.5 mg/dl. Accordingly, she was treated with antibiotics administration (BIPM 0.9g/day, CLDM 1200mg/day) and hospitalized. An intraoral incision and extraction of the lower left second premolar and lower left wisdom tooth were performed under general anesthesia. During surgery a large amount of pus was drained from the abscess, and her WBC count and CRP decreased. The administration of BIPM and CLDM was stopped on the 5th day. She recovered well and was discharged from hospital on the 12th day. At 4 weeks after surgery, MRI revealed improvement of the left masticator space abscess (Fig. 5), while another 20 weeks were needed until her mouth-opening range reached 41mm without any left-TMJ pain.



**Fig. 4.** CT findings in case 2

CT-scan reveals a left masticator space abscess with a low density mass.



**Fig. 5.** MRI findings of postoperation in case 2

MRI reveals only change of postinflammation and no left masticator space abscess.

## TWO CASES OF A MASTICATOR SPACE ABSCESS

### DISCUSSION

Abscess formation in the orofacial region is relatively rare but it usually develops from an odontogenic location (3, 8). Odontogenic infections are commonly caused by pericoronitis, dental caries, periodontitis, or complications from dental procedures. The second and third molars are often the etiological tooth for these odontogenic infections (1). A decayed tooth with an exposed pulp causes pulpitis, which, if untreated, develops into periodontitis. Pericoronitis or periodontitis can progress to alveolar osteitis or maxillare osteitis, which causes abscess formation in the orofacial region (7).

The masticator space is a distinct deep facial space, bounded by the superficial layer of the deep cervical fascia. It contains the ramus and posterior body of the mandible, and the four muscles of mastication, including the medial, lateral pterygoid muscle, temporal muscle and masseter muscle. This space is distinguished from other spaces by the superficial layer of deep cervical fascia. The space also contains several important nerves. These nerves, all branches of the mandibular division of the trigeminal nerve, include the masticator nerve, which innervates the muscles of mastication, as well as the buccal, lingual, and inferior alveolar nerves. Some clinical reports refer to the masticator space as temporal fossa and infratemporal fossa (2). Masticator space is clinically important as a potential route of tumor progression and inflammation (6). It is commonly known that the contracture of medial and lateral pterygoid muscle in response to inflammation causes trismus and pain of TMJ. Muscle contracture or abscess formation in the masticator space tends to be recognized as a tumorous lesion by MRI views, however it is easy to discriminate between those diseases by CT imaging and the large amount of pus discharge observed during surgery.

An abscess within the maxillo-mandibular bone must perforate jawbone itself before expanding to the surrounding soft tissues (5). The least resistant, weakest and thinnest portion of the mandible is the lingual side of the molar region and the labial side of the anterior region. In the maxilla, the bone is the weakest on the labial or buccal side. An abscess, which perforates the buccal or labial plate of either the mandible or maxilla, will advance intraorally if it is disturbed by the bone attachments of the buccinator muscle, and extraorally if it perforates those muscular attachments. When a mandibular abscess perforates the lingual side of the molar region, it advances into the sublingual or submandibular spaces. A masticator abscess is usually caused by the advancement of a submandibular abscess. Normal flora in the oral cavity with low pathogenic potential can readily proliferate and cause abscess formation under immunosuppressive or ischemic or hypoxic conditions (4). Bacterial products such as endotoxins, collagenase, fibrinolysin, elastase or hyaluronidase facilitate the inflammation (4).

Antibiotic therapy is important for preventing both local infective spread and bacteremia (1). The initial treatment for odontogenic disease is either an extraction or a root canal treatment of the affected tooth. If an advanced abscess is observed, the surgical drainage and debridement of necrotic tissue must be performed immediately. Before the surgical treatment, information concerning the anatomical spaces relating to the abscess formation is useful. Both CT and MRI provide reliable information regarding whether surgery is indicated or not, and which surgical approach is appropriate. These images are useful when the abscess is localized within the deep anatomical spaces such as the masticator space. An incision to the premature abscess disrupts the normal physiologic barriers and can cause further extension of the infection (5), whereas spontaneous abscess rupture through the skin damages the subcutaneous tissues and causes hypertrophic scars (5). In the cases of an abscess in the vestibular, buccal, pterygomandibular and canine space abscess, an intraoral incision at the appropriate time can prevent cutaneous scar formation. A submental or submandibular

abscess requires an extraoral incision and drainage. The masticator space can be approached either intraorally or extraorally. The parapharyngeal space should therefore be approached extraorally to avoid any injury to the great vessels (6). In the present cases, the abscess was incised intraorally and a large amount of pus was drained from the abscess without any complications.

Case 1 had a TMJD due to a previous illness and thus developed a masticator abscess as a result of a tooth extraction, which confused the clinical findings and the diagnoses. The present cases could have been diagnosed by the high WBC count and CRP in blood analysis. In the cases of a deep masticator space abscess, the facial swelling or ferverescence tends to be minor (1). However, a blood analysis is not always performed at the first visit in the cases of trismus with spontaneous pain of the TMJ. Consequently, when we treat TMJD, we must keep in mind the possibility of inapparent of the presence of some unseen inflammation, especially an abscess formation in the masticator space.

#### REFERENCE

1. **Bratton TA, Jackson DC, Nkungula-Howlett T, et al.** 2002, Management of complex multi-space odontogenic infections. *J Tenn Dent Assoc*; **82**(3): 39-47.
2. **Chong VF, Fan YF.** 1996, Pictorial review: radiology of the masticator space. *Clin Radiol*; **51**(7): 457-65.
3. **Chow AW, Roser SM, Brady FA.** 1978, Orofacial odontogenic infections. *Ann Intern Med*; **88**(3): 392-402
4. **Duran-Reynals F.** 1942, TISSUE PERMEABILITY AND THE SPREADING FACTORS IN INFECTION: A Contribution to the Host:Parasite Problem. *Bacteriol Rev*; **6**(4): 197-252.
5. **Endicott JN, Nelson RJ, Saraceno CA.** 1982, Diagnosis and management decisions in infections of the deep fascial spaces of the head and neck utilizing computerized tomography. *Laryngoscope*; **92**(6 Pt 1): 630-3.
6. **Hardin CW, Harnsberger HR, Osborn AG, et al.** 1985, Infection and tumor of the masticator space: CT evaluation. *Radiology*; **157**(2): 413-417.
7. **Spilka CJ.** 1966, Pathways of dental infections. *J Oral Surg*; **24**(2): 111-24
8. **Welsh LW, Welsh JJ, Kelly JJ.** 1991, Massive orofacial abscesses of dental origin. *Ann Otol Rhinol Laryngol*; **100**(9 Pt 1): 768-773.