

A Case of Spontaneous Pneumothorax During Pregnancy and Review of the Literature

YASUHITO TANASE¹, TAKASHI YAMADA², YOKO KAWARYU³,
MASAYO YOSHIDA³, and SEIGO KAWAI³

¹*Department of Gynecology, Osaka Central Hospital, Osaka 530-0001,*

²*Pathology, Osaka Medical College, Osaka 569-8580, Japan,*

³*Obstetrics and Gynecology, Hoshigaoka Koseinenkin Hospital, Osaka 573-8511, Japan*

Received 27 October 2007 / Accepted 5 March 2007

Key words: pregnancy, spontaneous pneumothorax, thoracostomy, thoracotomy

Spontaneous pneumothorax is rare during pregnancy. A case of spontaneous pneumothorax occurring at 34 weeks' gestation in a healthy 25-year-old primigravida is described. Its occurrence was accompanied by sudden onset of dyspnea and pleuritic chest pain while the patient was walking. Diagnosis was made by chest radiograph and treatment was by tube thoracostomy. At 41 weeks' gestation, after normal labor progression, she successfully gave birth to a male infant with a birth weight of 2,744 g. We discuss spontaneous pneumothorax during pregnancy and review the literature.

Spontaneous pneumothorax is the sudden collapse of a bulla or bleb, and its occurrence during pregnancy is rare. Diagnosis, treatment, and the mode of delivery of the infant all present possible problems related to this event. We describe here a case of pneumothorax during pregnancy with a good outcome for both mother and infant and a review of the literature.

CLINICAL CASE

A 25-year-old primigravida at 34 weeks' gestation presented at our hospital by ambulance with the sudden onset of right-sided pleuritic chest pain and moderate dyspnea that occurred while she was walking. At that time she felt as if her ribs were fractured. There was no history of fever, chills, trauma, nausea, or vomiting. Her medical history was unremarkable. She was a nonsmoker and had no family history of pulmonary disease.

On admission, she was in the left lateral position and was not able to assume a supine position because of chest pain and moderate dyspnea. Physical examination revealed a well-nourished woman (height 163 cm, weight 51 kg). Blood pressure was 103/48 mm Hg, heart rate 105 beats per minute, respiratory rate 14 breaths per minute, and temperature was 37.5°C. Chest examination was notable for decreased breath sounds. Chest radiograph of the left decubital view with the abdomen shielded showed an almost complete pneumothorax of the right lung (Fig. 1). Peripheral pulse oximetry indicated normal oxygen saturation with room air. Abdominal examination revealed a normal-sized intrauterine pregnancy with vertex presentation and fetal heart tones of 140 beats per minute. The cervical os was not dilated.

A chest tube was placed because of the continued dyspnea and was connected to a closed suction device for 13 days. The patient gradually improved and repeated chest radiograph

revealed almost complete re-expansion of the right lung. Clinical improvement became evident in 16 days. As the clinical condition had stabilized, she was discharged from hospital on hospital day 19.

About 34 days after discharge, at 41 weeks' gestation, there was spontaneous onset of labor. After normal labor progression, the patient gave birth to a normal male infant with a birth weight of 2,744 g and Apgar scores of 9 at both 1 and 5 minutes. The patient's postpartum course was uneventful. Computed tomography (CT) scan of the chest on puerperal day 3 showed a few bullae at the apex of the bilateral lung, but the right lung remained expanded (Fig. 2). No surgery was performed and she has had no symptoms during the 16 months since delivery.

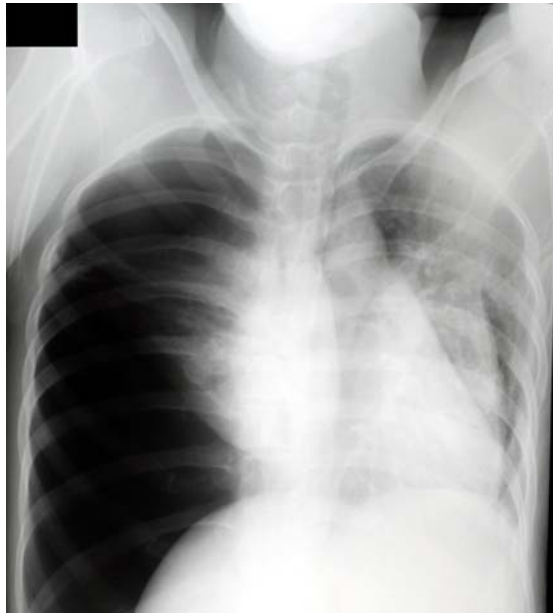

Figure 1. Chest radiograph image shows an almost complete pneumothorax in the right lung.

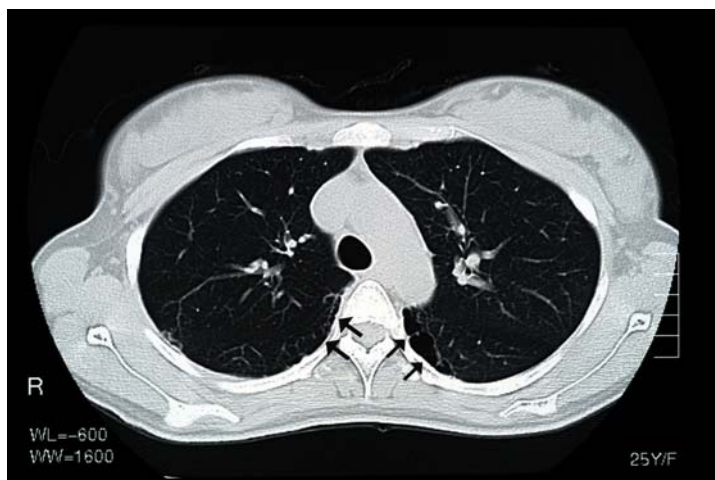


Figure 2. Computerized tomography image of the chest taken after delivery shows some bulla in the bilateral apex.

PNEUMOTHORAX DURING PREGNANCY

DISCUSSION

Acute pneumothorax during pregnancy is potentially serious for both the patient and fetus. But spontaneous pneumothorax in general rarely occurs in women compared with men. Furthermore, it is said that non-malignancy-related spontaneous pneumothorax in pregnancy is rare. In the English literature to date, only 44 cases have been described (3, 4, 5, 8). However, the true incidence of this condition is unknown and this number is almost certainly an underestimation (8).

The most common cause of spontaneous pneumothorax in pregnancy is rupture of a subpleural apical bulla or bleb in a patient with otherwise healthy lungs (7). Pulmonary lymphangiomatosis was also reported as another cause for pneumothorax during pregnancy (6, 11).

The typical symptoms of spontaneous pneumothorax, regardless of cause, include pleuritic chest pain associated with dyspnea (2, 9). Physical examination may show tachypnea, tachycardia, cyanosis, or ipsilateral decreased breath sounds.

Chest radiographs are required for definitive diagnosis. Ionizing radiation represents a potential risk to the fetus, particularly during the first 8 weeks of development, that is, the period of organogenesis. The potential hazards associated with a radiologic examination must be weighed against the possible benefits of study results. When one suspects pneumothorax in a pregnant patient, it is safe to proceed with the standard chest radiography without placing the fetus at substantial risk from ionizing radiation if the abdomen is shielded. Shielded CT is also a useful imaging technique that can help in defining the underlying anatomic abnormality and in planning an operative approach when surgical treatment is indicated (5).

Review of 45 cases (including this case) shows that the patients were young (average age 26.7 ± 2.3 years) and of low gravidity (mean gravidity 1.7). Risk factors for spontaneous pneumothorax were an underlying infection, asthma, history of pneumothorax, and cocaine use (1, 2). Pneumothorax occurred during the perinatal period in 53.3% (24/45) and during the first or second trimester in 46.7% (21/45) of cases. Initial treatment was observation only in 22.7% (10/44), tube thoracostomy in 75.0% (33/44), and thoracotomy in 2.3% (1/44). Of those treated by observation only, 80.0% (8/10) had resolution compared with 37.5% (12/32) of those treated by tube thoracostomy. Of the entire group, 37.2% (16/43) ultimately required thoracotomy for recurrence or persistence of the initial alveolar leak. The obstetric outcome was good; 86.0% (37/43) had vaginal delivery and 14.0% (6/43) elective cesarean delivery. No neonatal complications were reported.

Treatment of pneumothorax during pregnancy is controversial. The use of prolonged intercostal drainage was considered as a temporizing measure for spontaneous pneumothorax in late pregnancy to be safe and effective (7). However, any ventilatory problems associated with pneumothorax may not be well tolerated by a pregnant patient and her fetus (10). Generally, the same treatment criteria used for nonpregnant patients apply to pregnant patients. Admission and close observation of the patient is usually done with small pneumothoraces. Other treatment options are needle aspiration, needle decompression, pleurodesis, tube thoracostomy, thoracotomy, and thoracoscopy for recurrent, persistent, or bilateral pneumothorax (5). The traditional treatment approach to recurrent pneumothorax has been thoracotomy with bleb or bulla resection and pleurodesis. Recently, use of thoracoscopy has increased because the same procedures can be done through the thoracoscope as with complete thoracotomy. The advantages of thoracoscopic surgical treatment over thoracotomy are decreased time of exposure to anesthetic drugs, rapid lung

expansion, decreased postoperative pain, a potentially more brief postoperative period, and avoidance of a painful thoracotomy (10).

Allowing spontaneous vaginal delivery after operative treatment of pneumothorax during pregnancy also seems safe. For patients who have not received definitive surgical therapy, epidural anesthesia and forceps assistance are recommended to prevent increased intrathoracic pressure due to the expulsive efforts during the second stage of labor and possible worsening or recurrence of pneumothorax (7, 9). Based on the previous reports and the current case, there is no indication for cesarean section specifically related to spontaneous pneumothorax. We should select the mode of delivery only for obstetric indications. So in this case we selected transvaginal delivery as a mode of delivery.

In the present case, pneumothorax did not represent a serious risk to either mother or fetus, as the only treatment was tube thoracostomy.

As differential diagnosis in case of young woman's pneumothorax we should keep pulmonary lymphangioliomyomatosis (LAM) in mind. LAM occurs in young woman of pregnant ages and often causes pneumothorax. In this case the CT of the chest showed only a few bullae at the apex of the lung, but in LAM we could see multiple round cysts at almost all fields of the bilateral lung. At the point of this, we diagnosed her as pulmonary pneumothorax. But actually the diagnosis should be done by biopsy of the cysts if LAM is suspected.

Recently, in Japan, pulmonary embolism related to pregnancy and surgery has been increasing, and has been considered a serious complication in pregnancy. Pneumothorax should be considered in any pregnant woman with chest pain and/or dyspnea and must be confirmed radiographically to distinguish it from other diseases or conditions. Neither the condition nor its treatment seems to cause serious adverse effects on the course of pregnancy or delivery, but suspicion of the presence of pneumothorax under certain conditions is essential for prompt recognition of pneumothorax during pregnancy to prevent complications.

REFERENCES

1. **Bernasko J. W., Brown G., Mitchell J. L., Matseoane S. L.** 1997. Spontaneous pneumothorax following cocaine use in pregnancy. *Am J Emerg Med.* **15**: 107.
2. **Chan L., Pham H., Reece E. A.** 1997. Pneumothorax in pregnancy associated with cocaine use. *Am J Perinatol.* **14**: 385-388.
3. **Cooley S., Geary M., Keane D. P.** 2002. Spontaneous pneumothorax and febrile neutropenia in pregnancy. *J Obstet Gynaecol.* **22**: 91-92.
4. **Dorfler-Grassauer D., Nagele F., Kudielka I., Wieser F., Husslein P.** 1998. Emergency combined cesarean section and thoracoscopic pleurodesis in a patient with recurrent spontaneous pneumothorax. *Acta Obstet Gynecol Scand.* **77**: 787-788.
5. **Gorospe L., Puente S., Madrid C., Novo S., Gil-Alonso J. L., Guntinas A.** 2002. Spontaneous pneumothorax during pregnancy. *South Med J.* **95**: 555-558.
6. **Johnson S. R., Tattersfield A. E.** 2000. Clinical experience of lymphangioliomyomatosis in the UK. *Thorax.* **55**: 1052-1057.
7. **Levine A. J., Collins F. J.** 1996. Treatment of pneumothorax during pregnancy. *Thorax.* **51**: 338-339:discussion 340-341.
8. **Reid C. J., Burgin G. A.** 2000. Video-assisted thoracoscopic surgical pleurodesis for persistent spontaneous pneumothorax in late pregnancy. *Anaesth Intensive Care.* **28**: 208-210.
9. **Terndrup T. E., Bosco S. F., McLean E. R.** 1989. Spontaneous pneumothorax

PNEUMOTHORAX DURING PREGNANCY

complicating pregnancy--case report and review of the literature. *J Emerg Med*.**7**: 245-248.

10. **VanWinter J. T., Nichols F. C. 3rd, Pairolero P. C., Ney J. A, Ogburn P. L. Jr.** 1996. Management of spontaneous pneumothorax during pregnancy: case report and review of the literature. *Mayo Clin Proc*.**71**: 249-252.
11. **Warren S. E., Lee D., Martin V., Messink W.** 1993. Pulmonary lymphangiomyomatosis causing bilateral pneumothorax during pregnancy. *Ann Thorac Surg*.**55**: 998-1000.