

## Mosaic Tetrasomy 9p Case with the Phenotype Mimicking Klinefelter Syndrome and Hyporesponse of Gonadotropin-Stimulated Testosterone Production

WAKAKO OGINO<sup>1</sup>, YASUHIRO TAKESHIMA<sup>1</sup>,  
ATSUSHI NISHIYAMA<sup>1</sup>, MARIKO YAGI<sup>1</sup>,  
NOBUTOSHI OKA<sup>2</sup>, and MASAFUMI MATSUO<sup>1</sup>

<sup>1</sup>*Department of Pediatrics, Kobe University Graduate School of Medicine,*

<sup>2</sup>*Department of Urology, Hara Hospital*

Received 4 January 2007/ Accepted 24 January 2007

**Key word:** tetrasomy 9p, Klinefelter syndrome, FISH, concealed penis

**Tetrasomy 9p is a rare clinical syndrome and about 30% of known cases exhibit chromosome mosaicism. The cases with tetrasomy 9p mosaicism have been reported to show the various phenotypes. On the other hand, Klinefelter syndrome is well recognized chromosomal abnormality caused by an additional X chromosome in males (47,XXY), and the characteristic clinical findings include tall stature, immaturity of external genitalia, testicular dysfunction. Here, we report a 10-year-old male with tetrasomy of 9p mosaicism, whose phenotypic feature is mimicking Klinefelter syndrome. He was referred to our hospital for inconspicuous penis. He showed tall height (+2.5 SD). Endocrinological examination revealed the poor testosterone response to human chorionic gonadotropin administration, which indicated the testicular hypofunction, whereas MRI revealed concealed penis as a cause of inconspicuous penis. Because of the phenotype mimicking Klinefelter syndrome, karyotype of his blood lymphocytes was analyzed, and an additional marker chromosome was detected in 6% of the investigated metaphases. Fluorescence in situ hybridization analysis revealed that the marker chromosome was an isochromosome 9p, which resulted in tetrasomy 9p. Chromosome analysis of buccal smear also showed mosaicism for two karyotypes: 5% of cells had the isochromosome of 9p, and the other cells showed normal. This case is the second case with tetrasomy 9p mosaicism mimicking Klinefelter syndrome phenotype in the world. Our case, together with previously reported cases with the same association, indicates the possibility of testicular hypofunction and urogenital anomalies induced by overexpression of some genes on chromosome 9p.**

9p isochromosome formation is frequently caused by meiosis II nondisjunction followed by rearrangements leading to duplication of the short arm and loss of the long arm [10]. Since first description of tetrasomy 9p case by Ghymers et al [13], at least 30 cases have been described, and almost cases were due to addition of isochromosome 9p [7-9,11,15,20,21,32,34,37]. The tetrasomy 9p phenotype varies in severity from neonatal death to mild developmental delay and minor anomalies. One third of the reported cases showed the mosaicism of tetrasomy 9p in a tissue-limiting manner, which is one cause of wide variety of phenotype.

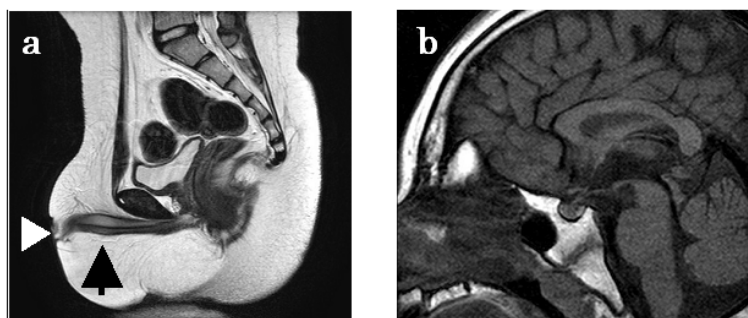
On the other hand, Klinefelter syndrome is well recognized chromosomal abnormality caused by an additional X chromosome in males (47,XXY), and the characteristic clinical findings include tall stature, immaturity of external genitalia, and testicular dysfunction [19]. Although additional X chromosomes is predominantly inactivated, the entire chromosome region is not inactivated, and inactivated region of additional X chromosome is likely to be responsible for clinical features.

Although urogenital anomalies were reported as a clinical feature of tetrasomy 9p case [4,7,9,32], phenotypes mimicking Klinefelter syndrome such as inconspicuous penis and testicular hypofunction are rare [28]. Here we describe a mosaic tetrasomy 9p case with the phenotype mimicking Klinefelter syndrome and hyporesponse of human chorionic gonadotropin (hCG) - stimulated testosterone production.

### CASE REPORT

The patient, a male, is the second child of healthy, non-consanguineous parents. One brother is healthy. The family history was negative for abortion and genetic abnormality. The pregnancy was uneventful. Delivery was at 38 weeks of gestation with a birth weight 2792g, birth length 50cm, and head circumference 33cm. Apgar score was 9 at 1 min. His motor development was normal, and health condition was good. And he made good scholastic progress and showed no sign of mental retardation.

At 10 years, he was referred to our hospital for inconspicuous penis. Height was 155cm (+2.5SD) and weight was 60kg (+2.9SD). Hand wrist roentgenogram revealed that his skeletal age was 11 years old. Physical examination showed inconspicuous penis. His pubic hair was Tanner I, and the length of his penis was 0.5cm, whereas he did not show any other feminized symptom. The craniofacial appearance of this patient is not specific. Because these clinical features initially suggested Klinefelter syndrome, internal and external genitalia was examined using MRI. The abdominal MRI revealed that the inconspicuous penis was caused by the concealed penis, and mullerian derivatives were not detected (Fig 1a). The head MRI revealed no abnormal finding (Fig 1b).



**Fig 1.** MRI findings of the index case. (a) The sagittal section of abdominal MRI. The inconspicuous penis is caused by the concealed penis, and this image shows neither uterus nor ovary. Arrow and arrow-head represent the concealed penis and the inconspicuous penis, respectively. (b) The sagittal section of brain MRI. This image shows the normal pituitary gland.

Because of his tall stature, he was examined endocrinologically. Basal serum GH and somatomedin C levels were less than 0.2 ng/ml and 280 ng/ml, respectively. Basal serum

## MOSAIC TETRASOMY 9P MIMICKING KLINEFELTER SYNDROME

LH and FSH levels were <0.1 mIU/ml and 0.9 mIU/ml, respectively, and peak LH and FSH levels were 1.8 mIU/ml and 6.1 mIU/ml after GnRH administration. Basal testosterone level was 0.4 ng/ml and 1.0 ng/ml after intramuscular hCG (4000IU/m<sup>2</sup>) administration for 3 consecutive days (Table 1).

These results indicated that pituitary gonadotroph functioned in accordance with his pubertal stage, whereas testosterone production was insufficient [18].

### Endocrinological examinations

testosterone (ng/ml)		FSH (mIU/mL)		LH (mIU/mL)	
basal	after hCG stimulation*	basal	peak during GnRH test **	basal	peak during GnRH test **
0.4	1.0	0.9	6.1	< 0.1	1.8

**Table 1.** The data of endocrinological examination of the index case.

\* indicates hCG 4000IU/m<sup>2</sup>/dose im, for 3 consecutive days, and blood sampling on day 4.

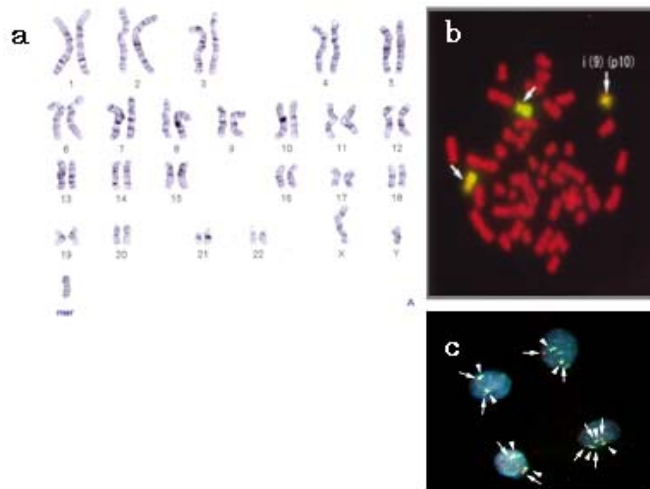
\*\* indicates 100µg/ m<sup>2</sup> bolus iv, blood sampling at 0,30,60,90, and 120 min.

### CYTOGENETIC ANALYSIS

Chromosome examination of a 72-hr peripheral blood lymphocyte culture stimulated with phytohemagglutinin (PHA) showed an extra chromosome in 6% of metaphases analyzed (Fig. 2a). G-banding revealed that the extra chromosome was an isochromosome 9p. FISH (fluorescence in situ hybridization) studies of lymphocytes were performed to confirm the origin of this isochromosome, using the whole chromosome 9-specific painting probe (WCP9) (Fig. 2b), and the result was compatible with isochromosome 9p. In summary, the patient's karyotype was 47,XY, +mar[6]/ 46,XY[94].ish i(9)(p10)(wcp9+), which indicated tetrasomy 9p. Since it was reported that the ratio of abnormal cells with isochromosome 9 was various among the different tissues, the buccal mucosa cells were analyzed by FISH again. For this analysis the paired probes to the chromosome 9 centromeric (CEP9) and p16 (9p21) regions were used. In buccal smear, interphasic FISH studies revealed that 5% of cells show tetrasomy 9p (Fig. 2c).

### DISCUSSION

Tetrasomy 9p is a rare clinical syndrome and about 30% of known cases exhibit chromosome mosaicism [32]. Previously reported features of tetrasomy 9p of both mosaic and non-mosaic cases were characteristic facial appearances with hypertelorism (72%), broad nasal root or bulbous / beaked nose (69%), cleft lip or palate (78%), ear anomalies (88%), and micrognathia (59%) [9]. Other frequent clinical features include developmental delay (94%), central nervous system anomaly (89%), limb defects (88%), postnatal growth failure (71%), congenital heart disease (62%), small gestational age (57%), renal anomalies (57%), wide sutures / large fontanelle (56%), and short neck / excess nuchal skin (53%). Abnormal genitalia were also complicated in 56% of male case, and 38% of female case [9]. Clinical findings of the index case included the inconspicuous penis, which was caused by the concealed penis. As shown in Table 2, in part of the cases with mosaic tetrasomy 9p, urogenital abnormalities were also reported.



**Fig 2.** Chromosomal analysis of the index case. (a) G-banded karyotype of lymphocytes. A marker chromosome (mar) was detected in 6% of lymphocytes and suggested to be an isochromosome 9p. (b) FISH studies of lymphocytes using whole chromosome 9p probe (WCP9). Bright signals indicate the location of 9p, and arrows with and without i(9)(p10) indicate the isochromosome 9p and short arm of normal chromosome 9. This picture makes it possible to confirm the origin of this isochromosome, and the patient's karyotype was determined as 47,XY, +mar[6]/ 46,XY[94]. ish i(9)(p10)(wcp9+). (c) Interphasic FISH study of buccal smear. Bright signals with arrow indicate the LSIP16 probe hybridization to short arm of chromosome 9 (9p21), and bright signals with arrow-head indicate the CEP probe hybridized to centromeric region of chromosome 9. The right lower cells included the isochromosome 9p, and the others were normal. Five percent of the buccal mucosa cells showed 9p tetrasomy.

### Reported cases with mosaic 9p tetrasomy

Blood (% of abnormal cells)	Skin (others)*	Karyotype	Urogenital anomalies	Reference
100	0	idic(9) (q12)		Ghymers., 1973
86	?	i (9) (p10)		Rutten et al., 1974
96	70	i (9) (p10)		Orye et al., 1975
100	0	i (9) (p10)		Cuoco et al., 1982
100	0	idic(9) (q13)	cryptorchidism	Peters et al., 1982
97	?	idic(9) (q12)	inconspicuous penis	Balestrazzi et al., 1983
100	55	idic(9) (q21)	hypoplastic genitalia	Calvieri et al., 1988
98	11	idic(9) (q12)		Papenhausen et al., 1990
28	?	idic(9) (q21)	hypoplastic genitalia	Nakamura et al., 1990
75	0	idic(9) (q12)		Grass et al., 1993
6	?	idic(9) (q21)		Andou et al., 1994
32	1st: 0, 2nd: 62	i (9) (p10)		Eggermann et al., 1998
88	?	idic(9) (q12)		Stumm et al., 1999
75	AF: 50	idic(9) (q13)		Cazorla et al., 2003
30	0	i (9) (p10)		Lloveras et al., 2004
68	buccal smear: 13	i (9) (p10)		
95	85	i (9) (p10)	horseshoe kidney	Tang et al., 2004
20	0	i (9) (p10)	oligospermia	McAuliffe et al., 2005
6	buccal smear: 5	i (9)(p10)	concealed penis	Present report

**Table 2.** Reported cases with mosaic 9p tetrasomy. \*: 1st and 2nd represent the 1st and 2nd skin biopsy, respectively. AF means the amniotic fluid sampling of each case. The following 14 references are cited: [1,2,4-6,11,13,14,20,21,24,26-28,30,32,33].

## MOSAIC TETRASOMY 9P MIMICKING KLINEFELTER SYNDROME

The clinical feature of the index case was tall height, and inconspicuous penis, which was mimicking Klinefelter syndrome. Because in the case of Klinefelter syndrome inconspicuous penis is usually caused by micropenis, the cause of inconspicuous penis was different from our case. However, insufficient production of testosterone was revealed in the index case as well as Klinefelter syndrome. Only one case with mosaic tetrasomy 9p mimicking Klinefelter syndrome was previously reported [28]. Furthermore, one mosaic tetrasomy 9p case with oligospermia and two trisomy 9p cases with ovarian dysfunction have been reported [6,21]. We found that these cases were not more frequent, but it was supposed that genital function was related with tetrasomy 9p. On the other hand, the reason for the tall height remained unclear, because serum somatomedin C level was not so high.

Reported cases of tetrasomy 9p in the literature can be grouped into three types based on the nature of the isochromosome by Dhandha et al [9]. In the cases of the first type, the isochromosome has breakpoint at p10 with no portion of the long arm of chromosome 9 present. In the second the isochromosome includes a small amount of the heterochromatic region of 9q, extending to 9q12 or 9q13. And in the third type cases, the isochromosome included a larger portion of the long arm of chromosome 9, extending to 9q21 or 9q22 (Table 2). It is controversial whether the nature of the isochromosome may influence phenotype, or not [14,32]. Isochromosome of our case is the first type, in which the break point is located at p10, whereas the second type isochromosome was detected in the reported tetrasomy 9 case mimicking Klinefelter syndrome [28]. These findings suggest that the testicular hypofunction is not determined by the portion of isochromosome breakpoint.

Isochromosome 9p shows a strong tendency to tissue-limited mosaicism [4-6,11,14,20,21,26-28,33]. It is predominantly detected in peripheral blood, and often at a lower frequency or it is absent in skin including the buccal mucosa [20]. Until now the different mosaic ratio among the examined tissues was reported in 13 cases (Table 2). However, there is no report about the ratio of mosaicism in internal organs, such as testis. Our case is mosaic tetrasomy 9p; the level of mosaicism in peripheral blood cultures is as low as in buccal smear. Although the correlation between the severity of the phenotype and the degree of mosaicism are still now discussed, a review of the literature reveals that phenotypic differences are more likely to be the result of the degree of mosaicism [9,14,17,22,31,35,37]. In our case testosterone response after hCG administration was low, which indicates the hypofunction of testis. It is likely that the percentage of tetrasomy 9p in testis is higher than that in lymphocytes or buccal mucosa.

In partial monosomy 9p patients, male to female sex reversal has been described, and haploinsufficiency of unknown testis determining factor(s) has been proposed as a cause of sex reversal [12,23,25,36,38]. DMRT1 (Doublesex and MAB-3 related transcription factor 1) gene on chromosome 9p is reported as a candidate gene for 9p sex reversal [3,29]. Because the expression levels of all known genes so far to be involved in the sex-determining cascade are finely tuned, overexpression of testis determining gene on chromosome 9p might be also cause for gonadal dysfunction. This idea is supported by the 46,XY gonadal dysgenesis case with partial duplication of chromosome 9p [16]. Trisomy 9p and mosaic tetrasomy 9p cases with gonadal hypofunction were also reported [6,21,28]. These cases suggest the possibility of testicular hypofunction induced by overexpression of some genes on chromosome 9p.

In summary, the case with tetrasomy 9p mosaicism mimicking Klinefelter syndrome phenotype and hyporesponse of hCG-stimulated testosterone production was reported. Our case, together with previously reported cases with the same association, indicates the

possibile testicular hypofunction induced by overexpression of some genes on chromosome 9p.

#### REFERENCES

1. **Andou, R., Mimaki, T., Ogihara, T., Tamai, H., and Mino, M.** 1994. A case of tetrasomy 9p. *Acta Paediatr Jpn* **36**: 724-726.
2. **Balestrazzi, P., Croci, G., Frassi, C., Franchi, F., and Giovannelli, G.** 1983. Tetrasomy 9p confirmed by GALT. *J Med Genet* **20**: 396-399.
3. **Calvari, V., Bertini, V., De Grandi, A., Peverali, G., Zuffardi, O., Ferguson-Smith, M., Knudtzon, J., Camerino, G., Borsani, G., and Guioli, S.** 2000. A new submicroscopic deletion that refines the 9p region for sex reversal. *Genomics* **65**: 203-212.
4. **Calvieri, F., Tozzi, C., Benincori, C., De Merulis, M.V., Bellussi, A., Genuardi, M., and Neri, G.** 1988. Partial tetrasomy 9 in an infant with clinical and radiological evidence of multiple joint dislocations. *Eur J Pediatr* **147**: 645-648.
5. **Cazorla Calleja, M.R., Verdu, A., and Felix, V.** 2003. Dandy-Walker malformation in an infant with tetrasomy 9p. *Brain Dev* **25**: 220-223.
6. **Cuoco, C., Gimelli, G., Pasquali, F., Poloni, L., Zuffardi, O., Alicata, P., Battaglino, G., Bernardi, F., Cerone, R., Cotellessa, M., Ghidoni, A., and Motta, S.** 1982. Duplication of the short arm of chromosome 9. Analysis of five cases. *Hum Genet* **61**: 3-7.
7. **de Azevedo Moreira, L.M., Freitas, L.M., Gusmao, F.A., and Riegel, M.** 2003. New case of non-mosaic tetrasomy 9p in a severely polymalformed newborn girl. *Birth Defects Res A Clin Mol Teratol* **67**: 985-988.
8. **Deurloo, K.L., Cobben, J.M., Heins, Y.M., de Ru, M., Wijnaendts, L.C., and van Vugt, J.M.** 2004. Prenatal diagnosis of tetrasomy 9p in a 19-week-old fetus with Dandy-Walker malformation: a case report. *Prenat Diagn* **24**: 796-798.
9. **Dhandha, S., Hogge, W.A., Surti, U., and McPherson, E.** 2002. Three cases of tetrasomy 9p. *Am J Med Genet* **113**: 375-380.
10. **Dutly, F., Balmer, D., Baumer, A., Binkert, F., and Schinzel, A.** 1998. Isochromosomes 12p and 9p: parental origin and possible mechanisms of formation. *Eur J Hum Genet* **6**: 140-144.
11. **Eggermann, T., Rossier, E., Theurer-Mainka, U., Backsch, C., Klein-Vogler, U., Enders, H., and Kaiser, P.** 1998. New case of mosaic tetrasomy 9p with additional neurometabolic findings. *Am J Med Genet* **75**: 530-533.
12. **Fujimoto, Y., Okuyama, T., Iijima, M., Tanaka, T., Horikawa, R., Yamada, K., and Ogata, T.** 2004. Genitourinary phenotype in XX patients with distal 9p monosomy. *Mol Genet Metab* **82**: 173-179.
13. **Ghymers, D., Hermann, B., Disteche, C., and Frederic, J.** 1973. Partial tetrasomy of number 9 chromosome, and mosaicism in a child with multiple malformations. *Humangenetik* **20**: 273-282.
14. **Grass, F.S., Parke, J.C., Jr., Kirkman, H.N., Christensen, V., Roddey, O.F., Wade, R.V., Knutson, C., and Spence, J.E.** 1993. Tetrasomy 9p: tissue-limited idic(9p) in a child with mild manifestations and a normal CVS result. Report and review. *Am J Med Genet* **47**: 812-816.
15. **Henriques-Coelho, T., Oliva-Teles, N., Fonseca-Silva, M.L., Tibboel, D., Guimaraes, H., and Correia-Pinto, J.** 2005. Congenital diaphragmatic hernia in a patient with tetrasomy 9p. *J Pediatr Surg* **40**: e29-31.
16. **Ion, R., Telvi, L., Chaussain, J.L., Barbet, J.P., Nunes, M., Safar, A., Rethore, M.O.,**

## MOSAIC TETRASOMY 9P MIMICKING KLINEFELTER SYNDROME

- Fellous, M., and McElreavey, K.** 1998. Failure of testicular development associated with a rearrangement of 9p24.1 proximal to the SNF2 gene. *Hum Genet* **102**: 151-156.
17. **Jalal, S.M., Kukulich, M.K., Garcia, M., Benjamin, T.R., and Day, D.W.** 1991. Tetrasomy 9p: an emerging syndrome. *Clin Genet* **39**: 60-64.
18. **Kauschansky, A., Frydman, M., Nussinovitch, M., and Varsano, I.** 2004. Evaluation of human chorionic gonadotropin stimulation tests in prepubertal and early pubertal boys. *Eur J Pediatr* **154**: 890-892.
19. **Lanfranco, F., Kamischke, A., Zitzmann, M., and Nieschlag, E.** 2004. Klinefelter's syndrome. *Lancet* **364**: 273-283.
20. **Lloveras, E., Perez, C., Sole, F., Zamora, L., Lladonosa, A., Espinet, B., Silvestre, E., Serra, J., Vendrell, T., Fernandez, B., Salido, M., and Plaja, A.** 2004. Two cases of tetrasomy 9p syndrome with tissue limited mosaicism. *Am J Med Genet A* **124**: 402-406.
21. **McAuliffe, F., Winsor, E.J., and Chitayat, D.** 2005. Tetrasomy 9p mosaicism associated with a normal phenotype. *Fetal Diagn Ther* **20**: 219-222.
22. **Melaragno, M.I., Brunoni, D., Patricio, F.R., Corbani, M., Mustacchi, Z., dos Santos Rde, C., and Lederman, H.M.** 1992. A patient with tetrasomy 9p, Dandy-Walker cyst and Hirschsprung disease. *Ann Genet* **35**: 79-84.
23. **Muroya, K., Okuyama, T., Goishi, K., Ogiso, Y., Fukuda, S., Kameyama, J., Sato, H., Suzuki, Y., Terasaki, H., Gomyo, H., Wakui, K., Fukushima, Y., and Ogata, T.** 2000. Sex-determining gene(s) on distal 9p: clinical and molecular studies in six cases. *J Clin Endocrinol Metab* **85**: 3094-3100.
24. **Nakamura, Y., Sato, E., Sakai, K., Sakuma, S., Hashimoto, T., and Sindou, S.** 1990. Abnormal chromosome 9 in a neonate program. Report of three cases. *Arch Pathol Lab Med* **114**: 185-187.
25. **Ogata, T., Muroya, K., Ohashi, H., Mochizuki, H., Hasegawa, T., and Kaji, M.** 2001. Female gonadal development in XX patients with distal 9p monosomy. *Eur J Endocrinol* **145**: 613-617.
26. **Orye, E., Verhaaren, H., Van Egmond, H., and Devloo-Blancquaert, A.** 1975. A new case of the trisomy 9P syndrome. Report of a patient with unusual chromosome findings (46,XX/47,XX, +i (9p) and a peculiar congenital heart defect. *Clin Genet* **7**: 134-143.
27. **Papenhausen, P., Riscile, G., Miller, K., Kousseff, B., and Tedesco, T.** 1990. Tissue limited mosaicism in a patient with tetrasomy 9p. *Am J Med Genet* **37**: 388-391.
28. **Peters, J., Pehl, C., Miller, K., and Sandlin, C.J.** 1982. Case report of mosaic partial tetrasomy 9 mimicking Klinefelter syndrome. *Birth Defects Orig Artic Ser* **18**: 287-293.
29. **Raymond, C.S., Parker, E.D., Kettlewell, J.R., Brown, L.G., Page, D.C., Kusz, K., Jaruzelska, J., Reinberg, Y., Flejter, W.L., Bardwell, V.J., Hirsch, B., and Zarkower, D.** 1999. A region of human chromosome 9p required for testis development contains two genes related to known sexual regulators. *Hum Mol Genet* **8**: 989-996.
30. **Rutten, F.J., Scheres, J.M., Hustinx, T.W., and ter Haar, B.G.** 1974. A presumptive tetrasomy for the short arm of chromosome 9. *Humangenetik* **25**: 163-170.
31. **Schaefer, G.B., Domek, D.B., Morgan, M.A., Muneer, R.S., and Johnson, S.F.** 1991. Tetrasomy of the short arm of chromosome 9: prenatal diagnosis and further delineation of the phenotype. *Am J Med Genet* **38**: 612-615.
32. **Stumm, M., Tonnie, H., Mandon, U., Gotze, A., Krebs, P., and Wieacker, P.F.** 1999. Mosaic tetrasomy 9p in a girl with multiple congenital anomalies: cytogenetic and molecular-cytogenetic studies. *Eur J Pediatr* **158**: 571-575.
33. **Tang, W., Boyd, B.K., Hummel, M., and Wenger, S.L.** 2004. Prenatal diagnosis of tetrasomy 9p. *Am J Med Genet A* **126**: 328.

34. **Tonk, V.S.** 1997. Moving towards a syndrome: a review of 20 cases and a new case of non-mosaic tetrasomy 9p with long-term survival. *Clin Genet* **52**: 23-29.
35. **Van Hove, J., Kleczkowska, A., De Bruyn, M., Bekaert, J., and Fryns, J.P.** 1994. Tetrasomy 9p: prenatal diagnosis and fetopathological findings in a second trimester male fetus. *Ann Genet* **37**: 139-142.
36. **Veitia, R.A., Salas-Cortes, L., Ottolenghi, C., Pailhoux, E., Cotinot, C., and Fellous, M.** 2001. Testis determination in mammals: more questions than answers. *Mol Cell Endocrinol* **179**: 3-16.
37. **Verheij, J.B., Bouman, K., van Lingen, R.A., van Lookeren Campagne, J.G., Leegte, B., van der Veen, A.Y., Hofstra, R.M., Buys, C.H., and van Essen, A.J.** 1999. Tetrasomy 9p due to an intrachromosomal triplication of 9p13-p22. *Am J Med Genet* **86**: 168-173.
38. **Vialard, F., Ottolenghi, C., Gonzales, M., Choiset, A., Girard, S., Siffroi, J.P., McElreavey, K., Vibert-Guigue, C., Sebaoun, M., Joye, N., Portnoi, M.F., Jaubert, F., and Fellous, M.** 2002. Deletion of 9p associated with gonadal dysfunction in 46,XY but not in 46,XX human fetuses. *J Med Genet* **39**: 514-518.