

Abdominal Malignant Fibrous Histiocytoma Infiltrating Stomach with Chilaiditi's Sign Manifestation (A Rare Case Report)

SITI NURDJANAH, PUTUT BAYUPURNAMA,
SUTANTO MADUSENO, and NENENG RATNASARI

*Division of gastroentero-hepatology, Department of Internal Medicine, Faculty of Medicine,
Gadjah Mada University/Dr. Sardjito Hospital Yogyakarta, Indonesia*

Received 28 August 2006 /Accepted 29 September 2006

Keywords: Malignant fibrous histiocytoma (MFH), soft tissue sarcoma, undifferentiated pleomorphic sarcoma, Chilaiditi's sign, Chilaiditi's syndrome

The incidence and mortality rate of gastric cancer are decreasing within last 60 years. Approximately 85% of gastric cancer is carcinoma where as the rest 15% is lymphoma and sarcoma.

Leiomyosarcoma is the most frequently encountered sarcoma in stomach and represents 1-3% gastric cancer. This tumor is frequently located in the anterior and posterior wall of gastric fundus accompanied by ulceration and bleeding.

Malignant fibrous histiocytoma (MFH) is a soft tissue tumor with poor prognosis, rarely found in stomach. This tumor is most frequently originated from inner fascia or skeletal muscle (58-75%) and most frequently happen in the peritoneal cavity and abdomen (9-16 %).

We reported a 45-year-old woman with abdominal MFH which infiltrated to the lesser curvature of stomach with Chilaiditi sign.

Chilaiditi sign is a condition of intestine disposition (usually at the hepatic flexure of colon) which lies between liver and diaphragm, found in 0.1 – 0.25% cases which is diagnosed by chest X Ray. This case is a very rare case.

Malignant fibrous histiocytoma (MFH) is a kind of sarcoma, a rare malignant tumor, derived from mesenchymal tissues in the body (1). Its annual incidence is 30 cases in one million population. Most of it is derived from soft tissues and some part is derived from bone tissue (2).

Chilaiditi's syndrome is a condition associated with intestinal disposition (usually as colon-hepatic flexure), which is located between liver and diaphragm. This condition is rarely found and about 0.1 - 0.25% cases are accidentally diagnosed through radiographic examination. This syndrome is caused by weak suspensory colon ligament as a result of some factors such as malignancy adjacent to colon (3, 4).

This case report aims to describe a rare gastric malignancy case in the form of MFH with Chilaiditi's sign.

CASE ILLUSTRATION

A 44 year-old female housewife was admitted to hospital on March 24th, 2005. Her chief complaint was fatigue and weight loss. Her current disease history was as follows: five months before admission, she felt fatigue, easily exhausted, loss appetite, nausea and weight loss. She had experienced a black stool once, without any bloody vomiting. Her daily stool

and urine was normal. Five days before admission, her body was pale and weak, with normal urination and defecation. Her previous disease history revealed no history of taking pain killer drugs (NSAID, etc) and any herbal medicine. There was no history of diabetes mellitus and hepatitis. She rarely experienced regular menstrual period. Her family disease history revealed no similar disease or malignant disease in her family.

On physical examination, her general condition revealed weak condition, moderate nutrition state, and fully alert. Her vital signs were blood pressure 120/80 mmHg, pulse rate 90 x / minute, regular rate, respiratory rate: 24 x/minute and temperature 36.8 °C. There was no pallor in conjunctiva, no jaundice on sclera, and atrophy found in her tongue bud. Thorax examination revealed: heart examination: left heart border was hardly evaluated, pure and regular heart sound (S₁ and S₂), without any murmur found. Lung examination revealed normal result for the right lung. On the left lung examination there was muffle sound on percussion and reduced vesicular sound. Abdominal examination revealed no palpable mass, no ascites and there was positive intestinal sound. No hepatomegaly and splenomegaly were found. The extremities were normal.

Laboratory examination revealed hemoglobin 7.85 g/dL, leukocytes 16,900 / μ L, differential count of leukocytes: neutrophils: 75.7%, lymphocytes 17.3%, monocytes 5.03%, eosinophil 1.22%, basophil 0.75%, platelet 779,000 / μ L, erythrocytes 3,85 million / μ L, hematocrit 26.1%, , Aspartate amino transferase (AST) 11 μ I, Alanine amino transferase (ALT) 12 μ I, Alkaline phosphatase (ALP): 241 μ I, Gamma glutamyl transpeptidase 20 μ I, total protein 7.2 g/dL, albumin 3.4 g/dL, Cholinesterase 3,189 μ I, prothrombin time 13.8 (control 14), partial thromboplastin time 30.5 (control 32.3). Fecal examination revealed normal result. Peripheral blood examination revealed impression of iron and folic acid deficiency anemia, there was possibility of chronic disorder and bleeding process.

Chest X-ray examination revealed a lucent shade in the right lung and there was no heart enlargement. Left lung was not clear with flattening border and there was haustral accompanied with air-fluid level image which led to suspicion of Chilaiditi's sign. The differential diagnosis was lung abscess.

In the beginning, the patient refused endoscopic examination. But later, endoscopic examination of gastrointestinal tract was performed. Ultrasonography examination revealed normal liver, spleen, gall bladder and kidney. Endoscopy revealed no varicose of esophagus / stomach. There was a protruded mass with pale red color in gastric fundus, without any bleeding and normal duodenum.

Computed tomography scan of thorax and abdomen revealed: left decline with left pleural effusion and diaphragmatic hernia (insertion of gastric fundus) with thickening of gastric wall.

The patient was prepared for operation. Laparotomy result was left diaphragm was pushed upward, transverse colon was inferior to diaphragm (colon disposition). The tumor mass on gastric lesser curvature joined together with liver, stomach was pushed downward by colon and tumor mass. The tumor mass caused adhesion and it adhered to all of abdominal organ till the posterior abdominal wall. The adhered tissue was released and there was about 200 mL of pus, the adjacent tissue was fragile, and a biopsy was performed. Tumor resection was unable to be performed anymore. Pathologic examination revealed MFH. Confirmed diagnosis was MFH with manifestation of Chilaiditi's sign. The patient disagree to the administration of chemotherapy because of its side effect. Finally, 2 months after her operation, she died at home.

CHILAUDITI IN MALIGNANT FIBROUS HISTIOCYTOMA

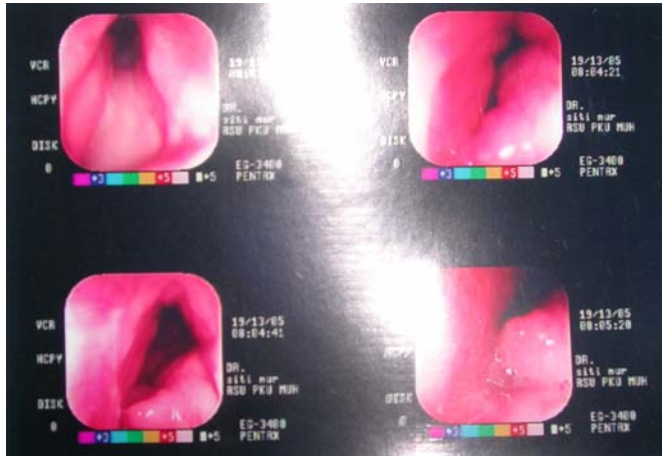


Figure 1. Endoscopy: in esophagus, there is no varicose and no erosion. On gastric fundus: there is a mass without any bleeding

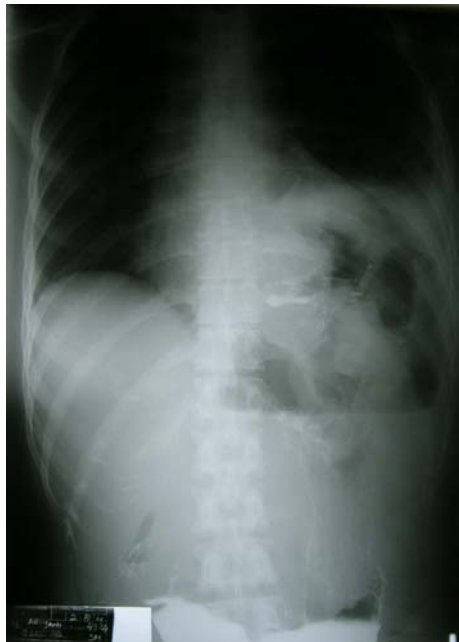

Figure 2: Chest X-ray: Suspicion of Chilaiditi's sign, differential diagnosis lower left lung abscess

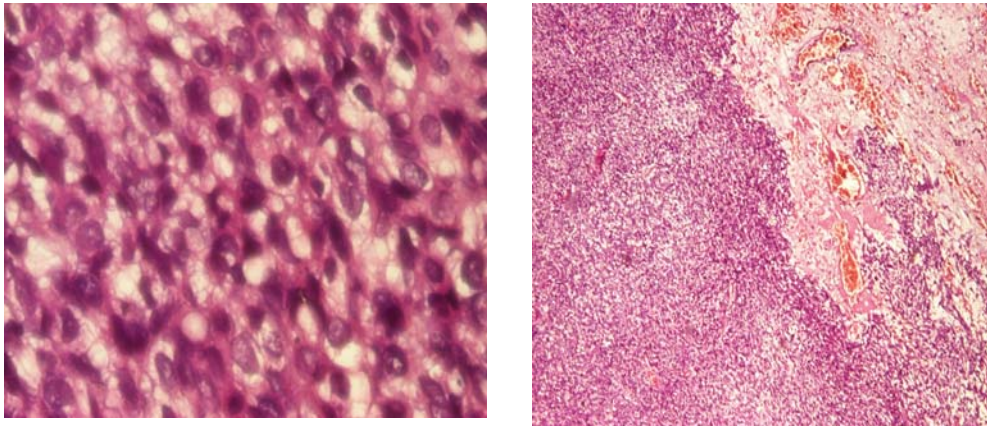


Figure 3: Biopsy of gastric tissue: Malignant fibrous histiocytoma

DISCUSSION

Most of gastric carcinoma is adenocarcinoma (85%), while part of it (15%) is in the form of lymphoma and sarcoma. Leiomyosarcoma is the most common sarcoma in stomach and represents 1-3% of gastric malignancy. This tumor usually appears in antral wall and posterior wall of gastric fundus accompanied with ulceration and malignant bleeding (5,6).

Clinical manifestation of MFH and Chilaiditi's syndrome rarely occurs. In Indonesia, such case has never been reported.

MFH is a soft tissue tumor with poor prognosis. This disease is the most common soft tissue sarcoma in adult and elderly patient, but it is rarely found in stomach. This tumor is commonly found in upper and lower extremities as well as peritoneum. It is also known as malignant fibrous xanthoma, pleomorphic fibrous histiocytoma and pleomorphic fibrous xanthoma (2,7). The most common MFH is derived from deep fascia or skeletal muscle (58-75%) and frequently occur in retroperitoneal cavity and abdominal cavity (9-16%). Histologically, this tumor is a pleomorphic sarcoma consisting 2 type of cells, namely fibroblast type and histiocyte type (1,8). In this case, there is a gastric tumor: Pathological examination reveals MFH.

The most common clinical manifestation of MFH is asymptomatic mass. Mechanical symptoms occur because of compression, traction or entrapment of nerve fiber or muscle fiber. MFH is likely to have hematogenic metastases rather than lymphatic metastases. Metastases to lymph node are found in 5% cases, in contrast to sinovial sarcoma, epitheloid sarcoma, clear-cell sarcoma, angiosarcoma and rhabdomyosarcoma which have lymph node spread in 17% cases. Lung parenchyma is the most common location for MFH metastases; unlike leiomyosarcoma which has liver metastases, myxoid liposarcoma which has metastases to adipose tissue and clear-cell sarcoma with bone metastases. Metastases to central nervous system was found in alveolar soft part sarcoma (9).

Chilaiditi's syndrome is a condition associated with intestinal disposition (usually as transversal colon-hepatic flexure), which is located between liver and right diaphragm, and is usually asymptomatic. Chan describes that asymptomatic colon disposition against diaphragm and liver is called as Chilaiditi' sign and it is called as Chilaiditi's syndrome if

CHILAITIDI IN MALIGNANT FIBROUS HISTIOCYTOMA

there is any symptom occur (10). This condition was initially described by Demetrius Chilaiditi, a radiologic expert from Venesia, Italia in 1910. This is a rare condition, which 0.1-0.25% cases are diagnosed by chest radiographic examination and most of cases are accidentally found in clinical evaluation of concomitant disease. This syndrome is more commonly found in male and most of them are adult male patient (3,4).

Chilaiditi's syndrome was characterized by abdominal pain, constipation, vomiting, respiratory distress, and anorexia. This syndrome is important because it may cause pneumoperitoneum. If pneumoperitoneum is present, it will be more complicated for diagnosis. Therefore, an abdominal CT Scan should be performed. In several cases, simple chest or abdominal radiographic examination may reveal such diagnosis (11). Diagnosis of Chilaiditi's syndrome sometimes is similar to obstructed ectopic kidney appearance, which has intestinal dilatation feature in upper abdominal region (12).

In this case, MFH is found in gastric fundus and it causes adhesion of adjacent tissue including liver. This tumor causes organ adhesion such as liver, colon, stomach and diaphragm. Those organs are tightly fixed by tumor mass. There is possibility that tumor mass is derived from retroperitoneal region because tumor mass fully fills upper abdominal cavity from anterior to posterior part. The tumor tissue in this case is fragile and there is infection which is characterized by increased patient's temperature and increased leukocytes count. It is assumed that anaerobic bacterial infection has occurred because there is pus in tumor location. Colon might be involved in this case. Malignancy process may cause retracted adjacent tissue, as a result there is disposition of transverse colon, liver and stomach in this case.

The diagnosis of Chilaiditi's sign in this case is established based on radiographic features, i.e.. There are haustrae and air fluid level appearances in thoracic cavity as the manifestation of transverse colon.

Double contrast radiographic examination is the simplest procedure that can be used to evaluate patient with epigastric symptoms. This technique is also helpful to find a small lesion. In this procedure, stomach should be distended in every slide session because reduced stomach elasticity may be found in diffuse infiltrative carcinoma (13).

On CT scan examination, MFH may appear as inhomogeneous mass with low density. CT scan or MRI may be used to determine the tumor margin and it may reveal the correlation between MFH and adjacent neurovascular structure (14).

MFH with metastases is hardly cured, but up to 20% patient with complete response may experience longer life expectancy. Therefore, the aim of therapy is to obtain complete remission by providing chemotherapy or surgery. Some patients have experienced advantage of repeated surgical excision for tumor with metastases (7,14).

The management of Chilaiditi's sign or syndrome usually performs through surgery. Usually, in surgery we found right colon located totally in intra peritoneal region and it is also located between diaphragm and liver. The liver tissue is apparently smaller than normal. The surgery that usually performed is called Colopexy, i.e. return the right colon to its position and fix it with anterior abdominal wall. After this surgery, abdominal pain usually diminishes (15).

MFH is a malignant sarcoma and it may have metastases. As a result, it will provide difficulty for subsequent therapy. Moreover, unmanaged colon, stomach and liver disposition may cause complication, especially to the lung in the form of life-threatening pneumonia. Two months later, the patient returned home and died in her house.

CONCLUSION

We report a 44 year-old female patient with chief complaint of fatigue, loss weight and anemia. The patient's diagnosis is MFH of stomach with Chilaiditi's sign manifestation. This diagnosis is established based on Pathologic Anatomy result of gastric tissue, physical and radiographic examination. The diagnosis of MFH in stomach still needs further review because MFH is rarely found in stomach.

The prognosis in this patient is poor because MFH is a kind of malignant soft tissue sarcoma and may cause serious complication such as pneumoperitoneum or pneumonia if the Chilaiditi's sign has not been controlled.

ACKNOWLEDGEMENTS

The author would like to express gratitude to Prof. Soeripto, MD Pathologist and Abdul Latief, MD Radiologist for their suggestions.

REFERENCES

1. **Doris Yip.** 2006 July 19. Malignant Fibrous Histiocytoma, Soft Tissue. <http://www.emedicine.com/radio/topic420.htm>.
2. **De Laney TF, Savarese DM.** 2006. Overview of soft tissue sarcoma. *In*: Ross BD (ed) *UpToDate 14.2 version* [cited April, 28]. Available from: www.uptodate.com.
3. **Bickle IC, Kelly B.** 2002. Abdominal X-rays made easy: abnormal extraluminal gas. *Student British Med Journal*; **10**:180-181.
4. **Nakagawa J.** 2000. Images in clinical medicine: Hepatodiaphragmatic interposition of the colon. *New Engl J Med* ; **343(9)**:631.
5. **Crump W, Antonioli DA, Goldman H.** 1999. Lymphoma of the gastrointestinal tract. *Semin Oncol*; **26**: 324.
6. **Fuchs CS, Mayer R.J.** 1995. Gastric carcinoma. *New Engl J Med*; **333**: 32.
7. **Ajisaka H, Maeda K, Uchiyama A, Miwa A.** 2002. Myxoid malignant fibrous histiocytoma of the breast. *Surgery Today*; **32**: 887-890.
8. **Oh SJ, Kim KM, Hong TH, Park WC, Kim JS, Jung SS.** 2004. Giant cell malignant fibrous histiocytoma of the breast: a case report. *J Korean Med Sci*; **19**:447-480.
9. **Patel SR, Benjamin RS.** 2001. Soft tissue and bone sarcomas and bone metastases. *In*: AS Fauci, E Braunwald, KJ Isselbacher, JD Wilson, JB Martin, DL Kasper, SL Hauser, DL Longo (editors). *Harrison's Principles of Internal Medicine*. 15th ed. CD ROM
10. **Chan SC, Liu CL, Lo CM, Fan ST.** 2004. Rapid onset Chilaiditi's sign on top of fulminant hepatic failure, *Hepatobiliary pancreat Dis Int*; **3**: 476-7.
11. **Perez CA, Benedico EC, Matinez DS.** 2003. Chilaiditi's syndrome in the differential diagnosis of the renal colic. *Medifam*; **13**: 41-4.
12. **Plorde JJ, Raker EJ.** 1996. Transverse colon volvulus and associated Chilaiditi's syndrome: case report and literature review. *AM J Gastroenterol*; **91(12)**: 2613-6.
13. **Mayer, R.J.** 2001, gastrointestinal tract cancer, *in* : A.S. Fauci, E. Braunwald, K.J. Isselbacher, J.D. Wilson, J.B. Martin, D.L. Kasper, S.L. Hauser, D.L. Longo (editors) *Harrison's Principles of Internal Medicine*, 15th edition CD ROM
14. **Yucel A, Polat C, Aktepe F, Degirmenci B, Dilek ON.** 2004. A case of malignant fibrous gistiocytoma mimicking pseudoaneurysm. *Med J Kocatepe*; **5**: 91-93.
15. **Altomare DF, Rinaldi M, Petrolino M, Sallatio PL, Guglielmi A, Pannarale OC.** 2001. Chilaiditi's syndrome: successfull surgical correction by colopexy. *Techniques in coloproctology. Springer-Verlag Italia*; **5(3)**: 173-5.