

Ultrasonographic Screening of Carotid Artery in Patients with Vascular Retinopathies

ELIO ARNALDO MARIN-SANABRIA¹, TAKESHI KONDOH¹,
AKIO YAMANAKA² and EIJI KOHMURA¹

¹ *Department of Neurosurgery, Kobe University Graduate School of Medicine*

² *Department of Ophthalmology, Kaisei Hospital, Kobe, Japan*

Received 27 May 2005/ Accepted 14 June 2005

Key Words: carotid artery ultrasound, vascular retinopathy, atherosclerotic progression

Background and Purpose: Retinal vasculopathy is commonly found with complaint of blurred vision by ophthalmologist and closely related to asymptomatic cerebrovascular disease. The purpose of this study was to evaluate patients with microvascular retinopathy by ultrasound sonography of neck carotid artery and to find high risk group for stroke at outpatient of ophthalmology with associated retinopathy.

Methods: Between 1999 and 2001, a total of 480 consecutive patients visited at outpatient of ophthalmology with a complaint of blurred vision were evaluated by ultrasound sonography of neck carotid artery. The patients were divided to with retinopathy (n=253) and without retinopathy (n=227). The former was subgrouped as follows; central retinal vein occlusion (CRVO; n=11), branch of retinal vein occlusion (BRVO; n=71), retinal artery occlusion (RAO; n=8), hypertensive retinopathy group-I (according to Keith, Wagener and Barker's criteria) (HTN-R I; n=43) and group-II (HTN-R II; n=42), and diabetic retinopathy (DM-R; n=78). The latter group was with various ophthalmological diseases, mainly inflammation of cornea, with healthy retinal vessels and constituted as the control group.

Results: There was no statistically significant difference between patients with retinopathy and the control group with respect to sex distribution, nor among the retinopathy groups. Patients with retinopathy had a mean age of 68 years, while those with HTN-R I and II were older with a mean age of 71 years. By ultrasonography, RAO showed pathology in intima-media thickness (IMT; 1.13 ± 0.55 vs. 0.81 ± 0.26 mm in control), average number of plaques (1.88 ± 0.99), degree of stenosis of internal carotid artery (42.4 ± 28.5 %) and common carotid artery (27.4 ± 21.3 %). Those with DM-R had the second thickest IMT (0.96 ± 0.42 mm) and the second highest quantity of plaque (1.23 ± 1.23), and the second most stenotic common carotid artery (13.1 ± 17.28 %).

Conclusion: Moderate sclerotic changes are found in ophthalmology patients with RAO and DM-R, although the degree pathology do not indicate medical nor surgical prophylactic treatment. Retinal vein occlusion, that has been discussed with diminished retinal blood circulation, does not show any differences in comparison with control group and ultra sonography has less value for screening of asymptomatic carotid atherosclerosis.

Ultrasound screening is an effective and safe diagnostic test for extracranial carotid atherosclerosis. (8) It permits assessment of luminal and wall features of the carotid artery

known as the intima-media thickness (IMT), plaque number and morphology, as well as degree of stenosis.

The retina is a unique part of the brain in that it can be visualized, which allows for the observation of microvascular abnormalities that have been associated with carotid artery stenosis. (3, 7, 9, 10, 21, 22)

Carotid atherosclerotic disease may indicate the comorbid of retinal and cerebral vascular events due to low perfusion pressure, which has been associated with ocular manifestations of retinal ischemia such as occlusion of the retinal artery, the central retinal vein and the branch retinal vein. (2, 3, 4, 6, 7, 10) In addition, hypertensive and diabetes retinopathy have been found to correlate with atherosclerosis of the carotid artery. (13, 28) Many attempts have therefore been made to identify retinal vessel symptoms as markers of extracranial carotid artery disease. (1, 3, 7, 20, 22, 25)

Although in many instances, the relation between the degree of carotid stenosis and retinal hypoperfusion has been determined, it is no clear why only some patients with atherosclerosis of the carotid artery progress to retina ischemia.

The purpose of this study was to assess the carotid ultrasound features of patients with vascular retinopathies requested by ophthalmologist from an eye hospital over a period of three years in order to define the predictive value of ocular finding for the presence of atheromatous lesion of the carotid artery.

MATERIALS AND METHODS

The evaluation involved 480 ambulatory patients and was conducted at Kaisei Hospital, a secondary medical center affiliated with Kobe University.

Study Population

Over three years, 1999 to 2001, 251 women and 229 men ranging in age from 38 to 93 years were examined with ultrasound scanning for carotid artery atherosclerosis. Of patients referred for evaluation of the carotid arteries, 253 were referred because of vascular retinopathy. The remaining 227 patients were referred as control group because they did not show evidence of vascular retinopathy. We excluded patients whose data from the ultrasonographic evaluation were incomplete.

Ascertainment of the retinal vessel disease

Eye examinations were performed for routine follow-up or were prompted by chronic visual complaints. All eye examinations consisted of visual acuity, pupil testing, intraocular pressure, dilated fundus examination, and visual field testing if indicated. Ophthalmologic diagnoses were based on standard diagnostic criteria, and were reviewed for accuracy by one of the authors (AY). The diagnosis included hypertensive retinopathy, diabetic retinopathy, branch retinal vein occlusion (BRVO), central retinal vein occlusion (CRVO), or retinal artery occlusion (RAO). Patients with healthy retinal vessels represented the control group. Keith, Wagener and Barker's criteria were used to classify patients with hypertensive retinopathy group I (HTN-R I) and group II (HTN-R II). (2, 13) The control group included patients who had been evaluated for conditions other than vascular retinopathy such as subconjunctival hemorrhage, episcleral vascular congestion, pterygium, trauma, iritis or keratitis.

Ultrasound evaluation

The extracranial carotid arteries were assessed by a single experienced vascular ultrasonographer using a standardized B-mode ultrasonogram (EUB-525; Hitachi Medico, Tokyo) with an electrical linear transducer (mid-frequency: 7.5 MHz). The common, internal, and external carotid arteries were examined for evidence of atherosclerotic lesions as seen in

CAROTID ULTRASONOGRAPHY AND VASCULAR RETINOPATHY

thickness of the IMT, plaque number and grade of stenosis of the common carotid artery (CCA) and internal carotid artery (ICA). Because images of the far-wall segments were more difficult to obtain, the IMT was mainly visualized from the common segment of the carotid artery. As for the plaque number, it was taken as the average number of plaques detected in the CCA and ICA ipsilateral to the affected eye.

Statistical analysis

InStat statistic software was used for all statistical analyses. Gender distribution among the patient groups was analyzed with Fisher's exact test. Differences in the response variable among the seven groups were compared with one-way analysis of variance (ANOVA). Multiple pairwise comparisons were made with Tukey's procedure. For all statistical analysis the threshold for significance was $P < 0.05$.

RESULTS

Of the 253 patients with vascular retinopathy, the most common indications for carotid imaging were fundoscopic findings of hypertensive retinopathy with 85 patients (34 %), 43 of them in group I and 42 in group II. The second most common disease with 82 patients (32 %) was retinal vein occlusion, which was sub-classified into branch or central vein occlusion, with 71 patients in the former and 11 in the latter group. Diabetic retinopathy accounted for 78 patients (31 %). The severity of diabetic retinopathy was graded as mild to moderate non-proliferative retinopathy in 39 patients, severe non-proliferative retinopathy in 6 patients and proliferative diabetic retinopathy in 2 patients. There was not case of diabetic maculopathy in this series. The remaining 31 patients with diabetic retinopathy showed

Table. Summary of cases

	Retinal Vein Occlusion		RAO (8)	Hypertensive Retinopathy		DM – R (78)	Control (227)
	Branch (71)	Central (11)		KWB I (43)	KWB II (42)		
Mean age, y	66.5 ± 10.7	69.1 ± 9.6	63.9 ± 5.6	71.4 ± 8.2 §	71.1 ± 10.6 §	63.8 ± 8.5	67.3 ± 11.2
Female/Male distribution	39/32	4/7	2/6	28/15	25/17	31/47	122/105
Mean IMT, mm	0.87 ± 0.27	0.87 ± 0.16	1.13 ± 0.55 †	0.85 ± 0.24	0.80 ± 0.20	0.96 ± 0.42 ‡	0.81 ± 0.26
Plaque number	0.89 ± 1.02	0.82 ± 0.98	1.88 ± 0.99 *	1.02 ± 1.28	0.60 ± 1.04	1.23 ± 1.23 ‡	0.71 ± 1.03
CCA stenosis, %	12.71 ± 29.08	9.73 ± 12.71	27.40 ± 21.28 ¶	10.17 ± 16.13	6.53 ± 12.42	13.08 ± 17.28	7.21 ± 11.17
ICA stenosis, %	11.67 ± 25.36	10.06 ± 18.76	42.38 ± 28.52	10.37 ± 22.91	7.00 ± 15.34	12.25 ± 22.19	6.78 ± 14.92

RAO: retinal artery occlusion, DM-R: diabetic retinopathy, KWB: Keith, Wagener and Barker classification.

§ $P < 0.01$ vs DM-R

† $P < 0.05$ vs Control

‡ $P < 0.01$ vs Control; $P < 0.05$ vs Hypertensive Retinopathy KWB II

* $P < 0.05$ vs Control; $P < 0.05$ vs Hypertensive Retinopathy KWB II

¶ $P < 0.01$ vs Control; $P < 0.01$ vs Hypertensive Retinopathy KWB II; $P < 0.05$ vs Hypertensive Retinopathy KWB I

$P < 0.05$ vs Control

$P < 0.001$ vs Control; $P < 0.001$ vs BRVO; $P < 0.001$ vs Hypertensive Retinopathy KWB I; $P < 0.001$ vs Hypertensive Retinopathy KWB II; $P < 0.001$ vs DM-R; $P < 0.01$ vs CRVO

ungradable photographs. The less common vascular retinopathy was RAO with eight patients (3 %). A subset of carotid arteries was imaged because of the presence of other ocular findings in 227 patients and was included as control group.

Patient characteristics and ultrasonography morphological findings are summarized in the Table. Analysis of age indicated a statistically significant difference between the hypertensive retinopathy (HTN-R I: 71.4±8.2 years and HTN-R II: 71.1±10.6 years) and diabetic retinopathy groups (63.8±8.5 years), with both sub-groups of the former being significantly older (P<0.01). The ages of all other groups fell between those of the hypertensive and diabetic retinopathy groups without statistically significant differences.

The RAO had high rates of male patients 67 %, whereas the retinopathy and the control group showed a similar distribution of gender with 129 women (51 %) and 122 men (53 %) respectively, without significant difference.

The results of imaging of the ipsilateral carotid artery were correlated with ocular findings at neurosurgical examination. The IMT of the RAO (1.13±0.55 mm; P<0.05) and the diabetic retinopathy (0.96±0.42 mm; P<0.01) were significantly thicker than controls (0.81±0.26 mm).

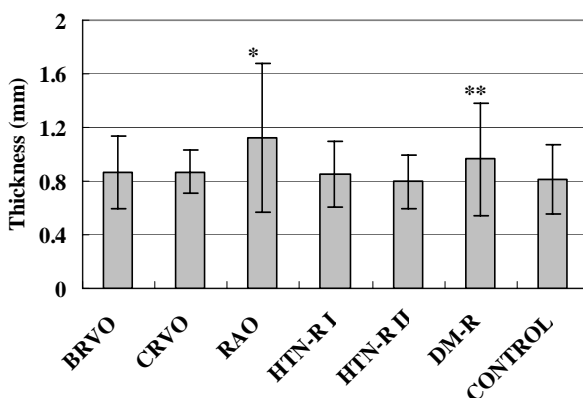


Figure 1. Average thickness in mm of IMT in the ipsilateral common carotid artery by subject group. Statistically significant differences were found for retinal artery occlusion (RAO) compared with control group (P<0.05) (*) and for diabetic retinopathy (DM-R) compared with control group (P<0.01) and with hypertensive retinopathy group II (HTN-R II) (P<0.05) (**).

The highest average plaque number per ipsilateral carotid artery was 1.88 ± 0.99 for the RAO group, which showed statistically significant highest average plaque number than control 0.71±1.03 (P<0.05). Diabetic retinopathy had the second highest average plaque number at 1.23±1.23, showing significant differences with the control (P<0.01).

CCA stenosis was most severe in RAO with 27.40 ± 21.28 %. Diabetic retinopathy was 13.08±17.28 %, and both groups showed a statistically significant degree of stenosis with the control group (7.21±11.17 %).

ICA stenosis was most severe in RAO with 42.38±28.52 %. By comparison, RAO showed a statistically significant degree of stenosis with the control 6.78±14.92 % (P<0.001), and with all other groups as BRVO 11.67±25.36 % (P<0.001), CRVO 10.06±18.76 %

CAROTID ULTRASONOGRAPHY AND VASCULAR RETINOPATHY

($P < 0.01$), HTN-R I 10.37 ± 22.91 % ($P < 0.001$), HTN-R II 7.00 ± 15.34 % ($P < 0.001$) and diabetic retinopathy 12.25 ± 22.19 % ($P < 0.001$).

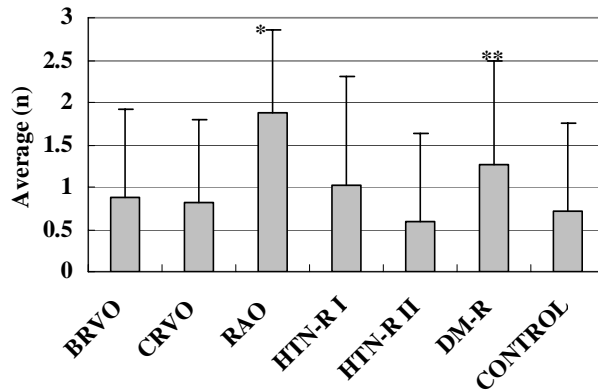


Figure 2. Average plaque number in the common and internal carotid arteries ipsilateral to the evaluated eye. Statistically significant differences were found for retinal artery occlusion (RAO) compared with control ($P < 0.05$) and with hypertensive retinopathy group II (HTN-R II) ($P < 0.05$) (*). The average number of plaques in patients with diabetic retinopathy (DM-R) also showed significance when compared with control ($P < 0.01$) and with hypertensive retinopathy group II ($P < 0.05$) (**).

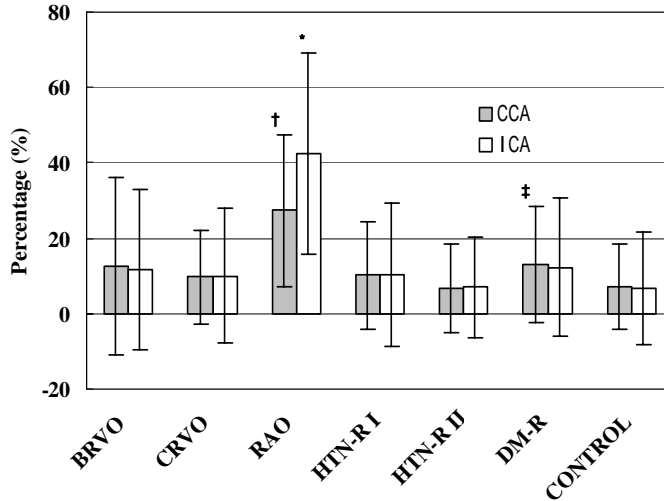


Figure 3. Representation of degree of stenosis between common and internal ipsilateral carotid artery. The common carotid artery was significantly stenotic in retinal artery occlusion (RAO) patients compared with control ($P < 0.01$), Hypertensive retinopathy group II (HTN-R II) ($P < 0.01$), and hypertensive retinopathy group I (HTN-R I) ($P < 0.05$) patients (†). The degree of stenosis also showed a significant difference for diabetic retinopathy patients (DM-R) compared with control ($P < 0.05$) (‡).

The degree of stenosis in the internal carotid artery showed a robust significance for RAO compared with Control ($P < 0.001$), branch retinal vein occlusion (BRVO) ($P < 0.001$), hypertensive retinopathy group I ($P < 0.001$), hypertensive retinopathy group II ($P < 0.001$), diabetic retinopathy ($P < 0.001$) and central retinal vein occlusion (CRVO) ($P < 0.01$)(*).

DISCUSSION

The present study found that the predictive value of fundoscopic findings of vascular retinopathies for identifying carotid artery atherosclerosis is variable. The distinction must be made between the different groups of patients presenting with ocular finding in terms of predictive value of the condition as well as the treatment. This will allow a more focused approach for determining which patients need a carotid ultrasound and which patients need to return to the neurosurgical clinic.

The presence of RAO and diabetic retinopathy was associated with significant carotid artery disease. Other eye fundoscopic findings, including BRVO and CRVO were not associated with significant carotid artery atherosclerosis. Hypertensive retinopathies showed somewhat contradictory results regarding to the carotid artery atherosclerotic progression and the degree of the retinopathy reported previously. (2)

Measurement of IMT of the carotid arteries was used to study the natural history of early phases of atherosclerotic changes of carotid artery. (1) The far-wall measurement is supposed to be more valid than its near-wall counterpart. However a recent study has shown that the CCA IMT is a good predictor of stroke incidence. (20) Our study confined IMT measurements to the CCA and confirmed that subjects with RAO and diabetic retinopathy showed a significantly increased carotid IMT. In the presence of another marker for carotid artery occlusive disease as plaque number and grading of stenosis, our results confirmed that both conditions correlated with carotid artery atherosclerotic progression.

Ultrasonographic evaluation of the carotid arteries demonstrated that subjects with RAO and diabetic retinopathy show high incidence of atherosclerotic progression and are more likely to experience a cerebral ischemic event during their lifetime. Patients with diabetic retinopathy make up the majority of clinical cases at risk because of their large number. In this study, RAO and diabetic retinopathy mainly affected the youngest population and are often asymptomatic in terms of their symptoms related to cerebral ischemia, both conditions may be more liable to be subject to cerebral ischemic risk. Peternel et al. have reported that three of 29 patients with RAO were found to have died of ischemic stroke when a follow-up study was conducted 5 years after they had been diagnosed with RAO. (22) Early detection through regularly scheduled ultrasound screening of atherosclerotic changes of the carotid artery would help determine the opportune time to take preventive measures.

A minority of patients with RAO represented the second youngest group after diabetic retinopathy, this finding is comparable with a previous study where this condition was detected in younger population. (25) Several investigators considered ischemic stroke, cerebral transient ischemic attacks (TIAs), amaurosis fugax or RAO manifestations of the same underlying disease. (12, 17) Our findings confirmed the presence of advanced stages of atherosclerosis throughout the carotid artery of patients with RAO. Mukherji et al. found in a retrospective study that 15 out of 24 of their patients with RAO had internal carotid artery stenosis. (18) Although we did not conduct a long-term follow up but in view of our findings, we stress the importance of such referrals for carotid ultrasound screening in order to prevent a subsequent ischemic stroke, and not restrict patient evaluation to solely to visual damage. This is of importance because RAO causes ocular symptoms, which frequently overlap those of carotid disease. (24)

Diabetic retinopathy is a highly specific vascular complication of both type 1 and type 2 diabetes mellitus, and the duration of diabetes is a significant risk factor for the development of this complication. (25) Some authors have examined the mechanisms contributing to changes in the retinal blood flow and to retinal vascular complications in diabetes and they demonstrated that the retinal blood flow is reduced in patients who have had diabetes more

CAROTID ULTRASONOGRAPHY AND VASCULAR RETINOPATHY

than 5 years. (5) Various metabolic and hormonal factors are suspected of being involved in the initiation and progression of retinal vascular abnormalities. The Diabetes Control and Complication Trial Research Group found that baseline level glycemic control significantly reduced the risk of onset and slowed down progression of diabetic retinopathy. (26) The study also demonstrated the positive effect of this control on the progression of other target organs, while a small but not statistically significant beneficial effect on large-vessel disease was noted. (26)

Our finding that IMT showed association with diabetic retinopathy is consistent with the findings of the Atherosclerosis Risk in Communities (ARIC) study (15) and a case-control study. (27) A most recent epidemiological study, which included 26,001 patients, also supported our finding. (23) However, the Cardiovascular Health Study (CHS) (14) did not show a relationship between early atherosclerosis and diabetic retinopathy. We found that diabetic retinopathy showed the second highest rate of carotid artery atherosclerosis progression, exceeded only by patients with RAO.

Although some risk factors are associated with the progression of both micro- and macroangiopathy in patients with diabetes, microangiopathy does not always progress simultaneously with macroangiopathy, and one type of diabetic angiopathy often worsens more rapidly than the other, that dissociation was reported in 30-40% of middle-aged Japanese type 2 diabetic patients with mean diabetes duration of 14 years. (30)

Patients with ocular sign of diabetic retinopathy need an initial screening carotid ultrasound examination. In fact, recent study provided direct evidence, at the vascular level, that atherosclerosis levels are elevated before the clinical onset of diabetes. (11)

Hypertensive retinopathies are related to the severity of the disease, the chronicity of its onset, the duration of symptoms, and the age of the patient. (13) Although not yet widely accepted, these factors are used for disease grading, and the difference between groups I and II of the Keith-Wagener-Baker classification represents the degree of sclerosis. (2) However, our carotid ultrasonographic screening showed conflicting findings for the atherosclerotic condition of the carotid artery's wall between patients in the HTN-R I and HTN-R II in terms of age distribution, IMT, plaque number and degree of stenosis. The HTN-R II group showed significantly lower average values for many variables when compared with HTN-R I.

The blood pressure is a significant independent factor in the progression of atherosclerotic carotid changes following diabetes, (6) but we found that patients with diabetic retinopathy show tendency to have a thicker IMT as well as a greater number of plaques than patients with hypertensive retinopathy, although there were no marked differences even after statistical adjustment in relation to other groups. Some investigators have found that the inclusion of subjects of a more advanced age may explain in part this apparent lack of concordance. (13) During neuro-ophthalmological examinations the classification of hypertensive retinopathy may have little clinical relevance because of difficulty for clinicians to estimate any advanced stages of atherosclerosis of the carotid wall on the basis of that classification.

Although the pathogenetic mechanism of carotid artery stenosis associated with BRVO and CRVO has not been fully established, previous reports have suggested that carotid disease leads to a diminished retinal circulation and subsequently venous stasis and thrombosis. (3, 9, 10) Statistical analysis of our results did not find a consistent influence of atherosclerotic carotid artery disease on patients with BRVO and CRVO as mentioned by McCullough et al., where four of their 5 patients provided a positive carotid scan. (16) We agree with some investigators who have proposed that retinal vein occlusion occurs in response to multifactorial pathogenesis instead of to simple mechanical factors and fluid

dynamics. (19) There is a conflicting evidence about the prevalence of the predictive value of retinal vein occlusion for carotid stenosis in the literature, while a retrospective study found as high as 75 % of their patient with retinal vein occlusion had ICA stenosis. (18) Other study have reported only a quarter of patients with retinal vein occlusion (9 of 33 patients) had evidence of carotid plaques on ultrasonography. (29) The differences between previous hypotheses and our results may be explained by the large number of elderly patients with the subclinical form of the disease, or because retinal vein occlusion is often associated with hypertension (21) and atherosclerosis. (4) The ocular findings exclusive of retinal vein occlusion were particularly poor predictor of carotid artery occlusive disease in our study.

In conclusion, the retinal vascular pathologies should not be considered as solitary lesion, but complementary to both a full general and a full neurological examination. Retinal vessel abnormalities and other clinical features observed in fundal assessment must be taken into account as well. Since RAO and diabetic retinopathy show association with asymptomatic carotid artery disease, both these entities should be closely followed up for early detection of carotid atherosclerosis progression as well as for intervention before a permanent neurological deficit can occur. On the other hand, the retinal vein occlusion group did not show association with carotid artery atherosclerotic progresion, so no benefit can be expected from further carotid screening. Although preventive measures to deal with the underlying systemic hypertensive disease is important, we did not find correlation between hypertensive retinopathy grading and atherosclerotic progression of carotid artery wall.

REFERENCES:

1. **Allan, P.L., Mowbray, P.I., Lee, A.J., and Fowkes, G.R.** 1997. Relationship between carotid intima-media thickness and symptomatic and asymptomatic peripheral arterial disease. The Edinburgh Artery Study. *Stroke* **28**:348-353.
2. **Breslin, D.J., Gifford, R.W., Fairbairn, J.F., and Kearns, T.P.** 1966. Prognostic importance of ophthalmoscopic finding in essential hypertension. *JAMA* **195**:334-338.
3. **Carter, J.E.** 1985. Chronic ocular ischemia and carotid vascular disease. *Stroke* **16**:721-728.
4. **Cassady, J.V.** 1953. Central retinal vein thrombosis. *Am J Ophthalmol* **36**:331-335.
5. **De la Rubia Sanchez, G., Oliver-Pozo, J., Shiba, T., and King, G.L.** 1991. Modulation of endothelin-1 (ET-1) receptor on retinal pericytes by elevated glucose levels. *Invest Ophthalmol Vis Sci* **32**:3110-3114.
6. **Delcker, A., Diener, H.C., and Wilhelm, H.** 1995. Influence of vascular risk factors for atherosclerotic carotid artery plaque progression. *Stroke* **26**:2016-2022.
7. **Dugan, J.D., and Green, W.R.** 1991. Ophthalmologic manifestation of carotid occlusive disease. *Eye* **5**:226-238.
8. **Feussner, J.R., and Matchar, D.B.** 1988. When and how to study the carotid arteries. *Ann Intern Med* **109**:805-818.
9. **Hayreh, S.S.** 1983. Classification of retinal vein occlusion. *Ophthalmology* **90**:458-474.
10. **Hayreh, S.S.** 1971. Pathogenesis of occlusion of the central retinal vessels. *Am J Ophthalmol* **72**:998-1011.
11. **Hunt, K.J., Williams, K., Rivera, D., O'Leary, D.H., Haffner, S.M., Stern, M.P., and Gonzalez Villalpando, C.** 2003. Elevated carotid artery intima-media thickness levels in individuals who subsequently develop type 2 diabetes. *Arterioscler Thromb Vasc Biol* **23**:1845-1850.
12. **Iwamoto, T., Matsushima, C., Shimizu, S., Takasaki, M., Iwasaki, T., and Usui, M.** 2002. Carotid ultrasonographic and brain computerized tomographic finding in patients

CAROTID ULTRASONOGRAPHY AND VASCULAR RETINOPATHY

- with vascular ocular syndromes (Article in Japanese). *No To Shinkei* **54**:119-125.
13. **Kim, S.K., Christlieb, A.R., Mieler, W.F., and Jakobiec, F.A.** 2000. Hypertension and its ocular manifestation, p.4506-4524. *In: Albert, D.M., Jakobiec, F.A., Azar, D.T., Gragoudas, E.S. (ed.), Principles and Practice of Ophthalmology.* W.B. Saunders Company, Philadelphia, USA.
 14. **Klein, R., Marino, E.K., Kuller, L.H., Polak, J.F., Tracy, R.P., Gottdiener, J.S., Burke, G.L., Hubbard, L.D., and Boineau, R.** 2002. The relation of atherosclerotic cardiovascular disease to retinopathy in people with diabetes in the Cardiovascular Health Study. *Br J Ophthalmol* **86**:84-90.
 15. **Klein, R., Sharrett, A.R., Klein, B.E., Moss, S.E., Folsom, A.R., Wong, T.Y., Brancati, F.L., Hubbard, L.D., and Couper, D., ARIC Group.** 2002. The association of atherosclerosis, vascular risk factors, and retinopathy in adults with diabetes: the Atherosclerosis Risk in Communities study. *Ophthalmology* **109**:1225-1234.
 16. **McCullough, H.K., Reinert, C.G., Hynan, L.S., Albiston, C.L., Inman, M.H., Boyd, P.I., Welborn, M.B. 3rd, Clagett, G.P., and Modrall, J.G.** 2004. Ocular findings as predictors of carotid artery occlusive disease: is carotid imaging justified?. *J Vasc Surg* **40**:279-86.
 17. **Mead, G.E., Lewis, S.C., Wardlaw, J.M., and Dennis, M.S.** 2002. Comparison of risk factor in patients with transient and prolonged eye and brain ischemic syndromes. *Stroke* **33**:2383-2390.
 18. **Mukherji, S., Kurli, M., and Sandramouli, S.** 2004. Indications and outcome of carotid Doppler ultrasound: an ophthalmic perspective. *Eur J Ophthalmol* **14**:240-244.
 19. **Ogawa, O., Onuma, T., Uchino, H., Takayanagi, Y., Tanaka, Y., Yamasaki, Y., Atsumi, Y., Matsuoka, K., and Kawamori, R.** 2003. Insulin resistance and atherosclerosis in branch retinal vein occlusion. *Jpn J Ophthalmol* **47**:351-355.
 20. **O' Leary, D.H., Polak, J.F., Kronmal, R.A., Manolio, T.A., Burke, G.L., and Wolfson, S.K.** 1999. Carotid-artery intima media thickness as a risk factor for myocardial infarction and stroke in older adults. *N Engl J Med* **340**:14-22.
 21. **Paton, A., Rubinstein, K., and Smith, V.H.** 1964. Arterial insufficiency in retinal venous occlusion. *Trans Ophthalmol Soc UK* **84**:559-586.
 22. **Peternel, P., Keber, D., and Videcnik, V.** 1989. Carotid arteries in central retinal vessel occlusion as assessed by doppler ultrasound. *Br J Ophthalmol* **73**:880-883.
 23. **Rema, M., Mohan, V., Deepa, R., and Ravikumar, R.** 2004. Chennai Urban Rural Epidemiology Study-2. Association of carotid intima-media thickness and arterial stiffness with diabetic retinopathy: the Chennai Urban Rural Epidemiology Study (CURES-2). *Diabetes Care* **27**:1962-1967.
 24. **Rumelt, S., Dorenboim, Y., and Rehany, U.** 1999. Aggressive systematic treatment for central retinal artery occlusion. *Am J Ophthalmol* **128**:733-738.
 25. **Streifler, J.Y., Eliasziw, M., Benavente, O.R., Harbison, J.W., Hachinski, V.C., Barnett, H.J.M., and Simard, D.** 1995. The risk of stroke in patients with first-ever retinal vs hemispheric transient ischemic attacks and high-grade carotid stenosis. North American Symptomatic Carotid Endarterectomy Trial. *Arch Neurol* **52**:246-249.
 26. **The Diabetes Control and Complications Trial Research Group.** 1993. The effect of intensive treatment of diabetes on the development and progression of long term complications in insulin-dependent diabetes mellitus. *N Eng J Med* **329**:977-986.
 27. **Visona, A., Lusiani, L., Bonanome, A., Beltramello, G., Confortin, L., Papesso, B., Costa, F., and Pagnan, A.** 1995. Wall thickening of common carotid arteries in patients affected by noninsulin-dependent diabetes mellitus: relationship to microvascular

- complications. *Angiology* **46**:793-779.
28. **Wong, T.Y., Klein, R., Sharrett, A.R., Schmidt, M.I., Pankow, J.S., Couper, D.J., Klein, B.E., Hubbard, L.D., and Duncan, B.B.** 2002. The ARIC Investigators. Retinal arteriolar narrowing and risk of diabetes mellitus in middle-aged persons. *JAMA* **287**:2528-2533.
 29. **Wong, T.Y., Larsen, E.K., Klein, R., Mitchell, P., Couper, D.J., Klein, B.E., Hubbard, L.D., Siscovick, D.S., and Sharrett, A.R.** 2005. Cardiovascular risk factors for retinal vein occlusion and arteriolar emboli: the Atherosclerosis Risk in Communities & Cardiovascular Health studies. *Ophthalmology* **112**:540-547.
 30. **Yamamoto, M., Egusa, G., Okubo, M., and Yamakido, M.** 1998. Dissociation of microangiopathy and macroangiopathy in patients with type 2 diabetes. *Diabetes Care* **21**:1451-1454.