

Radiofrequency Incision and Lay Open Technique of Pilonidal Sinus [Clinical Practice Paper on Modified Technique]

Pravin J. Gupta
*Department of Proctology,
Gupta Nursing Home
D/9, Laxminagar, Nagpur 440022, India*

Received 23 June 2003/ Accepted 26 September 2003

Key Words: Pilonidal sinus; Lay open technique; Radiofrequency; Recurrence

With the uncertainty as to the etiology and the complexities often encountered in its treatment, a pilonidal sinus has been considered as a tricky disease. Wide varieties of approaches are employed in dealing with this ailment ranging from a conservative treatment to an extensive surgical excision or repair. However, a method of simple lying open of pilonidal sinus is still considered as the favored one.

We describe a modified approach to the procedure of incision and lying open the sinus tracts. This retrospective study describes 18 patients of chronic pilonidal sinus treated with a technique of radiofrequency surgery under local anesthesia. There were 12 males and 6 females within an age group ranging from 16 to 30. The patients were subjected to a follow-up for a period of 18 months.

The patients were discharged on the same day of the procedure. Mean period off work was 7 days. The average healing time recorded was 67 days. Two wound complications in the form of premature closure of the skin edges were noted, requiring trimming of the edges. One of these two remained unhealed. At the last follow-up, no recurrence was found in the remaining 17 patients.

In the era when the emphasis is on the criteria like minimum hospital stay, less postoperative pain, early resumption to work and a reduced recurrence rate, there is a future to the procedure of incision and lying open of the pilonidal sinuses by using the radiofrequency wave.

Pilonidal sinus is a disabling nuisance in young adults, which can result in an abscess or draining sinus tracts, resulting in a long term loss of productive power and tends to have high rates of morbidity. It probably results from hair penetration beneath the skin and thus seems to be of an acquired origin. Despite advent of surgical therapy more than a century ago, an effective method of its management continues to remain debatable. Different approaches ranging from a conservative treatment (12) to an extensive surgical excision have been in practice for a long time.

Treatment options- The procedures presently advocated are-

1. Wide excision with closure of the defect by Z-plasty, rhomboid or myocutaneous advancement flaps.
2. Wide excision with healing by granulation.
3. Incision and lying open.

4. Marsupialization of the skin edges after excision.
5. Injection of phenol [Phenolization]. (6)
6. Cryosurgery.
7. Electrocauterization. (26)
8. Procedures using Nd-YAG (22) or Ruby lasers (15).

Spontaneous cure after discharge of the contents of some of the smaller sinuses have been reported. While all these treatment options are available, the consensus is that an ideal therapy should be simple to perform, inflict minimal pain and result in a short hospital stay. The wound care required should be minimum and simple to allow a quick return to normal activity and should have a low recurrence rate (11). The method of incision and lying open of pilonidal sinuses is found to meet most of these ideal goals (2).

Incision and lying open [sinotomy]- This procedure involves local excision of the midline sinuses, extending into the central cavity and laying open lateral tracts. Any hairs contained in the sinus are removed and wall of the cavity is scrapped free of granulations (9).

PATIENTS AND METHODS

The Incision and lay open [sinotomy] procedure is modified by us using the radiofrequency device to carry out the complete process. This retrospective study describes radiofrequency sinotomy in 18 patients with chronic pilonidal sinus. The procedures were carried out at Gupta Nursing Home, Nagpur, India between July 2000 and June 2001 and followed up till December 2002. There were 12 males and 6 females within the age group of 16 and 30.

The aim was to assess the effectivity of the modified procedure in terms of the operation time, period taken to resume routine activity, wound complications, time taken for complete wound healing and recurrence if any, in the follow-up period.

Patients having acute disease, those who had been previously operated for this pathology, those having more than 4 sinuses, and those who refused to sign the informed consent were excluded from the study.

An informed consent was obtained from all the patients under study. The study was approved by the local ethics committee and was carried out according to the declaration of Helsinki.

Radiofrequency surgery- It is a method by which cutting and coagulating of the tissues could be simultaneously achieved by using a high frequency alternate current. The effect of cutting, known as high frequency section, is executed without pressuring or crushing the tissue cells. This is possible on account of heat produced by tissue resistance to the passage of high frequency wave generated by the device. The heat makes the intracellular water boil, increasing the cell inner pressure to the point of breaking it from inside to outside [explosion]. This phenomenon is called as cellular Volatilization (24).

We used the radiofrequency generator known as Ellman dual frequency, [Ellman International, Hewlett, N.Y. USA] for our procedure. This instrument produces an electromagnetic wave of a very high frequency that reaches 4 megahertz. The unit is supplied with a handle to which different inter changeable electrodes could be attached according to the requirement. In this study, we used the ball electrode for coagulation, a round loop electrode for shaving the desired tissue and a fine needle electrode to open up the sinus tracts.

RADIOFREQUENCY PROCEDURE IN PILONIDAL DISEASE

PROCEDURE

The procedure was carried out under local anesthesia with the patient in a jack knife position. After shaving off the hairs around the sinuses and cleaning the area with Povidone Iodine, the subcutaneous tissues were infiltrated with 5-12 ml of a solution of 2% Xylocain and Adrenalin [1:200000].

Methylene blue dye mixed with hydrogen peroxide was injected in one of the external opening to give a guideline about the tract and branching. A probe was inserted in the tract and with the help of the fine needle electrode the tract was opened over the length of the probe. When two or more sinus openings were found joining each other, the fistula tract and the skin between them were incised by the needle electrode.

The occasional brisk bleeding encountered was held in the hemostat and coagulated with the ball electrode. Any hairs and foreign material if found, were removed. All the tracts were traced and the infected and indurated tissue was shaved off with the round loop electrode leaving behind a red, raw area. No attempt was made to deepen the dissection up to the post sacral fascia and a layer of tissue was left between the floor of the wound and the sacrum & coccyx. Care was taken that the wound should acquire a shape of an inverted cone, wide externally and narrow internally. This prevented premature closure of the external skin wound.

The wound was tucked with paraffin gauze and was then covered with a padded adhesive dressing. An intravenous dose of 1gm of Ceftriaxone was administered immediately after the procedure.

Postoperative care- Patients were encouraged to mobilize soon after the procedure. No oral antibiotics were prescribed. They were asked to take a combination of Diclofenac sodium 50mg and Serratiopeptidase 10 mg twice a day for first five days after the procedure and then as and when they felt pain.

All of them were discharged on the evening of the procedure and were called at a one-week interval. Twice daily cleaning of the wound with soap and application of an antiseptic cream was found sufficient to take care of the wound. A weekly inspection of the wound helped in keeping a close watch on possible wound complications like infection and premature skin closure (29).

RESULTS

The number of sinuses in each patient ranged from 1 to 3 with a mean of 2. Most of them were placed on either side of the sacrum. Discharge from the sinus and pain were the two main complaints. Half the number of patients had bleeding and pruritus. All the patients were observed till the wound bridged completely and the findings were noted.

Table I. Patient demographic and pre treatment symptoms.

Age	23* years [6.4]
Male: Female	12:6
Duration of Disease	24* months [2.7]
Discharge	14
Pain	11
Pruritus	7
Bleeding	2

*Values are mean [SD].

In two patients, wound-healing disturbance was faced due to premature closure of the external wound, which required slitting open the wound and trimming of the edges. The wound thereafter, healed uneventfully in one patient but failed to heal in the other. This was labeled as a 'failure of wound healing' rather than a case of recurrence.

No recurrence was observed in any of the remaining patients at a minimum follow up of 18 months.

Precautions while using radiofrequency device- Deep dissection could cause more scarring and consequently a longer time for healing. An excessive power of the unit would cause more smoke and charring. Incidences of accidental burns either on the patient or operator due to unintended activation of hand piece have been reported. A deft handling of the device eliminates the possibility of such contingencies.

DISCUSSION

In spite of high incidence of pilonidal disease affecting young population and the prolonged disabling period caused by it, surgeons have not reached to a unanimity about the best treatment for this condition (20).

The advocates of excision and primary closure of the wound using different techniques emphasize on quicker healing time, fewer postoperative visits and shorter time off work (23) (4) (3).

Those favoring simple excision or lay-open technique, are of the opinion that if general patient satisfaction, period of hospitalization and the recurrence rate are the criteria, then their's was a far better method than the other complex procedures (18) (27) (14).

However, it has been reported that the chances of infection are much higher in the wounds created by excision and suturing (19). Incidences of wound dehiscence following excision and primary repair are much more than previously

thought (31) (16). These procedures also require a long hospital stay and long periods off work (5).

Since the radiofrequency procedure of incision and lay open practiced by us can be easily performed in local anesthesia, the need for hospitalization is obviated. In comparison to all the other procedures described, the period off work was the shortest after our procedure (2) (23) (4).

We encouraged the patients to return to their normal activity as soon as possible because it was observed that the wounds healed more quickly in those patients who resumed their normal routine before the closure of the wound (21).

There is no denial that the number of visits needed and the time taken for the wound healing was significantly more in the technique used by us when compared with the excision and primary repair procedures. But considering the complexity of these extensive procedures, period of hospital stay, consumption of inpatient hospital resources, need of antibiotics and the need to repeat procedure in case of wound dehiscence or complications, the advantages of the procedure developed by us do outweigh the other procedures. This is particularly so in a developing country like India which is struggling to provide better health care to its masses.

The technique was found suitable in patients having limited, chronic pilonidal sinus disease with active symptoms like pain, discharge, bleeding and pruritus. Most of the patients operated were young adults.

Nd: YAG (22) and Ruby lasers have been used in treating pilonidal disease and are reported to reduce pain, length of hospitalization and early return to work similar to the procedure conducted by us with the radiofrequency device. The radiofrequency instrument

RADIOFREQUENCY PROCEDURE IN PILONIDAL DISEASE

has many advantages of the laser without the attending disadvantages like the risk of misdirected reflected beams, the prolonged healing period involved and the high cost of treatment (10).

The radiofrequency device allows cutting and coagulation of tissues in an atraumatic manner, contrary to the electric bistoury. The advantages of radiofrequency over electrocautery and laser energy surgery reside in its precision in ablating tissues and in its control of operation. With radiofrequency, the targeted tissue temperatures stay localized within a 60-90°C range thus limiting heat dissipation and damage to adjacent tissue. In contrast, electrocautery, diathermy, and laser temperatures are significantly higher (750-900°C) which result in significant heat propagation in excess of the desired therapeutic need. These differences allow for radiofrequency being found more accurate, minimally invasive and less morbid without compromising the treatment efficacy and durability (24).

While techniques using conventional scalpel apparently works in an atraumatic way, the prominence of bleeding from the wound forces the surgeon to coagulate the bleeders with traditional electrocautery or diathermy more frequently than radiofrequency. The radio waves can seal the small blood vessels without creating any char, whereas the cautery or elctrosurgical instruments create heat at the tip of the instruments to seal the affected portion with transferred heat, and in the process invariably damage the adjacent healthy tissues, (25) which consequently cause more edema and postoperative pain.

Malleable electrodes are available with the unit that could be selected for the exacting requirements of any surgical position (8). This is especially found of great help when working on a cavity of the disease with presence of offending tissues. The radiofrequency tool can easily clean these crevices.

The cost of radiofrequency procedure is limited to the acquisition of the radiofrequency generator (approximately US \$ 1800 for the basic unit), which does not require any recurring maintenance except the normal care during its handling and use. The running cost of the instrument is negligible.

Our results are comparable to other surgical procedures of pilonidal sinus viz. marsupialization, excision and primary closure, skin flaps, W-plasty closure, marsupialization and collagenase dressing, Laser sinotomy, and excision and healing by granulation techniques.

Table II. Comparative results of radiofrequency pilonidal sinotomy and other techniques of pilonidal sinus surgery.

Findings	Our series	Other series
Hospital Stay	6-13 hrs	5.95 ³ –26.5 ¹⁷ days (Skin flaps- W-plasty closure)
Procedure Time	10-19 minutes	30 ²² -120 ¹⁷ minutes (Laser- W-plasty closure)
Period off Work	4-10 days	17 ³ -28 ¹⁸ days (Marsupialization-Excision & open)
Wound Healing time	42-75 days	22 ¹ -168 ³⁰ days (Marsupialization with collagenase dressing- Excision)
Failure of Treatment	5.5% patients	9.1% ⁴ patients (Excision and primary closure)
Recurrence	Nil	24 ¹⁹ - 42 ¹³ % (Excision and primary closure)
Wound Infection	None	3.6 ⁷ - 14 ²⁸ % (Excision and primary closure)

CONCLUSION

An ideal treatment of pilonidal sinus disease is one which aims at, reducing hospital stay, minimizing tissue assault by avoiding unduly extensive procedures with the attendant complications, early resumption of work by the patient and preventing recurrence of the disease.

Incision and lying open of the sinuses by using the radiofrequency device seems to fulfill most of the above parameters. The procedure could very well be done as a day care procedure. There is less tissue trauma, pain and inflammation, and the patient can return to his routine within a short duration of time.

Our study size and follow-up was no doubt small to draw a definitive and authoritative conclusion. There is a need to conduct more such controlled and randomized studies to confirm the advantage of the radiofrequency technique over the other conventional procedures. We, however, feel that the initial results of the radiofrequency lay open technique of the pilonidal sinus disease are encouraging.

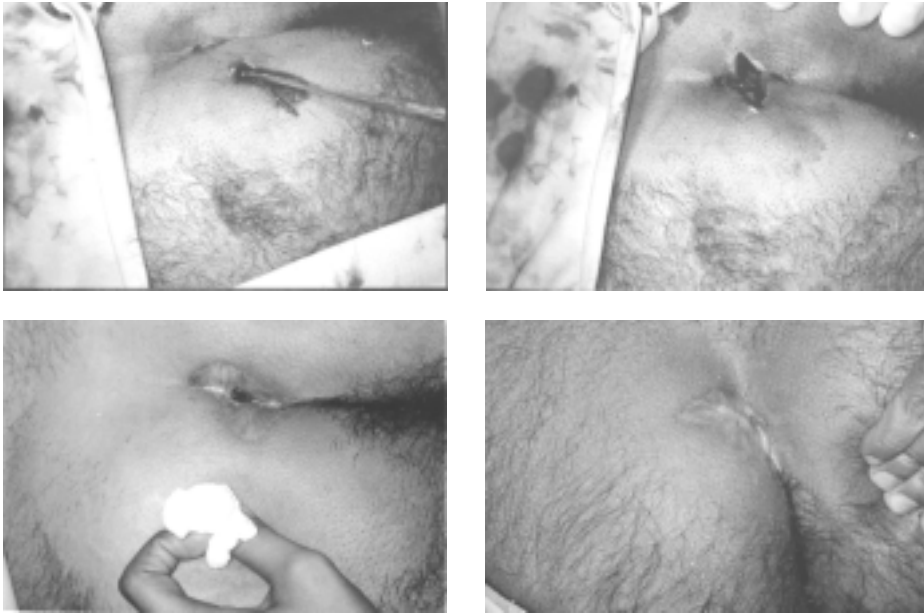
REFERENCES

1. **Aldemir M, Kara IH, Erten G, Tacyildiz I.** 2003. Effectiveness of collagenase in the treatment of sacrococcygeal pilonidal sinus disease. *Surg Today* **33**: 106-109.
2. **Al-Homoud SJ, Habib ZS, Abdul Jabbar AS, Isbister WH.** 2001. Management of sacrococcygeal pilonidal disease. *Saudi Med J* **22**: 762-764.
3. **Aydede H, Erhan Y, Sakarya A, Kumkumoglu.** 2001. Comparison of three methods in surgical treatment of pilonidal disease. *Aust N Z J Surg* **71**: 362-364.
4. **Chiedozi LC, Al-Rayyes FA, Salem MM, Al-Haddi FH, Al-Bidewi AA.** 2002. Management of pilonidal sinus. *Saudi Med J* **23**: 786-788.
5. **Destito C, Romagnoli A, Pucello D, Mercuri M, Marin AW.** 1997. Pilonidal sinus: long term results of excision and closure technic. Review of the literature. *G Chir* **18**: 441-446.
6. **Duchateau J, De Mol J, Bostoen H, Allegaert W.** 1985. Pilonidal sinus. Excision--marsupialization--phenolization? *Acta Chir Belg* **85**: 325-328.
7. **Fuzun M, Bakir H, Soylu M, Tansug T, Kaymak E, Harmancioglu O.** 1994. Which technique for treatment of pilonidal sinus- open or closed? *Dis Colon Rectum* **37**: 1148-1150.
8. **Goldberg SN, Gazelle GS, Dawson SL, et.al.** 1995. Tissue ablation with radiofrequency: effect of probe size, gauge, duration and temperature on lesion volume. *Acad Radiol* **2**: 399-404.
9. **Goligher J, Duthie H, Nixon H.** 1992. Pilonidal sinus. p. 230-233. In *Surgery of the anus rectum and colon*. 5th ed. Bailliere Tindall, London.
10. **Hofmann A, Wustner M, Ciric B.** 1996. Radiowave Surgery Case Report. *Int J Aest Rest Surg* **4**: 131-133.
11. **Hull TL, Wu J.** 2002. Pilonidal disease. *Surg Clin North Am* **82**: 1169-1185.
12. **Hurst DW.** 1984. The evolution of management of pilonidal sinus disease. *Can J Surg* **27**: 603-605.
13. **Iesalniaks I, Furst A, Rentsch M, Jauch KW.** 2003. Primary midline closure after excision of a pilonidal sinus is associated with a high recurrence rate. *Chirurg* **74**: 461-468.
14. **Isbister WH, Prasad J.** 1995. Pilonidal disease. *Aust N Z J Surg* **65**: 561-563.
15. **Lavelle M, Jafri Z, Town G.** 2002. Recurrent pilonidal sinus treated with epilation using a ruby laser. *J Cosmet Laser Ther* **4**: 45-47.

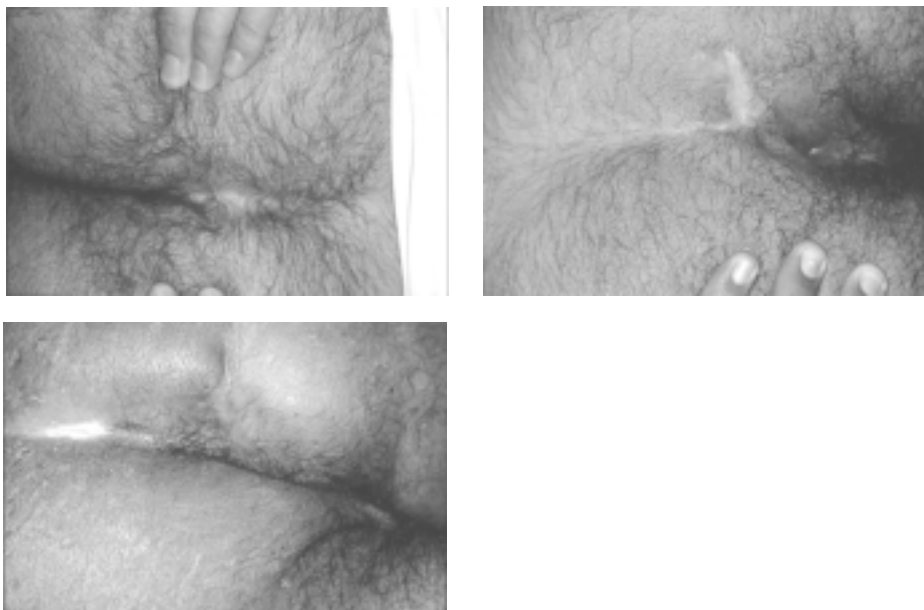
RADIOFREQUENCY PROCEDURE IN PILONIDAL DISEASE

16. **Lee HC, Ho YH, Seow CF, Eu KW, Nyam D.** 2000. Pilonidal disease in Singapore: clinical features and management. *Aust N Z J Surg* **70**: 196-198.
17. **Manabu Kudaka.** 1999. Surgical treatment for pilonidal sinus: a fourteen year experience. In *The 45th annual congress of ICS-JS*. Tokyo, Japan.
18. **Menzel T, Dorner A, Cramer J.** 1997. Excision and open wound treatment of pilonidal sinus. Rate of recurrence and duration of work incapacity. *Dtsch Med Wochenschr* **122**: 1447-1451.
19. **Miocinovic M, Horzic M, Bunoza D.** 2000. The treatment of pilonidal disease of the sacrococcygeal region by the method of limited excision and open wound healing. *Acta Med Croatica* **54**: 27-31.
20. **Nahas SC, Sobrado Junior CW, Araujo SE, Imperiale AR, Habr-Gama A, Pinotti HW.** 1997. Results of the surgical treatment of non-complicated pilonidal disease. *Rev Hosp Clin Fac Med Sao Paulo* **52**: 287-290.
21. **Ortiz HH, Marti J, Sitges A.** 1977. Pilonidal sinus: a claim for simple track incision. *Dis Colon Rectum* **20**: 325-328
22. **Palesty JA, Zahir KS, Dudrick SJ, Ferri S, Tripodi G.** 2000. Nd: YAG laser surgery for the excision of pilonidal cysts: a comparison with traditional techniques. *Lasers Surg Med* **26**: 380-385.
23. **Perruchoud C, Vuilleumier H, Givel JC.** 2002. Pilonidal sinus: how to choose between excision and open granulation versus excision and primary closure? Study of a series of 141 patients operated on from 1991 to 1995. *Swiss Surg* **8**: 255-258.
24. **Pfenninger JL, DeWitt DE.** 1994. Radiofrequency surgery. p 91-101. In Pfenninger JL Fowler GC (ed.). *Procedures for primary care physicians*. Mosby. St.Louis.
25. **Saidi MH, Setzler KR, Farhart SA, Akright BD.** 1994. Comparison of office loop electro-surgical conization and cold knife conization. *J Am Asso Gynecol laparosc* **1**:135-139.
26. **Shafik A.** 1996. Electrocauterization in the treatment of pilonidal sinus. *Int Surg* **81**: 83-84.
27. **Sondenaa K, Nesvik I, Andersen E, Soreide JA.** 1996. Recurrent pilonidal sinus after excision with closed or open treatment: result of a randomised trial. *Eur J Surg* **162**: 237-240.
28. **Spivak H, Brooks VL, Nussbaum M, Friedman I.** 1996. Treatment of chronic pilonidal disease. *Dis Colon Rectum* **39**: 1136-1139.
29. **Surrell JA.** 1994. Pilonidal disease. *Surg Clin North Am* **74**: 1309-1315.
30. **Viciano V, Castera JE, Medrano J, Aguilo J, Torro J, Botella MG, Toldra N.** 2000. Effect of hydrocolloid dressings on healing by second intention after excision of pilonidal sinus. *Eur J Surg* **166**: 229-232.
31. **Zieger K.** 1999. Complications after surgery for pilonidal cyst. An introduction to a new debate on a "costly" disease. *Ugeskr Laeger* **161**: 6056-6058.

ADDITIONAL DATA



Case I. Probe in the sinus tract (upper left). After incision and lay opening of the sinus tracts (upper right). Follow up wound healing (lower left). Completely healed wound (lower right).



Healed wounds of pilonidal sinuses. Case II (upper left), Case III (upper right), and Case IV (lower).