

# Cadaveric and Clinical Study of Endoscope-assisted Microneurosurgery for Cerebral Aneurysms Using Angle-type Rigid Endoscope

YOSHIYUKI TAKAISHI, HARUO YAMASHITA,  
and NORIHIKO TAMAKI

*Department of Neurosurgery, Kobe University Graduate School of Medicine*

Received 14 December 2001/ Accepted 10 January 2002

**Key words:** endoscope; aneurism surgery; microneurosurgery

**Highly advanced optical equipment enables endoscopic surgery to be performed in neurosurgery. We developed an angle-type rigid endoscope having an angled shaft, and has performed endoscope-assisted surgery in neck clipping of 50 cerebral aneurysms.**

Anatomical study concerning the perforating branch was made through a pterional approach using 3 cadavers. By using endoscope, we can observe the posterior communicating artery and anterior choroidal artery behind the internal carotid artery without retract the internal carotid artery and the surrounding structures. Furthermore IIIrd–VIIIth cranial nerve in opposite side and basilar artery in the posterior fossa can be observed.

As the clinical study, we used endoscope in 50 clipping of cerebral aneurysms (29 Internal carotid artery aneurysms, 6 anterior communicating artery aneurysms, 2 anterior cerebral artery aneurysms, 7 middle cerebral artery aneurysms, 5 vertebral artery-posterior inferior cerebellar artery aneurysm, and basilar bifurcation aneurysms). The endoscopic image showed in incomplete clipping in 2 cases, where additional clipping was then performed. In all subject, complete clipping was performed using both microscopic and endoscopic view.

Use of the angle-type rigid endoscope together with Doppler ultrasound, should increase the feasibility of complete clipping procedure, resulting in reduced complication rate.

Results in treating cerebral aneurysms have dramatically improved since the introduction of microscopic surgery. Still, the morbidity and mortality rates in surgically treating unruptured aneurysms are said to be about 4% and 1%, respectively. Constriction and occlusion of perforating branches and arterial branches peripheral to aneurysmal lesions caused by the surgery is accounted as one major cause. In some situations, retraction of the parent artery, or of the aneurysmal dome may be required for identifying the perforating branch in clipping the aneurysm, because the perforating branch is in a blind spot due to the main artery or aneurysm itself. Retraction of the main artery or aneurysm can lead to damaged vascular flow, arterial injury, and rupture of the aneurysm during the operation. Clipping an aneurysm without ascertaining the environs leads to insufficient preservation of the penetrating artery, increasing the morbidity and mortality rate.

There have been many reported cases in which endoscope-assisted microsurgery was used as an auxiliary measure in neurosurgery for performing safer aneurysm surgery.<sup>(2-4, 7, 9, 13)</sup> Our facility has developed an angle-type rigid endoscope having an angled shaft, and has performed endoscope-assisted microsurgery.<sup>(12)</sup> The authors carried out studies in cadavers

on reliability and direct visibility range in identifying the perforating branch, and report anatomical evaluations and clinical results, along with a bibliographical discussion.

### MATERIAL AND METHODS

Anatomical studies concerning the perforating branch and arterial branch were made, and the usable range with endoscopes was investigated, through a pterional approach using 3 cadavers. For the pterional approach, based on the Yasargil *et al.*<sup>(14)</sup> method, the heads were rotated about 30 degrees to perform frontotemporal craniotomies, followed by drilling of the sphenoidal ridge and dural incisions. Initially, an endoscope having a view angle of 30 degrees was introduced through the lateral space of the internal carotid artery to examine the artery branching from the lateral of the internal carotid artery, and advanced further to the posterior fossa of the cranial cavity to determine the visible range.

Endoscope-assisted surgery was performed on 50 subjects (47 cases of cerebral aneurysms) who underwent cerebral aneurysmal surgery at the Department of Neurosurgery, Kobe University Hospital between April 1994 and March 2001. The ages of the subjects average 59.6 years (33-81 years). Among these subjects, 16 were males and 31 females: 47 individuals had unruptured aneurysms (among whom for 1 individual it was complicated by a ruptured aneurysm), and 3 individuals had ruptured aneurysms that were Hunt and Kosnik grade II.

Aneurysmal regions: internal carotid artery aneurysms, 29 cases; anterior communicating artery aneurysms, 6 cases; anterior cerebral artery aneurysms, 2 cases; middle cerebral artery aneurysms, 7 cases; vertebral artery-posterior inferior cerebellar artery aneurysms, 5 cases; and basilar bifurcation aneurysms, 1 case (Table I). Operations were performed on these aneurysm cases under endoscopic visualization to ascertain the perforating arteries, verify clipping, and investigate complications in terms of endoscopic use.

Table I . Location of cerebral aneurysms.

ICA aneurysm	
IC-PC aneurysm	11
IC-Ach aneurysm	5
Paraclinoid aneurysm	10
IC anterior wall aneurysm	2
IC-bifurcation aneurysm	1
A-com aneurysm	6
Distal ACA aneurysm	1
A1 aneurysm	1
MCA aneurysm	7
Basilar bifurcation aneurysm	1
VA-PICA aneurysm	5
Total	50

Rigid endoscopes (outer diameter: 2.7mm, fields of view: 0, 30 and 80 degrees, manufactured by Machida Co. Ltd.), having bodies angled at 110 degrees so that in microsurgery the operational field is not obstructed (Fig. 1), were brought out and have been used since 1997<sup>(12)</sup>.

Two methods are employed: wherein bimanual surgical manipulations are performed utilizing both microscopic and endoscopic screens, with the endoscope fixed with a fixing

## ANGLE-TYPE RIGID ENDOSCOPE USING ANEURYSM SURGERY




Fig. 1. Angle-type rigid endoscopes which have a angle of  $110^\circ$  in its shaft. Viewing directions are 0, 30, and 80 degree.




Fig. 2. Intraoperative view that the operator inserted the endoscope into the operative field.

device (Fig. 2); and wherein the endoscope is introduced before/after clipping, and-without pitting excess pressure on brain tissues, cranial nerves, cerebral blood vessels or cerebral aneurysms-conditions surrounding the aneurysms are observed and whether clipping is complete is verified.

### RESULTS

Wherein a pterional approach is carried out assisted by microscopic imaging, the posterior communicating artery and anterior choroidal artery are in the blind spot of the carotid artery. In many cases, retraction of the internal carotid artery or dome of the aneurysm is often required during the clipping procedure. Cadavers were used to investigate whether the endoscope may be utilized to detect the dorsal internal carotid artery without retraction of the internal carotid artery or aneurysm. With an endoscope having view angle of 30 degrees inserted through the lateral side of internal carotid artery heading frontward, the posterior aspect of internal carotid artery was observed. The endoscopic images facilitated clear discrimination of the posterior communicating artery and the anterior choroidal artery branching from the posterior surface of the internal carotid artery, as well as other perforating arteries, which are difficult to discriminate (Fig. 3) with microscopic imaging. Endoscopes with a view angle of 70 degrees can produce disorientation, and therefore endoscopes with a view angle of 30 degrees were considered most useful.

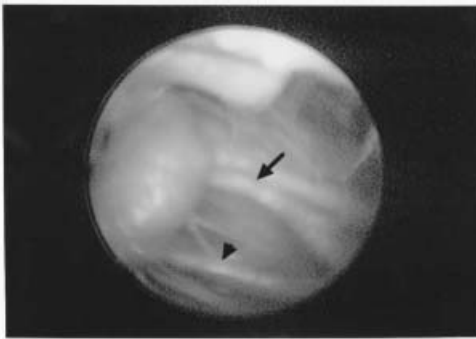


Fig. 3. (left) Endoscopic view showed the perforating artery including posterior communicating artery and anterior choroidal artery behind the internal carotid artery.

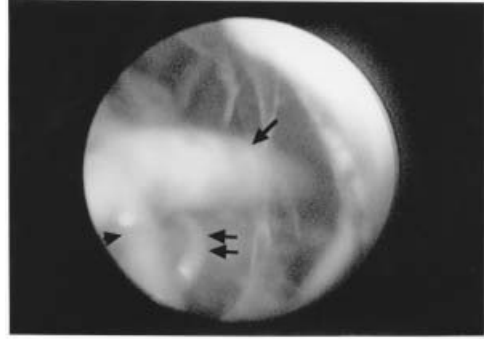


Fig. 4. (right) Endoscopic view showed the basilar artery, bilateral posterior cerebral arteries, and superior cerebellar arteries.

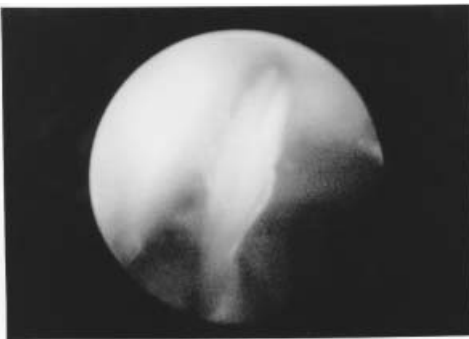


Fig. 5. (left) The Vth nerve of the opposite side was observed in endoscopic view through the Meckel's cave.

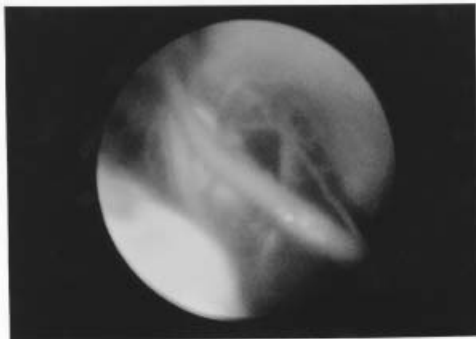


Fig. 6. (right) The VII VIII complex was observed in endoscopic view where can not be observed in the microscopic view.

## ANGLE-TYPE RIGID ENDOSCOPE USING ANEURYSM SURGERY

The range accessible through the pterional approach includes aneurysms of the Sylvian fissure hypothalamus, third ventricle, optic chiasm, and aneurysms of the skull base, as well as lesions of the cavernous sinus. Additional operations (i.e. drilling of the posterior clinoid process and dissection of the tentorium cerebri) are required on aneurysms of the low positioned basilar bifurcation or lesions of the basilar trunk.<sup>(6)</sup> Inserting the endoscope toward the posterior cranial fossa, sufficiently enables, without dissection of the tentorium cerebelli, detection of not only of the perforating branches from the basilar artery, posterior cerebral artery superior cerebellar artery basilar artery trunk (Fig. 4) and the oculomotor nerve, but also detection of contralateral V (Fig. 5) VII/VIII complex and flocculus (Fig. 6). With some types of endoscopes, textures present in the posterior cranial fossa can also be detected under direct sight. Detection of ipsilateral textures, however, is considered difficult owing to the insertion orientation, while the contralateral structures, however, is considered difficult owing to the insertion orientation, while the contralateral textures are easily detected.

In clinical cases, an endoscope with a view angle of 30 degrees was introduced frontward into 9 internal carotid artery-posterior communicating artery, and internal carotid artery-anterior choroidal artery aneurysms among clinical cases with internal carotid artery aneurysms. As a result, the relation between the aneurysms and the branched arteries was clearly established, and in 1 case indicated that the posterior communicating artery aneurysm was preserved, although the clipping position was shallow, confirming that the clipping procedure was incomplete (Fig. 7, 8 and 9). Additional clipping surgery resulted in complete success. Thus the pterional approach seems to be advantageous in detecting posterior communicating arteries and anterior choroidal arteries hidden by an internal carotid arteries and aneurysms.

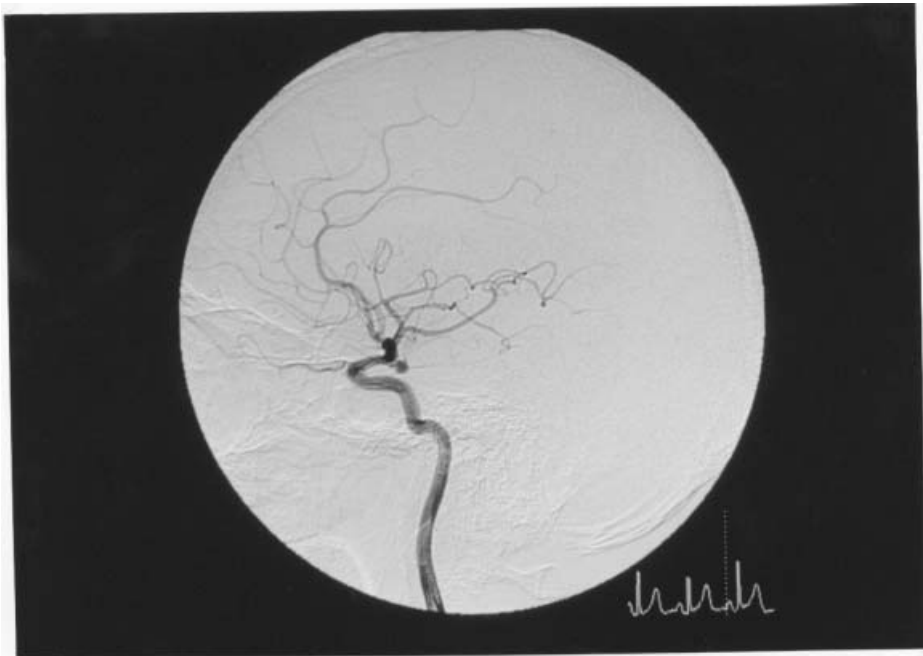

Fig. 7. Lt. carotid angiogram showed Lt. IC-PC aneurysm.

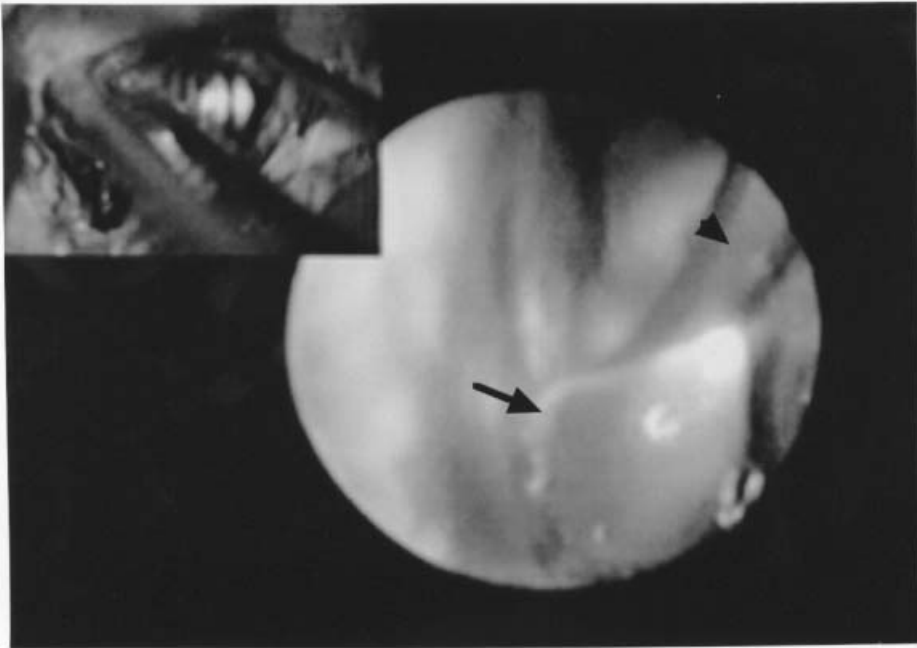

Fig. 8. Endoscopic view showed Lt. IC-PC aneurysm, internal carotid artery and clip.

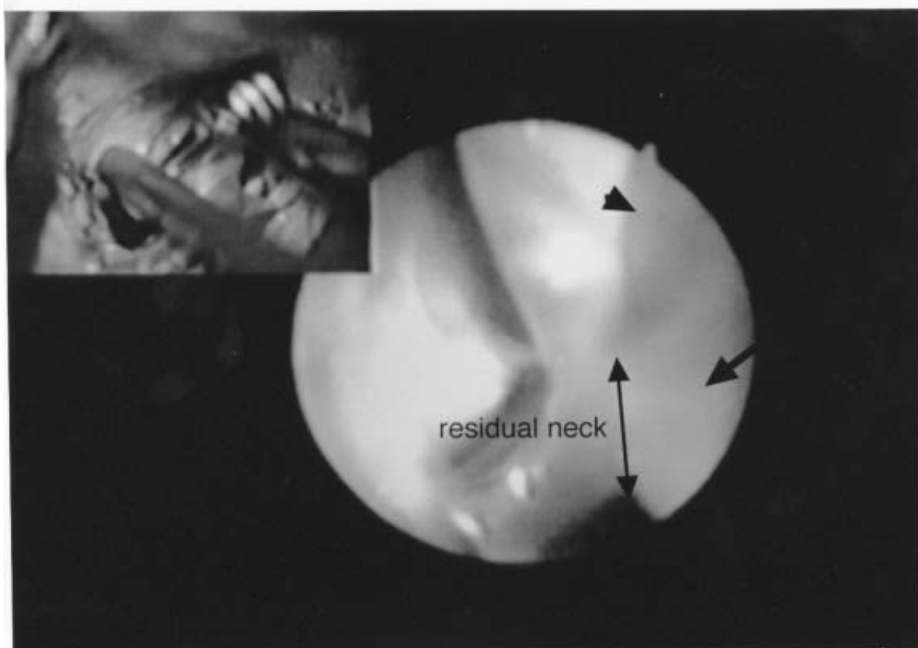


Fig. 9. Endoscopic view showed incomplete clipping of Lt. IC-PC aneurysm.

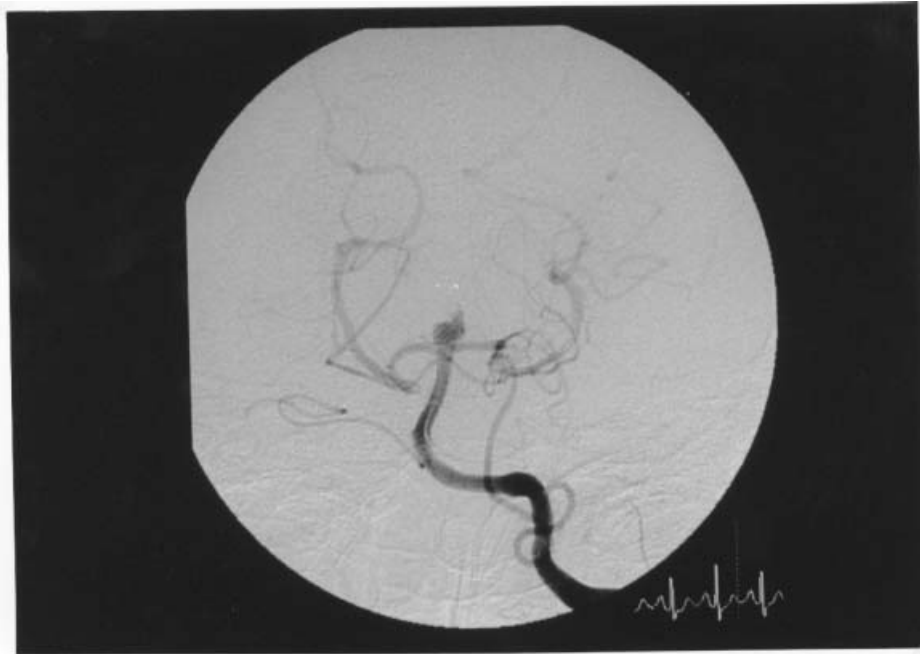

Fig. 10. Lt. vertebral angiogram showed basilar bifurcation aneurysm.

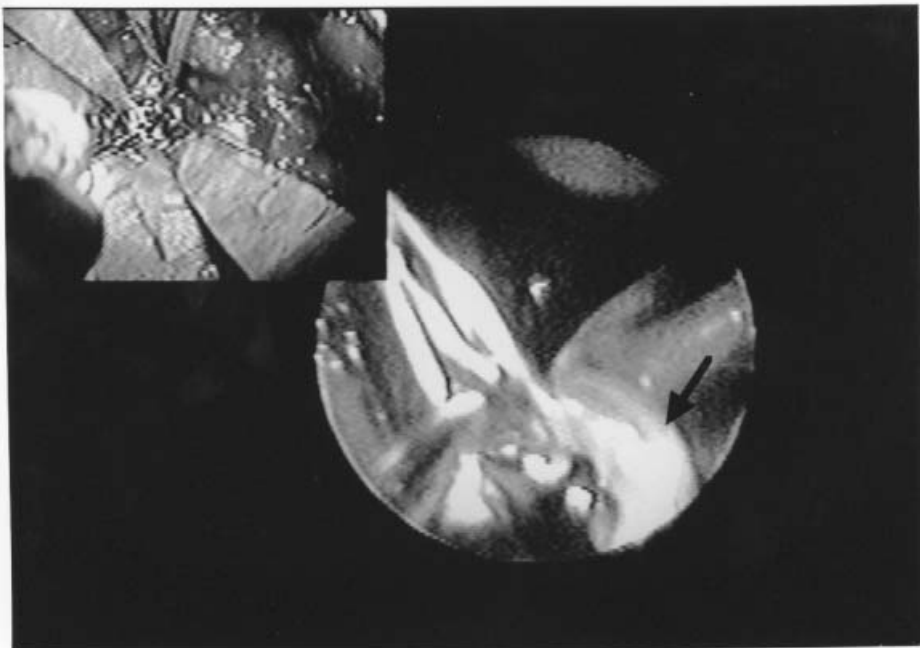


Fig. 11. Intraoperative endoscopic view in the clipping of basilar artery aneurysm showed the complete clipping sparing the Rt. posterior cerebral artery.

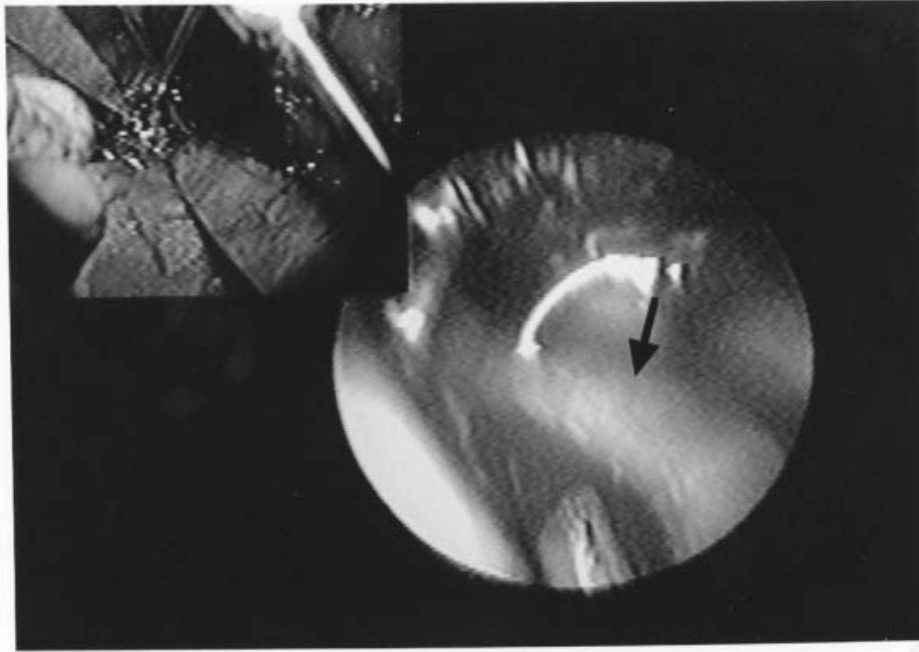


Fig. 12. Endoscopic view showed no stenosis of the posterior cerebral artery in the opposite side.

Cases of posterior fossa aneurysm are few. Basilar bifurcation aneurysms were located at very shallow depths and the microscope can provide sufficiently clear images. Upon insertion of the endoscope subsequent to clipping, however, the posterior cerebral artery, superior cerebellar artery and basilar artery trunks located at on the opposite side could be detected in their entirety, confirming that the neck clipping surgery was completely achieved (Fig. 10, 11 and 12).

Relatively clear visual fields were obtained in the case of unruptured aneurysms, while frequent irrigation was required for clear fields in subarachnoid bleeding cases, due to soiling of the endoscope tip. Thus, development of irrigation system is considered necessary.

This series of endoscopes allow us in nearly all cases to perform neck clipping while preserving the perforating arteries. Transient neurological symptoms developed in 2 out of 47 cases (4%), which were relieved with time, resulting in independent gait and discharge.

A comparative study was done on surgical results for 32 unruptured aneurysm cases who underwent clipping before endoscopes were used, and 47 unruptured aneurysm cases who underwent clipping in which the endoscope was used. With the endoscope not-used group, CT scans showed low density area in 6 of 32 cases (19%), and neurological symptoms developed in 4 of 32 cases (12%). Comparing with the results for unruptured aneurysms assisted by the endoscope suggests the possibility that using the endoscope improves the results aneurysm surgery (Table II).

Complication from inserting the endoscope, for example, premature rupture were recognized in particular.



## ANGLE-TYPE RIGID ENDOSCOPE USING ANEURYSM SURGERY

Table II . Results of the clipping of the unruptured cerebral aneurysms.

	Without Endoscope	With endoscope
Case number	32	47
Mean Age	62.2	59.6
GOS		
GR	29 (90%)	47 (100%)
MD	3 (9%)	0
Low density area on CT	6 (19%)	3 (6%)
Transient neurological deficit	1 (3%)	2 (4%)
Permanent neurological deficit	3 (9%)	0

### DISCUSSION

Endoscope have been increasingly used also in neurosurgery. The operations are classified into endoscopic surgery conducted under endoscopic visualization, and endoscope-assisted microsurgery in which the endoscope is used to assist microscopic imaging. In particular, endoscopes are frequently used during aneurysm and tumor resections. Fisher et al. reported the first study on application of the endoscope in aneurysms surgery in which structure around the aneurysm were detectable during fiberscope-assisted aneurysm surgery, contributing to reduced time for temporary clipping. However, disadvantage with the fiberscope were pointed out: 1)Image quality is poor compared with rigid endoscope, 2) Keeping its position constant is difficult.<sup>(1)</sup>

Rigid endoscopes are less flexible than fiberscope, and therefore require a viewing angle for surgical procedures. On the other hand, rigid endoscopes have advantages in that they provide high image quality, and make bimanual procedures possible, provided that an anchoring device is used. In general, endoscopic system consist of a light guide and CCD camera, enabling images to appear on a television monitor. However, the CCD camera or cable often appears in the microscopic images and interfere with the microscopic field during the endoscope-assisted microsurgery. In order to eliminate this defect, Tamaki had the body of the endoscope angled at 110 degrees so that the CCD camera and cable would appear away from the microscopic field<sup>(12)</sup>.

This allowed the endoscope to provide sufficient microscopic visual field. Furthermore, even if fixed the endoscope did not disturb surgical operations, which enabled bimanual surgical procedures to be performed.

In aneurysm surgery, subsequent to dissection the subarachnoid space and the structures around the aneurysm under the microscope, the endoscope is inserted to identify the aneurysm underside: Area hidden by the aneurysm or parent artery must be identified before neck clipping. Then, the endoscope is introduced again to confirm that the clipping is perfect and the perforating arteries remains preserved. In this situation, extreme caution must be taken to prevent the possibility of the aneurysm rupturing due to inserting the endoscope under limited-space condition. The authors spend the most time using the endoscope mainly for post-clipping verification: The endoscope was used to confirm imperfect clipping following the clipping procedure in 2 cases, and enabled complete clipping to be carried out. In addition, complications cases by insertion of the endoscope, in particular, premature rupture were not detected. Used for surgery on various aneurysms, the endoscope is considered to be useful particularly on internal carotid artery aneurysms and basilar bifurcation aneurysms. Since the internal carotid artery is present in the carotid cistern, which has sufficient space for insertion, used of the endoscope is relatively safe. Gibo et al.<sup>(5)</sup>

report the posterior communicating artery is branched from the posteromedial surface of the internal carotid artery, posterior surface, posterolateral surface at percentages of 44, 33, and 22%, respectively, indicating that the posterior surface accounts for much of the branching. Furthermore, the posterior communicating artery runs posteromedially. Because the anterior choroidal artery also branches from the posterolateral aspect and posterior aspect at percentages of 66 and 28%, respectively and then runs posteriorly, compression of the aneurysms or internal carotid artery is require for microscopic observation. The internal carotid artery itself is difficult to retract, and in some cases, the origins of the posterior communicating artery perfuse the major tissues including the tuber cinereum, interpeduncular fossa, mamillary bodies, visual pathway, cerebral peduncle, thalamus, hypothalamus, and the posterior limb of the internal capsule. The anterior choroidal artery perfuses the optic tract, cerebral peduncle, temporal lobe, lateral geniculate bodies.<sup>(5,8,10 11)</sup> Occlusion of the these tissues may often develop serious symptoms and thus those textures necessarily must be preserved, particularly in the case of unruptured aneurysms. The origins of those arteries are discernible with the endoscope, enabling safe and reliable clipping procedures.

Basilar bifurcation aneurysms are present deep in the brain, which limits the visual views regardless of the orientation of the microscope. In endoscope-assisted study using cadavers, the general pterional approach also provided very precise images of the posterior cerebral artery, the superior cerebellar artery and basilar bifurcation, as well as the middle and lower basilar arteries not detectable even with a microscope, and the contralateral cranial nerve. An endoscope with a view angle of 0 degrees was able to provide images of the posterior cerebral artery, basilar artery, and perforating arteries that are present on the opposite side, to verify that clipping procedures were complete.

Following the combined use of clipping, microscope and endoscope, the patency of the parent artery was detected using Doppler ultrasound. As a result, complete clipping was achieved in all the cases. Use of the angle type rigid endoscope together with Doppler ultrasound, then should increase the feasibility of complete clipping procedures, resulting in reduced complication rates.

**REFERENCES**

1. **Fischer J and Mastafa H.** 1994. Endoscopic-guided clipping of cerebral aneurysms. *Br J Neurosurg* **8**:559-565.
2. **Fries G and Perneczky A.** 1998. Endoscope-assisted brain surgery: part 2-analysis of 380 procedures. *Neurosurgery* **42**:226-232.
3. **Frazee JG and King WA.** 1998. Endoscopy and stereotaxy for aneurysms *Neurosurgery clinics of North America* **9**:869-878.
4. **Fujimoto S, Kusaka N, and Adachi Y.** 1997. Endoscopy-assisted microscopic operation for cerebral aneurysm. *Surg Cereb Stroke (Jpn)* **25**:293-299.
5. **Gibo H, Lenkey C, and Rhoton Al Jr.** 1981. Microsurgical anatomy of the supraclinoid portion of the internal carotid artery. *J Neurosurg* **55**:560-574.
6. **Kobayashi S and Okudera H.** 1990. Clinical anatomy of the pterional approach with special references to its limitation. *Surgical anatomy for microneurosurgery III*:21-27.
7. **Perneczky A.** 1998. Endoscope-assisted microsurgery for cerebral aneurysms. *Neurol Med Chir Supple (Tokyo)* **38**:33-34.
8. **Pedroza A, Dujovny M, and Artero JC.** 1987. Microsurgical anatomy of the posterior communicating artery. *Neurosurgery* **20**:228-235.
9. **Perneczky A and Fries G.** 1998 Endoscope-assisted brain surgery: Part I-evolution, basic concept, and current technique. *Neurosurgery* **42**:219-225.
10. **Rhoton AL Jr, Fujii K, and Fradd B.** 1977. Microsurgical anatomy of the anterior choroidal artery. *Surg Neurol* **12**:171-187.
11. **Saeki N and Rhoton AL Jr.** 1977. Microsurgical anatomy of the upper basilar artery and the posterior circle of Willis. *J Neurosurg* **46**:563-578.
12. **Tamaki N, Hara Y, Takaishi Y, and Shimada S.** 2001. Angled rigid neuroendoscope for continuous intraoperative visual monitoring: technical note. *J Clin Neuroscience* **8**:148-150.
13. **Taniguchi M, Takimoto H, and Yoshimine T.** 1999. Application of rigid endoscope to the microsurgical management of 54 cerebral aneurysms: results of in 48 patients. *J Neurosurg* **91**:231-237.
14. **Yasargil MG.** interfascial pterional (Frontotemporosphenoidal) craniotomy: 1984. *Microneurosurgery.* Georg Thieme Verlag Stuttgart, New York., pp215-233.