

IMMUNOLOCALIZATION OF CYTOKINES AND GROWTH FACTORS IN SUBACROMIAL BURSA OF ROTATOR CUFF TEAR PATIENTS

Hiroshige SAKAI, Kenji FUJITA, Yoshitada SAKAI,
and Kosaku MIZUNO

Department of Orthopaedic Surgery, Kobe University School of Medicine

KEY WORDS

subacromial bursa; rotator cuff tear; cytokines; immunohistochemical staining

ABSTRACT

Inflammation in the subacromial bursa causes pain in patients suffering from rotator cuff tear, with this long-lasting inflammation leading to fibrosis and thickening of the subacromial bursa. Both inflammatory cytokines and mechanical stress, and impingement in the subacromial space, might induce and worsen this inflammation. However, little is known of the mechanism of this inflammation. In this study, we used immunohistological staining to demonstrate the expression of Interleukin-1 (IL-1), Tumor necrosis factor (TNF- α), transforming growth factor (TGF- β), and basic fibroblast growth factor (bFGF) in subacromial bursa derived from the patients suffering from rotator cuff tear. On the other hand the expression of these inflammatory cytokines and growth factors were little detected only to a small degree in patients with anterior shoulder instability who did not have severe shoulder pain and impingement in the subacromial space. Our findings suggest that those inflammatory cytokines and growth factors may play an important role in inflammation of the subacromial bursa. Controlling the expression of these cytokines and growth factors might be important for treating patients suffering from shoulder pain due to rotator cuff tear.

INTRODUCTION

Complaints suffered by patients who experience rotator cuff tear are various: limitation of range of motion, Loss of muscle power of rotators, pain in the shoulder. Among these, shoulder pain is the key and if this pain can be controlled, the limitation of range of motion or the weakness of rotators will be minimized in most patients. The question arises as to the origin of this pain. Considering that about 10 to 20% Of the normal population over the age of sixty has rotator cuff tear,^{*3} or that conservative treatment, in which the tear will be remain, is effective for more than half of the patients, the tear itself seems not to be painful. On the other hand, the subacromial bursa in patients with rotator cuff tear usually shows severe synovitis compared to that in patients with anterior shoulder instability who don't have shoulder pain. These findings suggest that shoulder pain of the rotator cuff tear is due to inflammation in the subacromial bursa.

Little is known regarding the mechanism of inflammation in subacromial bursa, though mechanical stress and inflammatory cytokines as well as growth factors could induce and worsen this inflammation. In the present study, we examined the expression of inflammatory cytokines and growth factors in the subacromial bursa of patients suffering from rotator cuff tear by using immunohistochemical staining, and compare the results to those of patients suffering from anterior shoulder instability.

MATERIALS AND METHODS

Tissue sources

Subacromial bursa was obtained at the time of surgery from fourteen patients (ten men, four women) undergoing repair of rotator cuff tear. Informed consent was obtained from each patient. Age at the time of operation was ranged from 33 to 76 years (average; 55 years). For comparison, we also obtained subacromial bursa from patients who showed no impingement sign preoperatively and no inflammation.

Immunohistochemical staining

Tissue of the subacromial bursa taken from the surgical specimens was embedded in OCT tissue-embedding medium (Tissue Tek; Miles, Elkhart, IN, U.S.A.) and frozen in liquid nitrogen. Eight micrometer-thick frozen sections were cut onto glass microscope slides. Immunohistochemistry was performed using standard immunoperoxidase techniques. The slides were air-dried and then fixed with 100% acetone at 4°C for 5 minutes. Endogenous peroxidase activity was quenched for 5 minutes using a 3% hydrogen peroxide in phosphate-buffered saline

CYTOKINES AND GROWTH FACTORS IN SUBACROMIAL BURSA

(PBS) solution, after which the slides were rinsed three times in PBS. Cellular antigens were determined by an indirect immunoperoxidase staining technique using monoclonal antibodies which included monoclonal anti-human interleukin-1 β antibody, anti-human TNF- α antibody, anti-human bFGF antibody, and anti-human TGF- β antibody (Table 1). Indirect immunoperoxidase staining was performed using a Histofine SAB-PO Kit (Nichirei, Tokyo, Japan). Briefly, this method consisted of incubating the primary monoclonal antibody and SAB in a humidified chamber at 20°C for 1 hour. The excess antibody was removed by washing with PBS. The second antibody, biotinylated anti-mouse immunoglobulin . Or anti-rabbit immunoglobulin., was added, and samples were incubated for 10 minutes, followed by incubation for 25 minutes in avidin-biotin-peroxidase complexes. We detected the intensity of staining of anti- human IL- 1., anti-human TNF- α , anti-human bFGF antibody, and anti-human TGF- . antibody in the section under a light microscope.

The tissue sections were examined for specific staining in the cells, matrix, and vessels of both groups. Cellular staining was graded as positive if specific staining was seen in both slides for a given antibody and as negative if no staining or only rare cellular staining was evident. Positive matrix staining was recorded if pericellular staining was evident in more than 50% of the cells per medium-power field ($\times 200$) and if there was an absence of any background staining in the matrix in the negative control sections. Positive staining around blood vessels was recorded if staining could be observed in more than 50% of the blood vessels per medium-power field ($\times 200$).

Table I. Indirect immunoperoxidase staining was performed using these antibodies.

Cytokines	Species	Company
IL-1 β	Mouse Anti-Human IL-1 β	Genzyme
TNF- α	Rabbit Anti-Human TNF- α	Genzyme
bFGF	Mouse Anti-Human bFGF	Promega
TGF- β	Mouse Anti- TGF- β 1,2,3	Genzyme

RESULTS

Hematoxylin-Eosin staining of subacromial bursa

Figure 1 displays the frozen sections of subacromial bursa stained with hematoxylin-eosin from the patients of the rotator cuff (SAB-RCT) group and one from patients with anterior instability of the shoulder (SAB-AI).

Marked villi-like formations and hyperplasia of the fibroblast and blood vessels are visible in SAB-RCT sections (Fig. 1A) as compared to sections from SAB-AI (Fig. 1B). Both sections have no eosinophil infiltration.

Immunohistochemical staining

Figure 2A displays the frozen sections of subacromial bursa stained with an antibody to IL-1. from the patients of the SAB-RCT group. Diffuse staining for IL-1. is visible around the blood vessels (arrow) and underlying the cells that compose the inner surface of the subacromial bursa (open arrow). Focal staining for TNF- α is visible in the cells from the patients of the SAB-RCT group (Figure 2B arrow). Diffuse staining for bFGF is also visible in the area of hyperplasia of cells and vessels from the patients of the SAB-RCT group (Figure 2C arrow). Linear staining for TGF- β is visible in the cells from the patients of the SAB-RCT group (Figure 2D arrow).

Expression of cytokines and growth factors in cytoplasm of fibroblast in subacromial bursa

All of the cytokines and growth factors that we evaluated were expressed more frequently in the patients in the SAB-RCT group as compared to those of the SAB-AI group. The frequency of IL-1., TNF- α , bFGF, and TNF- β in the SAB-RCT group was 93%, 86%, 86%, and 86%, respectively. On the other hand, those in the SAB-AI group were IL-1.; 50%, TNF- α ; 17%, bFGF; 33%, and TGF- β .; 0%(Fig.3A).

Expression of cytokines in vessels

The percentage of patients in the SAB-RCT group showing positive staining of IL-1., TNF- α , bFGF, and TGF- β . was 86%, 79%, 78%, and 50%, respectively. On the other hand, the frequency of positive staining in the SAB-AI group was IL-1. ; 34%, TNF- α ; 33%, bFGF; 67%, and TGF- β .; 33% (Fig. 3B).

Expression of cytokines and growth factors in extra-cellular matrix

There was a trend toward a greater frequency of definite staining for TGF- β . in the matrix from patients of the SAB-RCT group than in that from individuals in the SAB-AI group. No positive staining for the other cytokines and growth factors was seen in either group.

CYTOKINES AND GROWTH FACTORS IN SUBACROMIAL BURSA

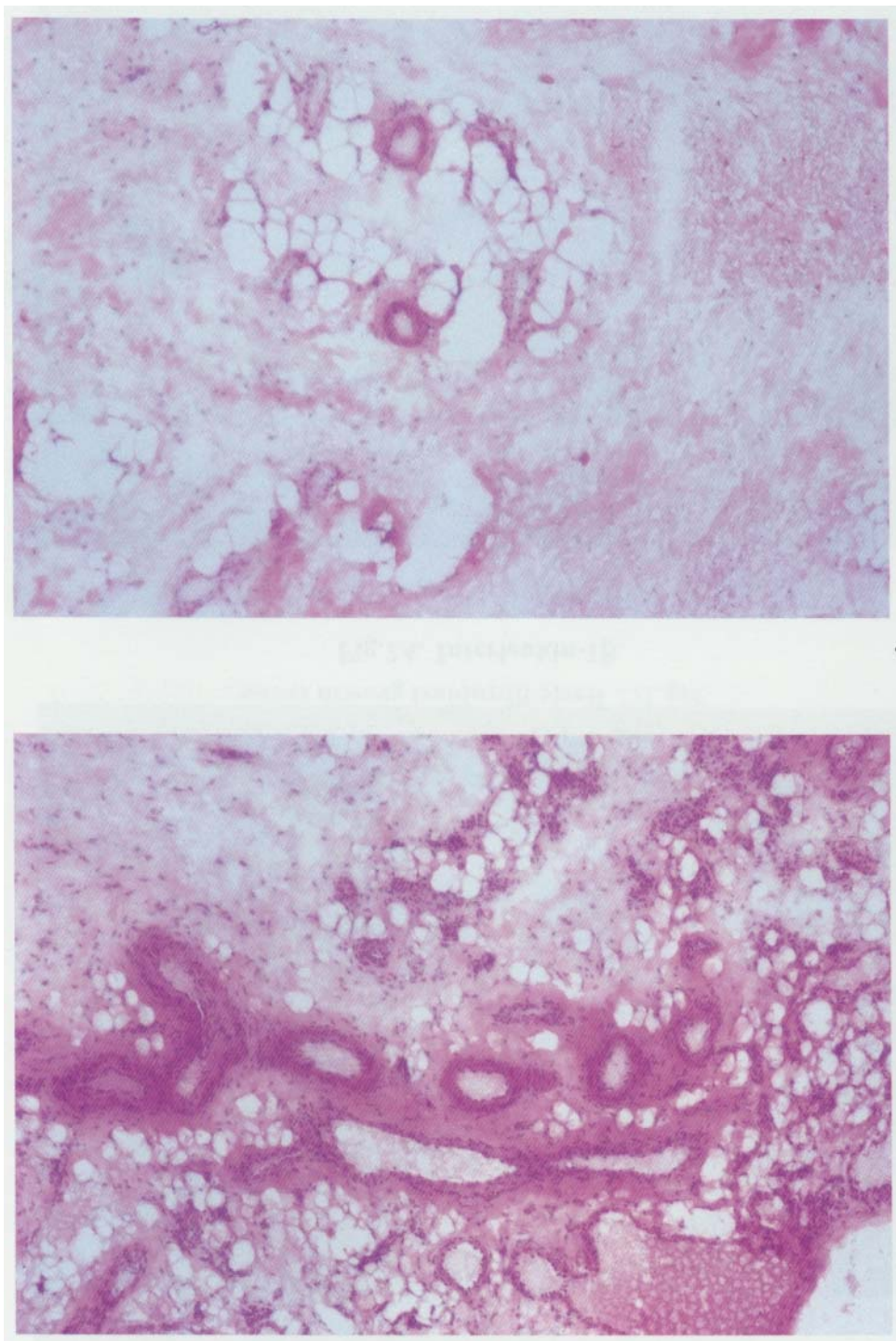


Fig.1. Histological sections of the subacromial bursa (hematoxylin and eosin, $\times 200$).
A: Subacromial bursa of the patients with rotator cuff tear.
B: Subacromial bursa of the patient with anterior shoulder instability that dose not have impingement sign preoperatively and no inflammation.

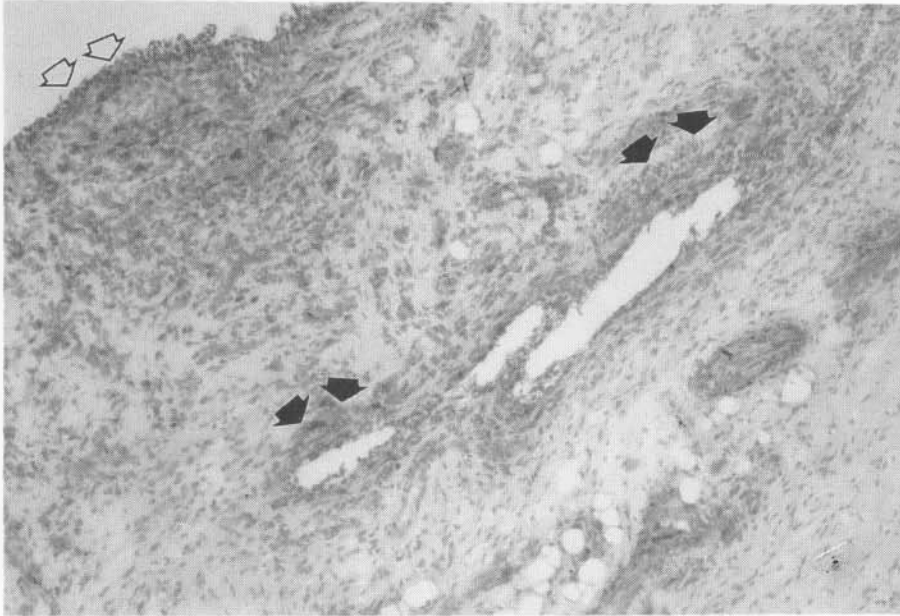


Fig.2A. Interleukin-1 β .

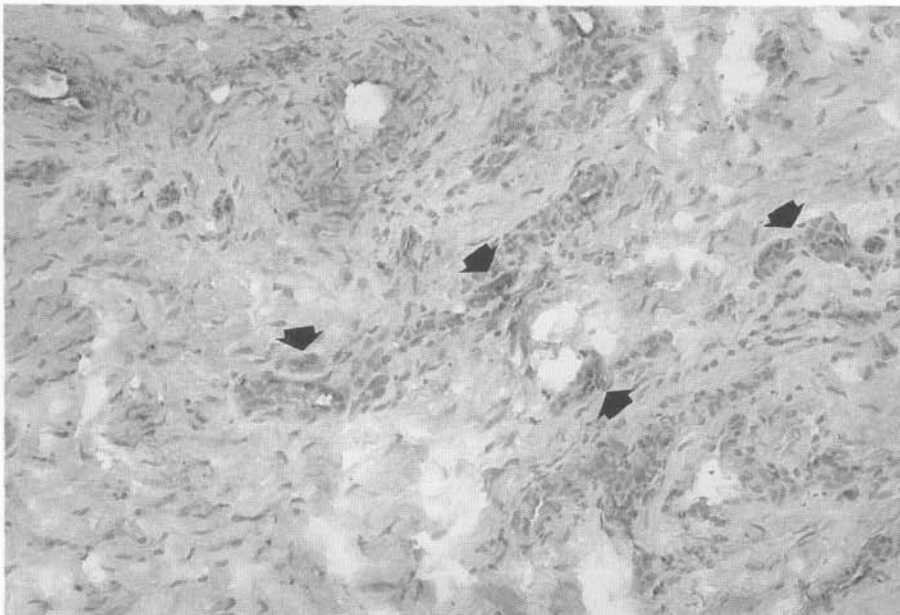


Fig.2B. Tumor necrosis factor α .

CYTOKINES AND GROWTH FACTORS IN SUBACROMIAL BURSA

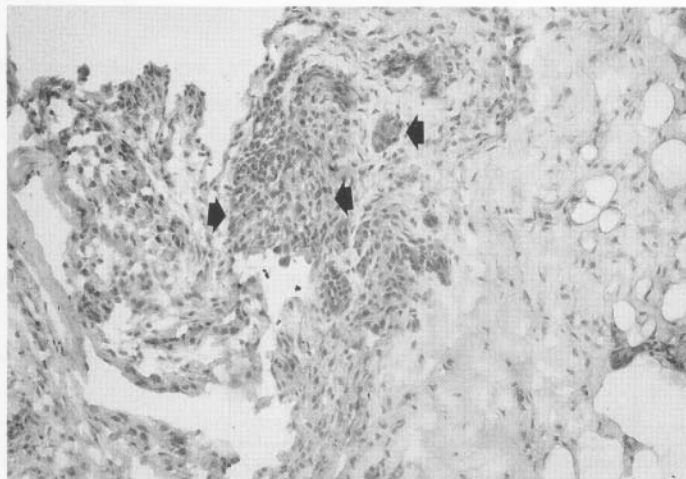


Fig.2C. Basic fibroblast growth factor.

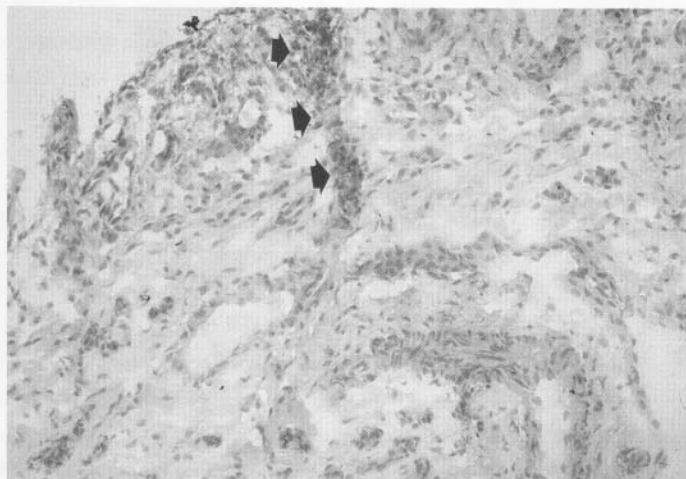


Fig.2D. Transforming growth factor β .

Fig.2. Frozen sections of shoulder subacromial bursa of rotator cuff patient stained with an antibody to A; interleukin-1. (IL- 1.), B; tumor necrosis factor α (TNF- α), C; basic fibroblast growth factor (bFGF), and D; transforming growth factor. (TGF- β .)

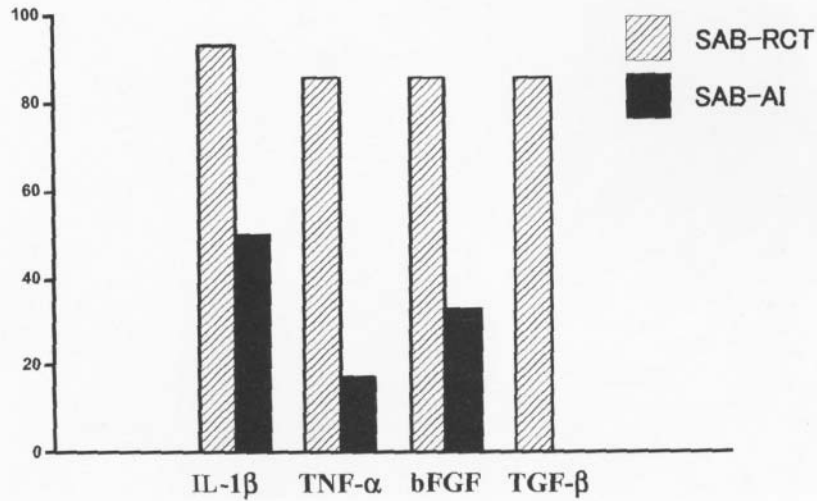


Fig.3A.Cytokine staining in cytoplasm of fibroblast in subacromial bursa.

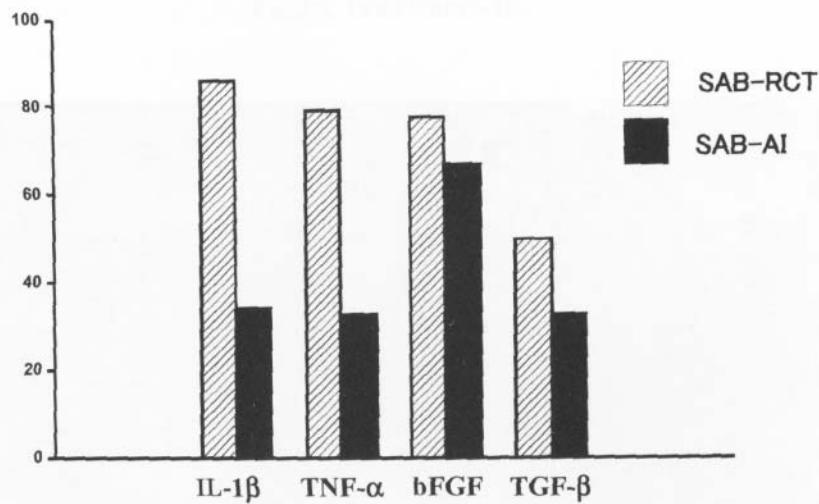


Fig.3B. Cytokine staining in subacromial vessels.

ig.3. Graph demonstrating the frequency of positive staining for each cytokines.

IL-1β = interleukin-1β, TNF-α = tumor necrosis factor, bFGF = basic fibroblast growth factor, TGF-β = transforming growth factor β.

SAB-RCT : subacromial bursa from the patients of rotator cuff tear

SAB-AI : subacromial bursa from the patients of the anterior instability of the shoulder

CYTOKINES AND GROWTH FACTORS IN SUBACROMIAL BURSA

DISCUSSION

It has been reported that inflammatory cytokines and growth factors such as IL-1, TNF- α , bFGF, or TGF- β play an important role in inflammation during wound healing by enhancing cell proliferation or production of extra cellular matrix in various types of cells.¹⁶ IL-1 and TNF- α have been reported to induce pain via cyclooxygenase-2 (COX-2) expression, resulting in the production of prostaglandins (PGs).² On the other hand, bFGF has been reported to be one of the main factors promoting proliferation of endothelial cells, which results in neovascularization.⁹ Furthermore, TGF- β has been detected in the synovial cells of rheumatoid arthritis, and administration of this cytokine and growth factor into the joint has been seen to induce arthritis in a mouse model.¹⁰ Therefore, the coexistence of these cytokines and growth factors for a long period leads to pain and fibrosis of the tissue.¹ In the patients suffering from rotator cuff tear inflammation in subacromial bursa is one of the main cause of their pain. However there is no report concerning the expression of inflammatory cytokines and growth factors in subacromial bursa. In this study, we demonstrated the expression of those cytokines and growth factors in the subacromial bursa of the patients with rotator cuff tear, and that these expressions were detected more frequently in these patients than in those with anterior shoulder instability. Although the average age of the patients with rotator cuff tear was much higher than that of those with anterior shoulder instability, it is hard to believe that aging itself induces the expression of these cytokines and growth factors in the subacromial bursa. We consider that the more frequent expression of cytokines and growth factors is one aspect of the pathology of rotator cuff tear.

We had reported the significant relationship between neovascularization and clinical shoulder pain in patients experiencing rotator cuff tear.⁸ However, in the present study we could not demonstrate a significant relation between the expression of cytokines and growth factors and clinical symptoms. This is because the population of patients in this study was relatively uniform. They all experienced severe shoulder pain and limitation in their range of motion. If we could operate on the patients who have mild pain or mild limitation of range of motion, we might be able to demonstrate the relation between the expression of cytokines and growth factors and clinical symptoms.

From our data, it is suggested that inflammatory cytokines and growth factors expressed in the subacromial bursa of the patients with rotator cuff tear might induce pain and fibrosis, following the hypertrophy of the bursa itself. This fibrosis and hypertrophy may disturb the sliding mechanism of bursa, resulting the contracture of the shoulder joint. Furthermore, the hypertrophic bursa may worsen the impingement in the subacromial space.

Generally speaking, cytokines and growth factors perform various functions, and these functions could be both physiological and pathological. Therefore, we cannot assert that the

expression of IL-1, TNF- α , bFGF, or TGF- β in the subacromial bursa is pathological. However, considering that those expressions were found only in small degrees in the one in the patients with anterior shoulder instability, they play some role in inflammation of subacromial bursa. Controlling the expression of these cytokines and growth factors might be the key to treating patients with rotator cuff tear.

ACKNOWLEDGMENTS

This paper was presented at the 25th Annual Meeting of the Japan Shoulder Society at Tokyo, October 29th-30th, 1998.

REFERENCES

1. Border, WA. and Noble, NA. 1994. Transforming growth factor beta in tissue fibrosis. *N. Engl. J. Med.* 33 1(19): 1286- 1292.
2. Crofford, LJ. 1997. COX-1 and COX-2 tissue expression: implications and predictions. *J. Rheumatol.* 49 (Suppl.): 15-19.
3. DePalma. AF. JB Lippincott. 1973. *Surgery of the shoulder.* 2nd ed. Philadelphia.
4. Gotoh, M., Hamada, K., Yamakawa, H., Inoue, A., and Fukuda, H. 1998. Increased substance P in subacromial bursa and shoulder pain in rotator cuff diseases. *J. Orthop. Res.* 16(5):618-621.
5. Kronberg, M. and Saric, M. 1997. Fibrosis in the subacromial bursa and outcome after acromioplasty. *Ann. Chir. Gynaecol.* 86(1):45-49.
6. Livne. E. 1994. In vitro response of articular cartilage from mature mice to human transforming growth factor beta. *Acta Anom. at (Basel).* 149(3): 185-194.
7. Rahme, H., Nordgren, H., Hamberg, H., and Westerberg, CE. 1993. The subacromial bursa and the impingement syndrome. A clinical and histological study of 30 cases. *Acta Orthop. Scand.* 64 (4) :485-488.
8. Terashita, T., Fujita, K., Iwasaki, Y., and Mizuno. K. 1995. The histological findings of subacromial bursa of the rotator cuff tear. *J. Orthop. Traumat.* 38 (6) : 1707-1708.
9. Thornton, SC., Por, SB., Penny, R., Richter, M., Shelley, L., and Breit. SN. 1991. Identification of the major fibroblast growth factors released spontaneously in inflammatory arthritis as platelet derived growth factor and tumor necrosis factor-alpha. *Clin. Exp. Immunol.* 86 (1) :79-86.
10. Van Beuningen. HM., Glansbeek, HL., van der Kraan, PM., and van den Berg, WB. 2000. Osteoarthritis-like changes in the murine knee joint resulting from intra-articular transforming growth factor-beta injections. *Osteoarthritis Cartilage.* 8 (1) :25-33.