

## Treatment of Subungual Glomus Tumor

HIROYUKI FUJIOKA, TAKESHI KOKUBU, TOSHIHIRO AKISUE,  
ISSEI NAGURA, NARIKAZU TOYOKAWA, ATSUYUKI INUI,  
RYOSUKE SAKATA, and MASAHIRO KUROSAKA

*Department of Orthopedic Surgery, Kobe University Graduate School of Medicine, 7-5-1  
Kusunoki-cho, Chuo-ku, Kobe, 650-0017, Japan.*

Received 18 December 2008/ Accepted 19 January 2009

**Key Words:** finger, subungual, glomus tumor, high-resolution MRI

### ABSTRACT

**We report four cases of chronic obscure pain in the finger tips. High-resolution magnetic resonance imaging (HR-MRI) findings helped diagnose the existence of a mass at the subungual area and all patients were treated with excision and biopsy. The pathological diagnosis was glomus tumor. HR-MRI is useful in the diagnosis of patients with subungual glomus tumor.**

### INTRODUCTION

Glomus tumor is a tumor arising from a neuromyoarterial glomus, which is an arteriovenous anastomosis functioning without an intermediary capillary bed<sup>1,3</sup>. Normal glomus bodies are thought to aid in the regulation of skin circulation and to be highly concentrated in the finger tips, particularly beneath the nail. The most common site of glomus tumor is the fingers. However, it is difficult to diagnose because of obscure symptoms, such as chronic pain and hypersensitivity, and the small size of the lesion. We diagnosed patients, who had obscure chronic pain and hypersensitivity, with glomus tumor at the subungual area of the finger using high-resolution magnetic resonance imaging(HR-MRI) and treated the patients with surgical excision. The patients and/or their families were informed that data from the cases would be submitted for publication and gave their consent.

### CLINICAL CASE

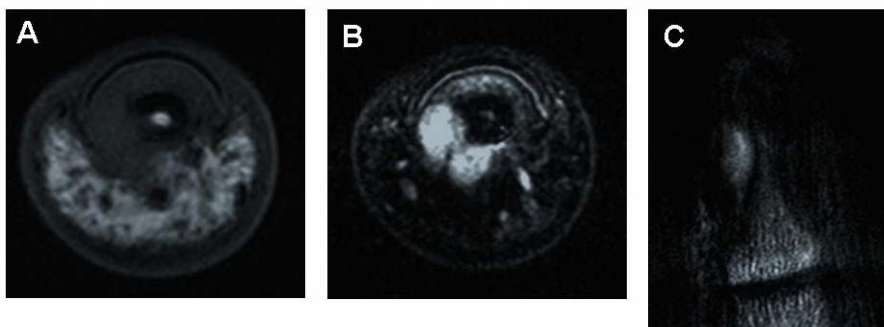
From January 2002 to August 2007, four patients were treated surgically and diagnosed with glomus tumor (Table). Two patients were male and two were female. The mean age of the patients was 29 (range from 25 to 31). The complaints of all patients were severe pain on touching or with exposure to coldness in the finger tip. Neither mass of the finger pulp nor deformities of the nail were observed. All patients were referred to us because clinical diagnosis was difficult and there were no abnormal findings on the radiographs. The patients were examined with HR-MRI upon initial consultation. The mean duration from the onset to clinical diagnosis was 4.5 years (range from 6 months to 10 years). All patients were treated with surgical excision through the lateral incision close to the margin of the nail accompanied with partial removal of the nail. Symptoms such as pain on touching or with exposure to coldness disappeared immediately after surgery. Recurrence of the symptoms was not observed at follow-ups of more than one year.

**Table** Summary of reported cases

case	age	sex	location	symptom	duration to diagnosis from onset	MRI finding	treatment	results
1	30	M	Right ring, subungual	pain on touching and with exposure to coldness	6 months	T1: isointense of the nail bed T2: hyperintense	excision	pain relieved
2	29	F	Right little, subungual	pain on touching and with exposure to coldness	2.5 years	T1: isointense of the nail bed T2: hyperintense	excision	pain relieved
3	25	F	Left middle, subungual	pain on touching	5 years	T1: isointense of the nail bed T2: hyperintense	excision	pain relieved
4	31	M	Left thumb, subungual	pain on touching	10 years	T1: isointense of the nail bed T2: hyperintense	excision	pain relieved

**Representative Case Report (case 2)**

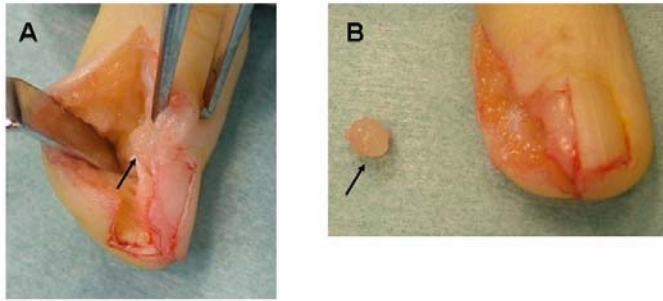
The patient was a 29 year-old-woman who was a postdoctoral student of psychology. Without previous cause, she felt pain and hypersensitivity on exposure to coldness on the right little finger. She consulted some doctors, however, no adequate diagnosis was made. She visited our institution two years and six months after onset. There was neither deformity of the nail nor limitation of the range of motion of the fingers. The radiographs of the right hand did not detect any abnormal findings. The patient was examined with HR-MRI. A small space occupying lesion was detected at the subungual area and adjacent to the distal phalangeal bone. The mass was isointense of the dermis of the nail bed on T1-weighted image and hyperintense on T2-weighted image (Figure 1). Surgical excision was performed through a lateral incision close to the margin of the nail accompanied with partial removal of the nail (Figure 2). Histological examination confirmed the diagnosis of benign glomus tumor composed of blood vessels surrounded by a proliferation of round cells in a fibrous stroma (Figure 3). The pain on exposure to coldness in the little finger disappeared after surgery and she was asymptomatic at postoperative two years.



**Figure 1** MRI findings of the distal phalanx in case 2.

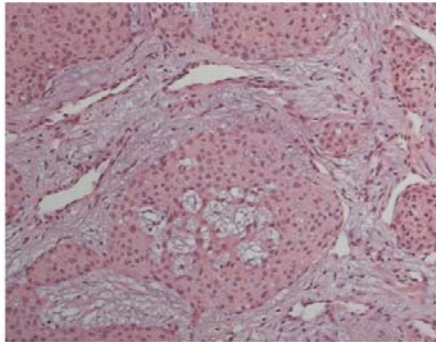
A mass is detected at the subungual area and adjacent to the distal phalangeal bone. The mass was isointense of the dermis of the nail bed on T1-weighted image (A) and hyperintense on T2-weighted image (B and C). Axial (A and B) and coronal view (C).

## SUBUNGUAL GLOMUS TUMOR



**Figure 2** Intraoperative findings in case 2.

The intra-operative picture demonstrates the tumor seated at the subungual area adjacent to the distal phalangeal bone (A). The tumor was excised en bloc (B). The arrows indicate the tumor.



**Figure 3** Histological section of the tumor in case 2.

The section stained with hematoxylin and eosin demonstrates blood vessels surrounded by a proliferation of round cells in a fibrous stroma, which is diagnosed as glomus tumor (original magnification x 20).

## DISCUSSION

We have presented four cases of patients, who had obscure chronic pain and hypersensitivity. The patients were diagnosed with glomus tumor in the finger tip using HR-MRI and were treated with surgical excision.

Glomus tumor is a tumor arising from a neuromyoarterial glomus and the most common site of glomus tumor is fingers<sup>1,3</sup>. Occasionally, in subungual glomus tumor, nail deformity and change of color beneath the nail on clinical findings and a scalloped defect of the distal phalanx on the radiograph are observed<sup>1,3,5,7</sup>. However, in our cases, these findings were not observed and thus it is difficult to diagnose the patient with glomus tumor from characteristic clinical findings and radiographs.

Recently, HR-MRI has been developed to diagnose small lesion and its usefulness has been reported in diagnosis of glomus tumor in the finger tips, which can be detected the mass as isointense of the dermis of the nail bed on T1-weighted image and hyperintense on T2-weighted image<sup>2,5-7</sup>. In all cases of the present study, the mass detected as isointense of the dermis of the nail bed on T1-weighted image was clearly identified in the subcutaneous fat, however, the margin of the mass unclear in the subungual zone. By contrast, the mass detected as homogeneous hyperintense on T2-weighted image was clearly identified in the

subcutaneous fat and in the subungual zone. Therefore, axial and coronal view of T2-weighted image gives the good information to make diagnosis.

All patients in the present study had a mass located in the finger tips and the mass was not diagnosed until HR-MRI examination was performed. They had a long history (mean, 4.5 years) suffering from onset to clinical diagnosis using HR-MRI, which detected the mass at the distal phalanx. Therefore, HR-MRI is considered to be a useful method to diagnose glomus tumor in fingers.

The patients were treated with surgical excision through a lateral incision close to the margin of the nail accompanied with partial removal of the nail. In all patients, symptoms such as pain on touching or with exposure to coldness disappeared after surgery and no recurrence was observed. Surgical excision and biopsy for glomus tumor is effective and necessary to confirm diagnosis and to relieve pain<sup>1,3,7,8</sup>. However, it is important that surgeons understand the accurate localization of the tumor and make meticulous surgical plan preoperatively in order to avoid recurrence and nail deformity<sup>8</sup>. HR-MRI is considered useful for planning surgical approach as well as for detecting the mass.

Therefore, HR-MRI is recommended in patients experiencing chronic pain and hypersensitivities in the finger. In addition, HR-MRI can offer excellent diagnostic information in detecting the occult lesion. If HR-MRI detects a mass of the fingers and glomus tumor is suspected, surgical excision, which gives pathological diagnosis and achieves pain relief, should be performed.

#### REFERENCES

1. **Carroll RE, Berman AT.** 1972. Glomus tumors of the hand. Review of the literature and report on twenty-eight cases, *J Bone Joint Surg* **54A**: 691-703.
2. **Drapé JL, Idy-Peretti I, Goettmann S, Guérin-Surville H, Bittoun J.** 1996. Standard and high resolution magnetic resonance imaging of glomus tumors of toes and fingertips. *J Am Acad Dermatol* **35**: 550-555.
3. **Enzinger FM, Weiss SW.** 1995. Perivascular tumors. In: *Soft tissue tumors*. 3<sup>rd</sup> ed. St. Louis: Mosby; p.701-733.
4. **Hou SM, Shih TTF, Lin MC.** 1993. Magnetic resonance imaging of an obscure glomus tumor in the finger tip. *J Hand Surg* **18B**: 482-483.
5. **Koç O, Kivrak AS, Paksoy Y.** 2007. Subungual glomus tumor: magnetic resonance imaging findings. *Australas Radiol* **51**: B107-109.
6. **Opdenakker G, Gelin G, Palmers Y.** 1999. MR imaging of a subungual glomus tumor. *Am J Roentgenol* **172**: 250-251.
7. **Takemura N, Fujii N, Tanaka T.** 2006. Subungual glomus tumor diagnosis based on imaging. *J Dermatol* **33**: 389-393.
8. **Takata H, Ikuta Y, Ishida O, Kimori K.** 2001. Treatment of subungual glomus tumour. *Hand Surg* **6**: 25-27.