

Nonsense Mutations of the *ZFHX1B* Gene in Two Japanese Girls with Mowat-Wilson Syndrome

TEGUH HARYO SASONGKO¹, AHMAD HAMIM SADEWA¹,
GUNADI¹, MYEONG JIN LEE¹, KEIKO KOTERAZAWA²,
and HISAHIDE NISHIO¹

*Department of Public Health, Kobe University Graduate School of Medicine¹;
Himeji City Center for the Handicapped²*

Received 25 October 2006 /Accepted 9 February 2007

Key words: Mowat-Wilson syndrome, *ZFHX1B*, SIP1, nonsense mutation

Mowat-Wilson syndrome (MWS) is a multiple congenital anomaly-mental retardation complex caused by mutations in the Zinc Finger Homeobox 1 B gene (*ZFHX1B*). MWS has been reported in association with Hirschsprung disease (HSCR). MWS is sometimes difficult to diagnose clinically, especially when HSCR is absent. Thus, it is necessary to detect gene abnormalities at the molecular level. Here we report two Japanese girls with MWS, who showed a distinct facial phenotype, severe intellectual disability and epileptic seizures. Major congenital anomalies of the patients were very different. Patient 1 suffered from severe congenital heart disease, but did not show apparent HSCR. Patient 2 suffered from typical HSCR and underwent surgical treatment, but did not have congenital heart disease. According to the gene analysis using white blood cells, they had nonsense mutations in *ZFHX1B*, R695X and Q433X, respectively. In conclusion, molecular genetic analysis of *ZFHX1B* is important for a definite diagnosis of MWS which has a wide phenotypic spectrum of congenital anomalies.

Mowat-Wilson syndrome (MWS; OMIM#235730) is a new clinical entity with a distinct facial phenotype, multiple congenital anomalies and mental retardation. In 1998, Mowat et al. described a new syndrome characterized by a distinct facial phenotype, Hirschsprung disease (HSCR), microcephaly and mental retardation, and identified a disease-locus at chromosome 2q21-q23 (4). In 2001, Wakamatsu et al. (9) reported mutations in the Zinc Finger Homeobox 1B (*ZFHX1B*) gene of patients with syndromic HSCR, and Cacheux et al. (2) reported mutations in *ZFHX1B* of the patients of Mowat et al (4). In 2002, Zweier et al. (12) concluded, based on their own patients, that MWS was a distinct and recognizable syndrome caused by mutations in *ZFHX1B*. Only heterozygous mutations of *ZFHX1B* have been found in MWS patients, suggesting an autosomal dominant inheritance trait.

ZFHX1B spans approximately 70 kb of DNA, and consists of 10 exons and 9 introns. It encodes the protein product Smad-interacting protein-1 (SIP1), consisting of 1214 amino acids. *ZFHX1B* mRNA is detected in nearly all human tissues including the fetus (2), and is likely to play a crucial role in embryonic development (8). Van de Putte et al. (8) showed that *Zfhx1b*-knockout mice do not develop postotic vagal neural crest cells, the precursors of the enteric nervous system which is affected in patients with HSCR. They also displayed a delamination arrest of cranial neural crest cells, which form the skeletomuscular elements of

the vertebrate head. This suggests that SIP1 is essential for the development of vagal neural crest precursors and the migratory behavior of cranial neural crest cells in the mouse.

Here, we report two Japanese girls with MWS who showed a typical facial phenotype, mental retardation and epileptic seizures. Molecular genetic analysis revealed that both were heterozygous for a nonsense mutation in *ZFX1B* exon 8 which led to a definite diagnosis of MWS.

PATIENTS AND METHODS

Patients

Patient 1 was a 5-year-old Japanese girl with mental retardation and epileptic seizures. She was born to unrelated healthy parents at 37 gestational weeks with a weight of 2,700 g, a length of 47.6 cm and a head circumference of 31.5 cm. She showed tachypnea just after birth and was diagnosed as having a congenital heart disease complex including patent ductus arteriosus (PDA), ventricular septal defect (VSD), aortic stenosis (AS) and pulmonary stenosis (PS). To ameliorate the heart failure, surgical closure of PDA was accomplished at day 11. In addition, a double renal pelvis was found in the right kidney. She was able to control her head at 5 months of age, sit without support at 15 months and walk alone at 5 years. She developed epilepsy at 4 years. At the present examination, her weight was 15.2 kg (-2.4SD), height 98.2 cm (-1.2SD) and her head circumference was 46 cm (-2.7SD). Her facial characteristics included frontal bossing, medially flaring thick eyebrows, hypertelorism, epicanthus, saddle nose, open mouth, triangular jaw with prominent chin and posterior low set ears with uplifted lobes (Fig.1). No cleft lip and palate were observed. Neurological examination disclosed that muscle tonus was slightly decreased and that deep tendon reflexes were slightly exaggerated. She sometimes demonstrated a happy and affectionate personality. However, since she had no speech, most communication of wants and ideas were nonverbal. Cranial MR imaging did not show any cerebral structural anomalies including callosal agenesis. Cytogenetic analysis with G-banding showed a normal karyotype.

Patient 2 was an 8-year-old Japanese girl with mental retardation and epileptic seizures. She was born to unrelated healthy parents at 38 gestational weeks with a weight of 3,205 g, a length of 46.0 cm and a head circumference of 31.0 cm. She showed no evacuation after birth and was diagnosed as having HSCR. Surgical treatment was performed which excised a large aganglionic segment of the colon and a part of the small intestine. Her physical development was delayed: she was able to walk alone at 7 years of age. She developed epilepsy at 7 months. On the examination at 8 years of age, her weight was 17.1 kg (-1.9SD), height 118.0 cm (-1.1SD) and she had a head circumference of 48.5 cm (-1.5SD). Her facial characteristics were similar to those of patient 1, including frontal bossing, medially flaring thick eyebrows, hypertelorism, epicanthus, saddle nose, open mouth, triangular jaw with a prominent chin and posterior low set ears with uplifted lobes (Fig.1). No cleft lip and palate were observed. Neurological examination disclosed that muscle tonus was slightly decreased and that deep tendon reflexes were slightly exaggerated. She sometimes demonstrated a happy and affectionate personality. However, most communication of wants and ideas were nonverbal, as for Patient 1, because she had no speech. Cranial MR imaging did not show any cerebral structural anomalies including callosal agenesis. Cytogenetic analysis with G-banding showed a normal karyotype.

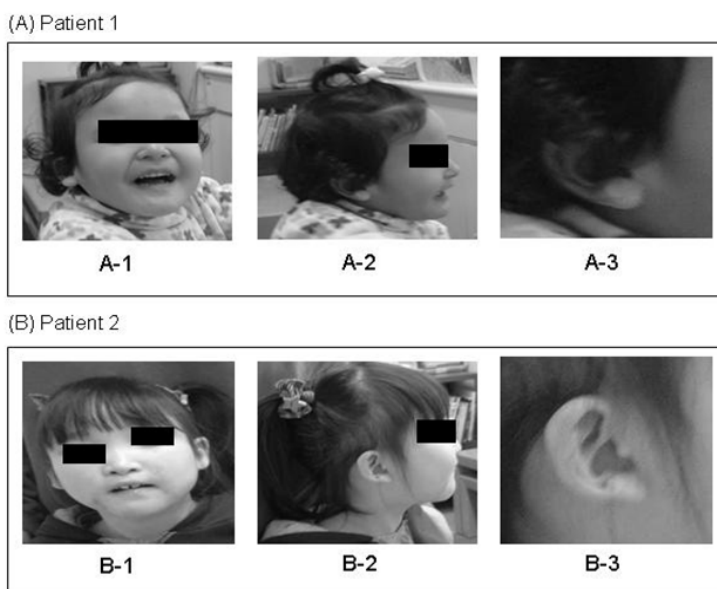


Figure 1. Facial features of Patients 1 and 2. (A) Full face, right profile and right ear appearances of Patient 1. (B) Full face, right profile and right ear appearances of Patient 2. Characteristic appearances of the posteriorly rotated ears with uplifted earlobes in MWS are observed.

PCR Amplification, DHPLC, and Direct Sequencing

Molecular genetic analysis was done after obtaining informed consent from their parents. Genomic DNA was extracted from whole blood using SepaGene Kit (Sanyo Junyaku Co., Ltd., Tokyo, Japan). PCR-amplification of all exons in *ZFHX1B* was carried out using the primer pairs described previously by Amiel et al. (1) and our new primer pairs. Ours were Z8B-1221F (5'- ACG GGT TTA GTG GCA CTA GT -3') and Z8B-1494R (5'- GGT TGA GAG CAT GGA TCC TT -3') for the exon 8B fragment, and Z8D-1953F (5'- CAT ACA AGG ACC ACA TGT CT -3') and Z8D-2195R (5'- GAG ACC TGG GTA ATA AAG AG -3') for the exon 8D fragment. To screen for mutations in *ZFHX1B* with denaturing high performance liquid chromatography (DHPLC), we applied the PCR-products into a PCR WAVE® DNA Fragment Analysis System (Transgenomic, Omaha, NE). The PCR products were sequenced by an ABI Prism® 310 Genetic Analyzer (Applied Biosystems, Foster City, CA, USA).

RESULTS

In both patients, an abnormal heteroduplex peak was observed in the chromatogram of exon 8 in each patient (Fig.2). These findings suggested that a mutation was present in *ZFHX1B* exon 8 of each patient. For the identification of an intragenic mutation in each patient, direct sequencing analysis of the PCR-products of *ZFHX1B* exon 8 from each patient was performed. Patient 1 showed a heterozygous transition mutation, 2083C>T, resulting in an arginine codon to a stop codon at amino acid 695 (R695X). Patient 2 showed a heterozygous transition mutation, 1298C>T, resulting in a glutamine codon to a stop codon at amino acid 433 (Q433X) (Fig.2).

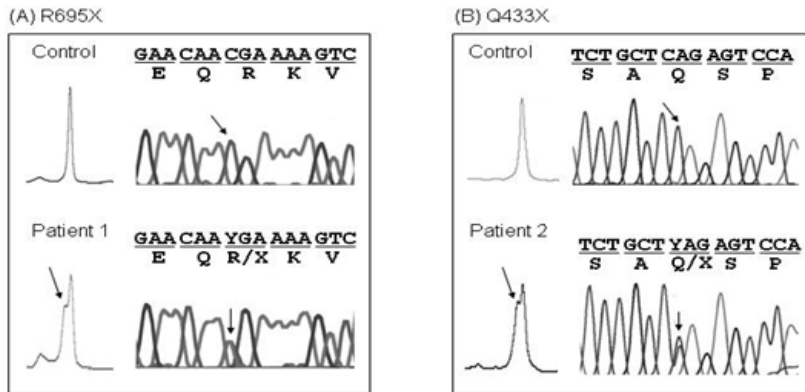


Figure 2. DHPLC and sequencing data of Patients 1 and 2. Patient 1 showed a heterozygous transition mutation, 2083C>T, resulting in an arginine (CGA) codon to a stop (TGA) codon (R695X), while patient 2 showed a heterozygous transition mutation, 1298C>T, resulting in a glutamine (CAG) codon to a stop (TAG) codon (Q433X).

DISCUSSION

1. Diagnosis of MWS

Although our patients showed the distinct facial phenotype, molecular genetic analysis of *ZFX1B* was needed for the definite diagnosis of MWS, because not all MWS-related symptoms were present in both patients. Besides, we were afraid of arbitrary assessment of dysmorphic findings, especially in the facial phenotype. Molecular genetic analysis identified two nonsense mutations, R695X and Q433X, in *ZFX1B* of these girls. The former was one of the recurrent mutations (11,12), and the latter was a novel one that has not been reported so far. The presence of a mutation in *ZFX1B* gave us a definite diagnosis of MWS.

In spite of the presence of a distinct facial phenotype, severe mental retardation (often present in HSCR), epilepsy and major and minor malformations, it may sometimes be difficult to reach a correct diagnosis of MWS. If the MWS patient with HSCR shows cleft palate or lip cleft as previously reported (10), and if molecular genetic analysis of *ZFX1B* is not performed, the patient may be diagnosed as having Goldberg-Shprintzen syndrome. Goldberg-Shprintzen syndrome is a phenotypically similar genetic disorder which is also characterized by HSCR and mental retardation, but with a different mode of inheritance, namely autosomal recessive (1).

There are some examples of misdiagnosis previously reported: a patient with MWS had been thought to have Angelman syndrome, based on the presence of severe MR, seizures, ataxia, microcephaly, prominent jaw and a happy behavioral phenotype (10). One patient with unilateral duplication of the hallux and agenesis of the corpus callosum was previously diagnosed as having the acrocallosal syndrome (5). Therefore, we conclude that molecular genetic analysis is essential for attributing a definite diagnosis of MWS.

2. Recurrent mutations in *ZFX1B*

The R695X mutation was detected in Patient 1 of this study. A total of 117 patients with mutated/deleted *ZFX1B* have been registered in the data bank of the Institute of Human Genetics of the University of Friedrich-Alexander in Erlangen-Nuremberg (<http://www.hum>

NONSENSE MUTATIONS OF ZFHX1B GENE IN MOWAT-WILSON SYNDROME

genet.uni-erlangen.de/2k/AGRauch_ZFHX1B.html). According to this data bank, 11 patients harbored R695X.

Yamada et al. (11) suspected that the C-to-T transition in R695X mutation which was derived from CpG doublet is likely to be favored by *ZFHX1B* mutations. Zweier et al. (12) also reported that three other recurrent mutations of C-to-T transitions, 904C>T (R302X), 1027C>T (R343X) and 2761C>T (R921X) were derived from CpG doublet. Sved and Bird (6) showed that 20 out of 38 (53%) point mutations giving rise to diseases are at CpG doublet. Thus, a C-to-T transition at CpG doublets may be the most favored target for *ZFHX1B* mutations.

3. Genotype-phenotype correlation in MWS

Our patient with R695X (Patient 1) showed a distinct facial phenotype, mental retardation, epilepsy, constipation and congenital heart disease, but no apparent HSCR. According to the clinical data of 7 patients with R695X reported by Ishihara et al. (3), 4 out of 7 patients (57%) had HSCR and 3 patients (43%) had only constipation. These findings showed that a single mutation in *ZFHX1B* did not always cause apparent HSCR, suggesting that the HSCR phenotype in MWS are determined not only by *ZFHX1B* mutations but also by epigenetic factors or modifying genes.

Although Patient 2 harbored a novel nonsense mutation, Q433X, the clinical phenotype was similar with other patients harboring different mutations. The patient showed a distinct facial phenotype, mental retardation, epileptic seizures and HSCR. Mowat et al. (5) suggested that there is no clear genotype-phenotype correlation in respect to location of the mutation and penetrance of the HSCR phenotype.

4. Genetic heterogeneity in MWS

Several studies have reported typical MWS cases without demonstrable mutations in *ZFHX1B* gene (1,5,11). Yamada et al. (11) reported one out of eleven patients without mutation in *ZFHX1B*. The patient demonstrated severe mental retardation and delayed motor development, without epileptic seizures. Amiel et al. (1) described eleven out of nineteen patients without mutation in *ZFHX1B*.

Several explanations may be available for the absence of mutations in *ZFHX1B*. Genetic heterogeneity for MWS cannot be completely excluded. Mowat et al. (5) speculated that mutations in the other genes acting on the same pathways related to neuronal development and/or organogenesis may play crucial role in the pathogenesis of MWS.

5. Conclusion

In conclusion, we identified two nonsense mutations, R695X and Q433X, in *ZFHX1B* of two Japanese girls with MWS. The importance of molecular genetic analysis of *ZFHX1B* is illustrated here for a definite diagnosis of MWS which has a wide phenotypic spectrum of congenital anomalies.

REFERENCES

1. Amiel, J., Espinosa-Parrilla, Y., Steffann, J., Gosset, P., Pelet, A., Prieur, M., et al. 2001. Large-scale deletions and SMADIP1 truncating mutations in syndromic Hirschsprung disease with involvement of midline structures. *Am J Hum Genet* **69**:1370-7.
2. Cacheux, V., Dastot-Le Moal, F., Kaariainen, H., Bondurand, N., Rintala, R., Boissier, B., et al. 2001. Loss-of-function mutations in SIP1 Smad interacting protein 1 result in a syndromic Hirschsprung disease. *Hum Mol Genet* **10**:1503-10.

3. **Ishihara, N., Yamada, K., Yamada, Y., Miura, K., Kato, J., Kuwabara, N., et al.** 2004. Clinical and molecular analysis of Mowat-Wilson syndrome associated with ZFHX1B mutations and deletions at 2q22-q24.1. *J Med Genet* **41**:387-93.
4. **Mowat, D.R., Croaker, G.D., Cass, D.T., Kerr, B.A., Chaitow, J., Ades, L.C., et al.** 1998. Hirschsprung disease, microcephaly, mental retardation, and characteristic facial features: delineation of a new syndrome and identification of a locus at chromosome 2q22-q23. *J Med Genet* **35**:617-23.
5. **Mowat D.R., Wilson M.J., Goossens M.** 2003. Mowat-Wilson syndrome. *J Med Genet* **40**:305-10.
6. **Sved, J., and Bird, A.** 1990. The expected equilibrium of the CpG dinucleotide in vertebrate genomes under a mutation model. *Proc. Natl. Acad. Sci. USA* **87**:4692-6.
7. **Ten Dijke, P., Miyazono, K., Heldin, C.** 2000. Signaling inputs converge on nuclear effectors in TGF-beta signaling. *Trends Biochem Sci* **25**:64-70.
8. **Van de Putte, T., Maruhashi, M., Francis, A., Nelles, L., Kondoh, H., Huylebroeck, D., et al.** 2003. Mice Lacking *Zfhx1b*, the Gene That Codes for Smad-Interacting Protein-1, Reveal a Role for Multiple Neural Crest Cell Defects in the Etiology of Hirschsprung Disease-Mental Retardation Syndrome. *Am J Hum Genet* **72**:465-470.
9. **Wakamatsu, N., Yamada, Y., Yamada, K., Ono, T., Nomura, N., Taniguchi, H., et al.** 2001. Mutations in *SIP1*, encoding Smad interacting protein-1, cause a form of Hirschsprung disease. *Nat Genet* **27**:369-70.
10. **Wilson, M., Mowat, D., Dastot-Le Moal, F., Cacheux, V., Kaariainen, H., Cass, D., et al.** 2003. Further delineation of the phenotype associated with heterozygous mutations in *ZFHX1B*. *Am J Med Genet* **119**:257-65.
11. **Yamada, K., Yamada, Y., Nomura, N., Miura, K., Wakako, R., Hayakawa, C., et al.** 2001. Nonsense and frameshift mutations in *ZFHX1B*, encoding Smad-Interacting Protein 1, cause a complex developmental disorder with a great variety of clinical features. *Am J Hum Genet* **69**:1178-85.
12. **Zweier, C., Albrecht, B., Mitulla, B., Behrens, R., Beese, M., Gillissen-Kaesbach, G., et al.** 2002. "Mowat-Wilson" syndrome with and without Hirschsprung disease is a distinct, recognizable multiple congenital anomalies-mental retardation syndrome caused by mutations in the zinc finger homeo box 1B gene. *Am J Med Genet* **108**:177-81.